A 16-year-old boy comes to the office due to a 3-day history of burning with urination and yellow penile discharge. He is monogamous with one female sexual partner who is on oral contraceptives. He engages in vaginal intercourse and does not use condoms. The patient has no other medical problems, takes no medications, and has no allergies. Urine nucleic acid amplification test results are pending, and urethral Gram stain is shown in the exhibit. Treatment of this patient's condition should be selected from which of the following drug classes?

A. Fluoroquinolone and macrolide

B. Fluoroquinolone and third-generation cephalosporin

C. Macrolide and third-generation cephalosporin

D. Macrolide only

E. Penicillin only

F. Third-generation cephalosporin only

Submit

A 16-year-old boy comes to the office due to a 3-day history of burning with urination and yellow penile discharge. He is monogamous with one female sexual partner who is on oral contraceptives. He engages in vaginal intercourse and does not use condoms. The patient has no other medical problems, takes no medications, and has no allergies. Urine nucleic acid amplification test results are pending, and urethral Gram stain is shown in the exhibit. Treatment of this patient's condition should be selected from which of the following drug classes?

- A. Fluoroquinolone and macrolide (4%)
- B. Fluoroquinolone and third-generation cephalosporin (8%)
- ✓ C. Macrolide and third-generation cephalosporin (76%)
- D. Macrolide only (2%)
- E. Penicillin only (2%)
- F. Third-generation cephalosporin only (5%)

Omitted
Correct answer
C

76%
Answered correctly

09 secs
Time Spent

06/27/2020
Last Updated

Explanation

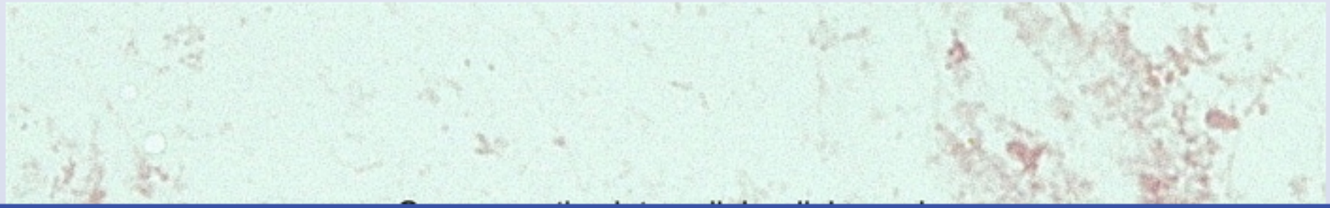

1 2 3 4 5 6 7 8 9 10 11 12 13 14 15 16 17 18 19 20 21 22 23 24 25 26 27 28 29 30 31

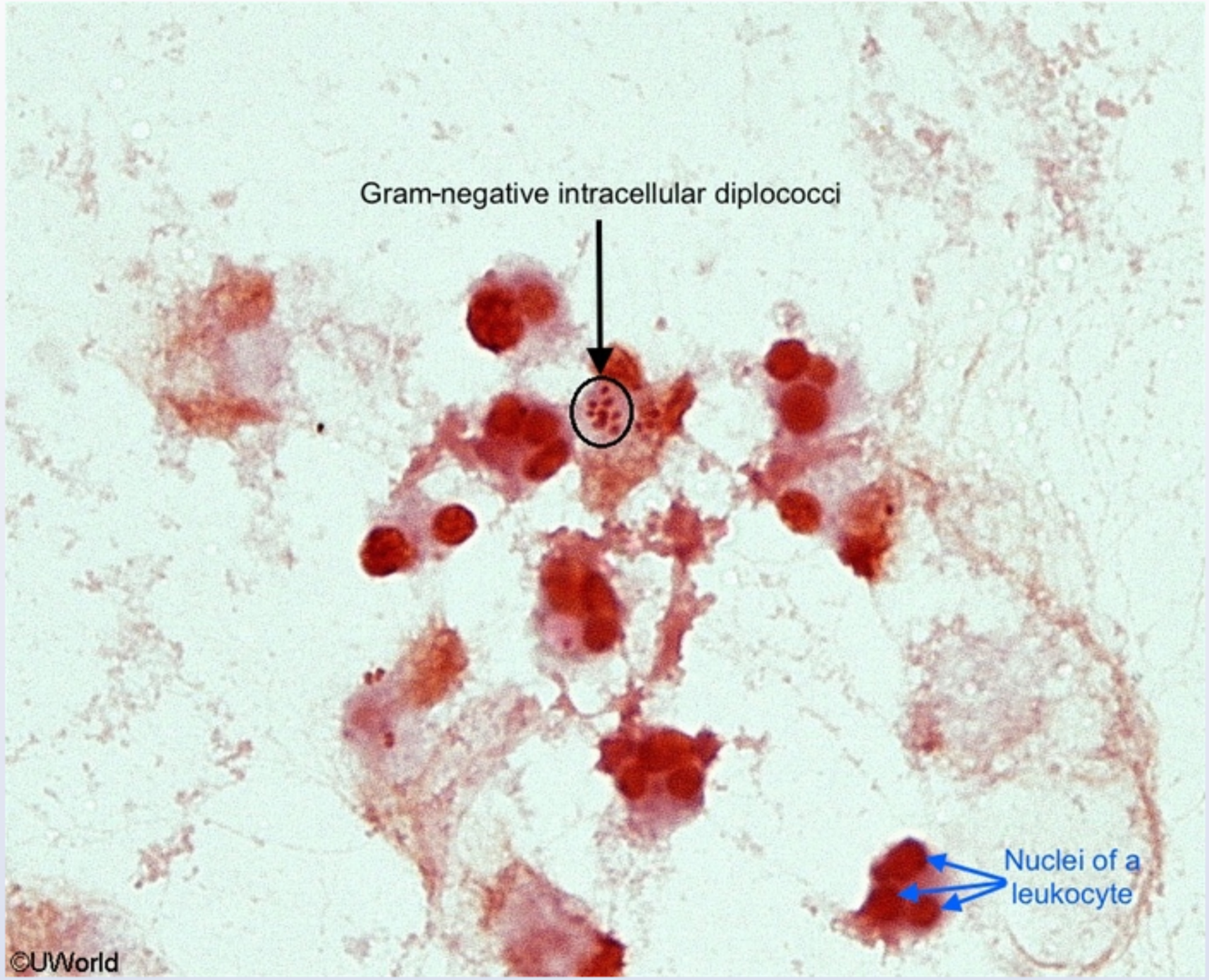

This patient with **dysuria** and penile **discharge** has urethritis caused by *Neisseria gonorrhoeae*, a **gram-negative intracellular diplococcus** (black arrow) shown in the image above with polymorphonuclear leukocytes (blue arrows). Gonorrhea is the second most common sexually

This patient with **dysuria** and penile **discharge** has urethritis caused by *Neisseria gonorrhoeae*, a **gram-negative intracellular diplococcus** (black arrow) shown in the image above with polymorphonuclear leukocytes (blue arrows). Gonorrhea is the second most common sexually transmitted disease in the United States following chlamydia. *N gonorrhoeae* are non-motile organisms that use pili to adhere to and penetrate mucosal epithelial cells. **Nucleic acid amplification testing (NAAT)** is the diagnostic test of choice for gonorrhea. NAAT uses male urine or urethral specimens or female urine, vaginal, or endocervical specimens to detect a virus or bacterium. Urethral **Gram stain** and culture can also be obtained for diagnosis and determination of antibiotic sensitivities, respectively.

The treatment of choice for gonorrhea is dual therapy with **ceftriaxone**, a third-generation cephalosporin, **and azithromycin**, a macrolide. Although ceftriaxone cures nearly all cases of isolated gonorrhea, the addition of azithromycin is recommended due to potential resistance against cephalosporins and protection against chlamydia co-infection. Therefore, ceftriaxone alone **(Choice F)** is no longer recommended for treatment of gonorrhea.

Untreated gonococcal (and chlamydial) infections can lead to **prostatitis** or **epididymitis** in males and pelvic inflammatory disease in females. Other potential sites of gonococcal infection include the anus in men who have sex with men, the pharynx through oral sex, and the conjunctivae of neonates from untreated infected mothers.

(Choices A and B) Fluoroquinolones (eg, ciprofloxacin, levofloxacin) are not recommended for gonorrhea treatment due to high rates of resistance.

(Choice D) Azithromycin, a macrolide, is the recommended treatment for *Chlamydia trachomatis* infection (eg, urethritis, cervicitis). NAAT is also the diagnostic test of choice for chlamydia.

(Choice E) Penicillin is the treatment of choice for all stages of syphilis. Primary syphilis (eg, painless chancre) is best diagnosed by direct visualization of bacteria on darkfield microscopy. Secondary syphilis (eg, maculopapular rash) and tertiary syphilis (eg, central nervous system and cardiovascular involvement, gumma development) are generally diagnosed through serology (eg, RPR, VDRL).

Educational objective:
Gonorrhea can cause urethritis (dysuria and purulent urethral discharge). The nucleic acid amplification test is the diagnostic tool of choice. Gram stain showing gram-negative, intracellular diplococci is also diagnostic. Dual therapy with ceftriaxone and azithromycin is the first-line treatment due to concerns about resistance and chlamydia co-infection.

References

cephalosporins and protection against chlamydia co-infection. Therefore, ceftriaxone alone **(Choice F)** is no longer recommended for treatment of gonorrhea.

Untreated gonococcal (and chlamydial) infections can lead to **prostatitis** or **epididymitis** in males and pelvic inflammatory disease in females. Other potential sites of gonococcal infection include the anus in men who have sex with men, the pharynx through oral sex, and the conjunctivae of neonates from untreated infected mothers.

(Choices A and B) Fluoroquinolones (eg, ciprofloxacin, levofloxacin) are not recommended for gonorrhea treatment due to high rates of resistance.

(Choice D) Azithromycin, a macrolide, is the recommended treatment for *Chlamydia trachomatis* infection (eg, urethritis, cervicitis). NAAT is also the diagnostic test of choice for chlamydia.

(Choice E) Penicillin is the treatment of choice for all stages of syphilis. Primary syphilis (eg, painless chancre) is best diagnosed by direct visualization of bacteria on darkfield microscopy. Secondary syphilis (eg, maculopapular rash) and tertiary syphilis (eg, central nervous system and cardiovascular involvement, gumma development) are generally diagnosed through serology (eg, RPR, VDRL).

Educational objective:
Gonorrhea can cause urethritis (dysuria and purulent urethral discharge). The nucleic acid amplification test is the diagnostic tool of choice. Gram stain showing gram-negative, intracellular diplococci is also diagnostic. Dual therapy with ceftriaxone and azithromycin is the first-line treatment due to concerns about resistance and chlamydia co-infection.

References

- Update on Treatment Options for Gonococcal Infections.
- Management of Gonorrhea in Adolescents and Adults in the United States.

Microbiology	Infectious Diseases	Urethritis
Subject	System	Topic

Copyright © UWorld. All rights reserved.

be obtained for diagnosis and determination of antibiotic sensitivities, respectively.

Exhibit Display

Zoom In | Zoom Out | Reset | Add To New Card | Existing Card

Microbiology | Infectious Diseases | Urethritis

be obtained for diagnosis and determination of antibiotic sensitivities, respectively.

Exhibit Display

Zoom In | Zoom Out | Reset | Add To New Card | Existing Card

Microbiology | Infectious Diseases | Urethritis

Three cases of severe pharyngitis were reported in a community of immigrants. The patients had thick pharyngeal exudates, neck swelling, and difficulty swallowing. One of them died from severe heart failure. The toxin responsible has a mechanism of action most similar to another toxin produced by which of the following bacteria?

A. *Pseudomonas aeruginosa*

B. *Staphylococcus aureus*

C. *Clostridium difficile*

D. *Clostridium botulinum*

E. *Bordetella pertussis*

F. *Vibrio cholerae*

Submit

Three cases of severe pharyngitis were reported in a community of immigrants. The patients had thick pharyngeal exudates, neck swelling, and difficulty swallowing. One of them died from severe heart failure. The toxin responsible has a mechanism of action most similar to another toxin produced by which of the following bacteria?

- ✓ A. *Pseudomonas aeruginosa* (57%)
- B. *Staphylococcus aureus* (9%)
- C. *Clostridium difficile* (7%)
- D. *Clostridium botulinum* (3%)
- E. *Bordetella pertussis* (16%)
- F. *Vibrio cholerae* (4%)

Omitted
Correct answer
A

57%
Answered correctly

02 secs
Time Spent

07/04/2020
Last Updated

Explanation

Severe pharyngitis with exudates and cervical lymphadenopathy in a group of people with unknown vaccination status should raise suspicion for respiratory diphtheria infection. Diphtheria toxin can cause severe myocarditis and heart failure, which occurred in one of the patients in the vignette. Diphtheria toxin acts in a similar manner to exotoxin A, which is produced by *Pseudomonas aeruginosa*.

P aeruginosa produces several extracellular products, including exotoxin A, collagenase, elastase, fibrinolysin, phospholipase C, and DNAse. These substances assist in its invasion and dissemination in human tissues. Although they are structurally different, both diphtheria toxin and exotoxin A ribosylate and inactivate elongation factor 2 (EF-2), halting human cell protein synthesis and causing cell death. Exotoxin A is a major

Severe pharyngitis with exudates and cervical lymphadenopathy in a group of people with unknown vaccination status should raise suspicion for respiratory diphtheria infection. Diphtheria toxin can cause severe myocarditis and heart failure, which occurred in one of the patients in the vignette. Diphtheria toxin acts in a similar manner to exotoxin A, which is produced by *Pseudomonas aeruginosa*.

P aeruginosa produces several extracellular products, including exotoxin A, collagenase, elastase, fibrinolysin, phospholipase C, and DNAse. These substances assist in its invasion and dissemination in human tissues. Although they are structurally different, both diphtheria toxin and exotoxin A ribosylate and inactivate elongation factor-2 (EF-2), halting human cell protein synthesis and causing cell death. Exotoxin A is a major virulence factor and is responsible for the high mortality associated with *P aeruginosa* septicemia.

Mechanism of action of bacterial toxins

Choice	Organism	Toxin	Microbiology
	C. diphtheriae	Diphtheria toxin	Inactivates EF-2 via ribosylation, thus inhibiting host cell protein synthesis
A	*P. aeruginosa*	Exotoxin A	Inactivates EF-2 via ribosylation, thus inhibiting host cell protein synthesis
B	*S. aureus*	Enterotoxin	Superantigen that acts locally in the GI tract causing vomiting
		TSS toxin	Superantigen that stimulates T-cells leading to widespread cytokine release and shock
			Induces actin depolymerization leading to

Mechanism of action of bacterial toxins

Choice	Organism	Toxin	Microbiology
	C. diphtheriae	Diphtheria toxin	Inactivates EF-2 via ribosylation, thus inhibiting host cell protein synthesis
A	*P. aeruginosa*	Exotoxin A	Inactivates EF-2 via ribosylation, thus inhibiting host cell protein synthesis
B	*S. aureus*	Enterotoxin	Superantigen that acts locally in the GI tract causing vomiting
		TSS toxin	Superantigen that stimulates T-cells leading to widespread cytokine release and shock
C	*C. difficile*	Cytotoxin B	Induces actin depolymerization leading to mucosal cell death, necrosis of colonic mucosal surfaces, & pseudomembrane formation
D	*C. botulinum*	Botulinum toxin	Blocks the presynaptic release of acetycholine at the neuromuscular junction resulting in flaccid paralysis
			Disinhibits adenylate cyclase via G_i ADP

C	*C. difficile*	Cytotoxin B	Induces actin depolymerization leading to mucosal cell death, necrosis of colonic mucosal surfaces, & pseudomembrane formation
D	*C. botulinum*	Botulinum toxin	Blocks the presynaptic release of acetycholine at the neuromuscular junction resulting in flaccid paralysis
E	*B. pertussis*	Pertussis toxin	Disinhibits adenylate cyclase via G_i ADP ribosylation, increasing cAMP production in the host cell; causes increased histamine sensitivity & phagocyte dysfunction
F	*V. cholerae*	Cholera toxin	Activates adenylate cyclase via G_s ADP ribosylation, increasing cAMP production in the host cell; causes secretory diarrhea, dehydration, & electrolyte imbalances

©UWorld

Educational objective:
Diphtheria toxin and pseudomonal exotoxin A act by ribosylating and inactivating elongation factor-2, inhibiting host cell protein synthesis and causing cell death.

Microbiology	Infectious Diseases	Diphtheria
Subject	System	Topic

Copyright © UWorld. All rights reserved.

A 29-year-old woman comes to the hospital due to fever and skin rash. She returned from a trip to Brazil 10 days ago. Her symptoms started 5 days ago with a headache, retro-orbital pain, high-grade fever, and joint and muscle pains. She has also had an episode of epistaxis. Today, she noticed a skin rash all over her body. Examination shows a diffuse maculopapular rash and scattered petechiae. Laboratory study results show thrombocytopenia. Her boyfriend traveled to Brazil with her and is asymptomatic. Transmission of the pathogen causing this patient's current symptoms occurs in a manner that is most similar to which of the following diseases?

A. Chikungunya fever
B. Lymphogranuloma venereum
C. Meningococcal meningitis
D. Pulmonary tuberculosis
E. Rocky Mountain spotted fever
F. Typhoid fever

Submit

A 29-year-old woman comes to the hospital due to fever and skin rash. She returned from a trip to Brazil 10 days ago. Her symptoms started 5 days ago with a headache, retro-orbital pain, high-grade fever, and joint and muscle pains. She has also had an episode of epistaxis. Today, she noticed a skin rash all over her body. Examination shows a diffuse maculopapular rash and scattered petechiae. Laboratory study results show thrombocytopenia. Her boyfriend traveled to Brazil with her and is asymptomatic. Transmission of the pathogen causing this patient's current symptoms occurs in a manner that is most similar to which of the following diseases?

- ✓ A. Chikungunya fever (69%)
- B. Lymphogranuloma venereum (1%)
- C. Meningococcal meningitis (4%)
- D. Pulmonary tuberculosis (1%)
- E. Rocky Mountain spotted fever (17%)
- F. Typhoid fever (5%)

Omitted
Correct answer
A

69%
Answered correctly

02 secs
Time Spent

04/13/2020
Last Updated

Explanation

Transmission of common infections	
Mechanism of	

Transmission of common infections

Mechanism of transmission	Examples
Direct contact	• Infectious mononucleosis • Lymphogranuloma venereum • RSV, rhinovirus, Norwalk virus
Droplet (>5 µm) (eg, coughing, sneezing)	• Influenza • Meningococcus • Adenovirus, pertussis
Airborne (<5 µm) (eg, aerosols, ventilation system)	• TB • Measles, chickenpox, smallpox
Vectorborne	• Mosquitoes (malaria, dengue fever, chikungunya) • Ticks (Lyme disease, RMSF)

RMSF = Rocky Mountain spotted fever; **RSV** = respiratory syncytial virus; **TB** = tuberculosis.

©UWorld

This patient's presentation after recent travel to Brazil is consistent with **dengue fever (DF)**. DF is due to a virus transmitted by the *Aedes aegypti* **mosquito**. It is prevalent in tropical and subtropical regions (South and Southeast Asia, Pacific Islands, Caribbean, Americas). DF presents as an acute febrile illness with headache, **retro-orbital pain**, and joint and muscle pain. Other findings can include **hemorrhage** (eg, petechiae, purpura, epistaxis, melena), thrombocytopenia, leukopenia, and hemoconcentration.

©UWorld

This patient's presentation after recent travel to Brazil is consistent with **dengue fever (DF)**. DF is due to a virus transmitted by the *Aedes aegypti* **mosquito**. It is prevalent in tropical and subtropical regions (South and Southeast Asia, Pacific Islands, Caribbean, Americas). DF presents as an acute febrile illness with headache, **retro-orbital pain**, and joint and muscle pain. Other findings can include **hemorrhage** (eg, petechiae, purpura, epistaxis, melena), thrombocytopenia, leukopenia, and hemoconcentration.

The *Aedes* mosquito also transmits the virus causing **chikungunya**, a febrile illness with flulike symptoms, prominent polyarthralgia/arthritis (hands, wrists, ankles), and diffuse macular rash. As a result, many areas have had **simultaneous outbreaks** of both dengue and chikungunya. Preventive measures against both infections include protective barriers (eg, bed nets, window screens) and insect spraying.

(Choice B) Lymphogranuloma venereum can be caused by direct sexual contact with an infected individual.

(Choice C) Meningococcal meningitis is acquired by droplet contact. In a health care setting, measures to prevent transmission include wearing a face mask within 3 feet of the patient (who is typically placed in a private room).

(Choice D) Pulmonary tuberculosis is usually spread through airborne contact. Patients are placed in a negative-pressure isolation room, and specific respirator masks are worn by all contacts and visitors.

(Choice E) Rocky Mountain spotted fever is due to *Rickettsia rickettsii*, which is transmitted by ticks rather than mosquitoes.

(Choice F) Typhoid fever is caused by *Salmonella* and is usually acquired from contaminated food or water, typically in areas with poor sanitation.

Educational objective:
The *Aedes aegypti* mosquitoes can transmit the viruses that cause dengue fever and chikungunya. Classic dengue fever presents as an acute febrile illness with headache, retro-orbital pain, and joint and muscle pain. Chikungunya is a febrile illness with flulike symptoms, prominent polyarthralgias, and diffuse macular rash.

References

- Recent introduction and rapid dissemination of Chikungunya virus and Dengue virus serotype 2 associated with human and mosquito coinfections in Gabon, central Africa.

Microbiology Infectious Diseases Dengue fever

A 65-year-old woman with ovarian cancer undergoing chemotherapy is hospitalized due to fever, headache, ataxia, and progressive confusion. Two days later, a 26-year-old pregnant woman is admitted to the same hospital with fever, nausea, vomiting, diarrhea, and muscle aches and spontaneously delivers a preterm infant who has generalized skin rash. Laboratory evaluation reveals that these patients' conditions were caused by the same microbial organism. The state health department is notified. Reports of similar illnesses are noted in neighboring cities. A subsequent investigation reveals that 8 people were affected, all of whom consumed food products from a single processing facility. Which of the following organisms is most likely responsible for this outbreak?

- A. *Aspergillus fumigatus*
- B. Cytomegalovirus
- C. *Escherichia coli* O157:H7
- D. Herpes simplex virus
- E. *Listeria monocytogenes*
- F. *Neisseria meningitidis*
- G. *Streptococcus pneumoniae*
- H. *Toxoplasma gondii*

Submit

A 65-year-old woman with ovarian cancer undergoing chemotherapy is hospitalized due to fever, headache, ataxia, and progressive confusion. Two days later, a 26-year-old pregnant woman is admitted to the same hospital with fever, nausea, vomiting, diarrhea, and muscle aches and spontaneously delivers a preterm infant who has generalized skin rash. Laboratory evaluation reveals that these patients' conditions were caused by the same microbial organism. The state health department is notified. Reports of similar illnesses are noted in neighboring cities. A subsequent investigation reveals that 8 people were affected, all of whom consumed food products from a single processing facility. Which of the following organisms is most likely responsible for this outbreak?

- A. *Aspergillus fumigatus* (0%)
- B. Cytomegalovirus (5%)
- C. *Escherichia coli* O157:H7 (8%)
- D. Herpes simplex virus (1%)
- ✓ E. *Listeria monocytogenes* (72%)
- F. *Neisseria meningitidis* (0%)
- G. *Streptococcus pneumoniae* (0%)
- H. *Toxoplasma gondii* (11%)

Omitted
Correct answer
E

72%
Answered correctly

02 secs
Time Spent

03/12/2020
Last Updated

Explanation

Listeria monocytogenes is a facultative intracellular gram-positive bacillus that can multiply at **refrigerated temperatures** in both anaerobic and microaerophilic conditions. It is an important cause of foodborne illness; outbreaks are frequently associated with consumption of **contaminated food products** (eg, processed meats, soft cheeses, raw fruits & vegetables).

Healthy patients who ingest high inoculums of *Listeria* are at risk for febrile gastroenteritis. Invasive infections such as sepsis and **meningoencephalitis** are primarily seen in patients with **impaired cell-mediated immunity** (eg, AIDS, malignancy, extremes of age, pregnancy). Pregnant women are at greatest risk in the third trimester and often present with flu-like symptoms and intrauterine infection leading to **preterm labor** and neonatal sepsis.

(Choice A) Epidemic fungal meningitis due to *Aspergillus fumigatus* has been associated with contaminated glucocorticoid injections. *Aspergillus* is not typically associated with foodborne illness.

(Choices B and D) Cytomegalovirus and herpes simplex virus can cause a variety of clinical syndromes in immunocompromised patients, including encephalitis, esophagitis, pneumonitis, and colitis. These viruses are ubiquitous and not associated with foodborne outbreaks.

(Choice C) Foodborne outbreaks of *Escherichia coli* O157:H7 have been linked to the ingestion of contaminated beef (primarily) and are usually associated with hemorrhagic colitis. Patients may also develop hemolytic uremic syndrome. Meningitis and neonatal infection would be atypical.

(Choice F) *Neisseria meningitidis* causes sepsis and acute meningitis. It is transmitted primarily by respiratory droplets; most cases occur in those who live in congregate settings (eg, dormitories, military barracks).

(Choice G) *Streptococcus pneumoniae* is a common cause of bacterial meningitis in elderly and immunocompromised individuals but is not associated with foodborne outbreaks.

(Choice H) *Toxoplasma* is associated with meningoencephalitis in immunocompromised patients (eg, advanced AIDS). It is usually acquired by contact with cat feces, although transmission via undercooked lamb and pork has also been reported.

Educational objective:
Listeria is a relatively common foodborne illness associated with outbreaks after the consumption of contaminated food, particularly processed meats and dairy products. Healthy patients may develop gastroenteritis; patients with impaired cell-mediated immunity are at risk for invasive infection (eg, sepsis, meningoencephalitis) and listeriosis in pregnancy is associated with adverse fetal outcomes (eg, fetal death, premature birth).

1
2
3
4
5
6
7
8
9
10
11
12
13
14
15
16
17
18
19
20
21
22
23
24
25
26
27
28
29
30
31

Exhibit Display

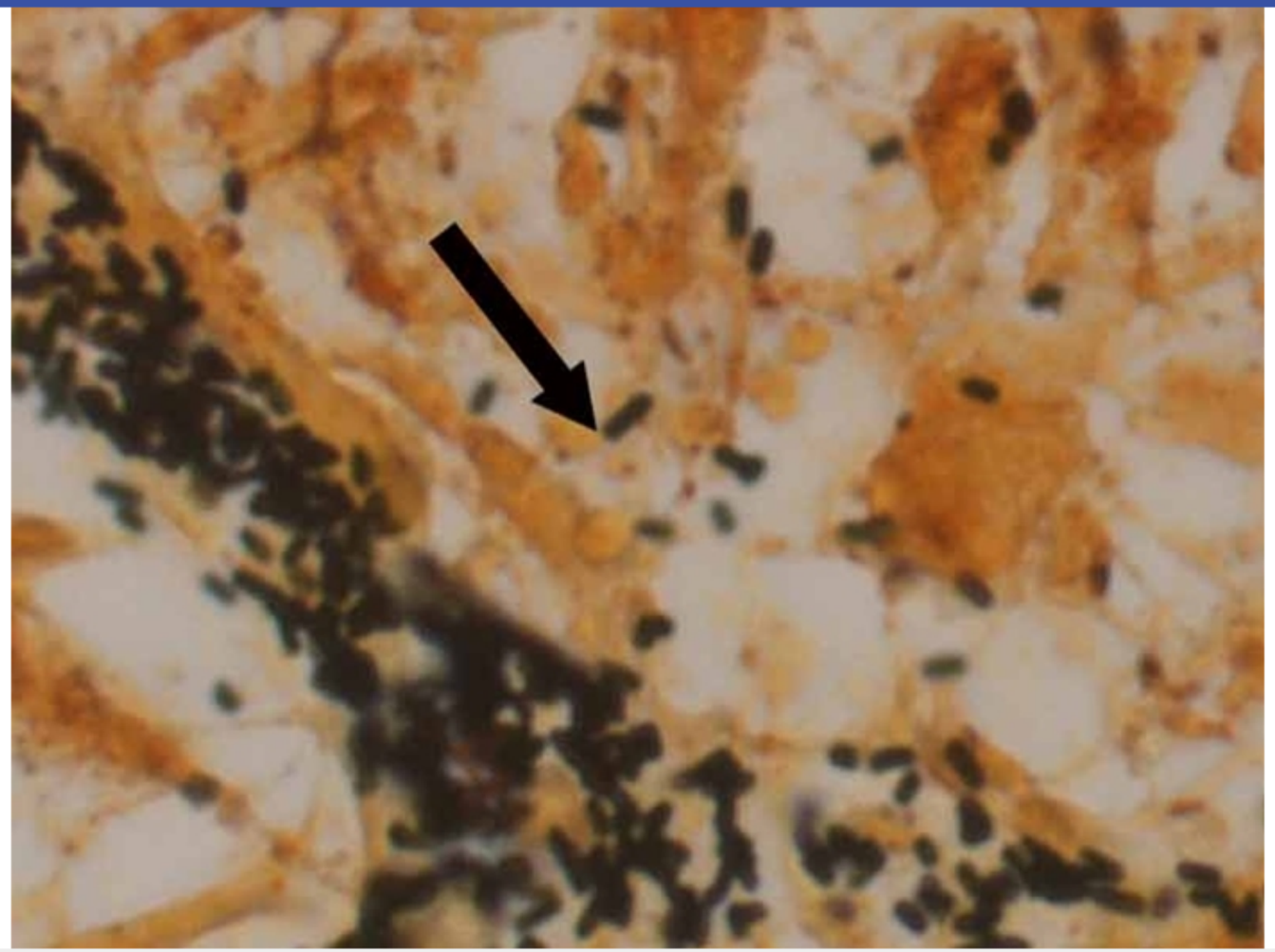

Zoom In | Zoom Out | Reset | Add To New Card | Existing Card

(Choice A) Epidemic fungal meningitis due to *Aspergillus fumigatus* has been associated with contaminated glucocorticoid injections. *Aspergillus* is not typically associated with foodborne illness.

(Choices B and D) Cytomegalovirus and herpes simplex virus can cause a variety of clinical syndromes in immunocompromised patients, including encephalitis, esophagitis, pneumonitis, and colitis. These viruses are ubiquitous and not associated with foodborne outbreaks.

(Choice C) Foodborne outbreaks of *Escherichia coli* O157:H7 have been linked to the ingestion of contaminated beef (primarily) and are usually associated with hemorrhagic colitis. Patients may also develop hemolytic uremic syndrome. Meningitis and neonatal infection would be atypical.

(Choice F) *Neisseria meningitidis* causes sepsis and acute meningitis. It is transmitted primarily by respiratory droplets; most cases occur in those who live in congregate settings (eg, dormitories, military barracks).

(Choice G) *Streptococcus pneumoniae* is a common cause of bacterial meningitis in elderly and immunocompromised individuals but is not associated with foodborne outbreaks.

(Choice H) *Toxoplasma* is associated with meningoencephalitis in immunocompromised patients (eg, advanced AIDS). It is usually acquired by contact with cat feces, although transmission via undercooked lamb and pork has also been reported.

Educational objective:
Listeria is a relatively common foodborne illness associated with outbreaks after the consumption of contaminated food, particularly processed meats and dairy products. Healthy patients may develop gastroenteritis; patients with impaired cell-mediated immunity are at risk for invasive infection (eg, sepsis, meningoencephalitis) and listeriosis in pregnancy is associated with adverse fetal outcomes (eg, fetal death, premature birth).

References

- Listeria monocytogenes: epidemiology, human disease, and mechanisms of brain invasion.

Microbiology	Infectious Diseases	Meningitis
Subject	System	Topic

Copyright © UWorld. All rights reserved.

1
2
3
4
5
6
7
8
9
10
11
12
13
14
15
16
17
18
19
20
21
22
23
24
25
26
27
28
29
30
31

A 23-year-old man comes to the office due to penile ulcers that appeared after unprotected sexual intercourse. Physical examination shows 3 subcentimeter ulcers on the penile shaft. Microscopic examination of a scraping from an ulcer base reveals the following:

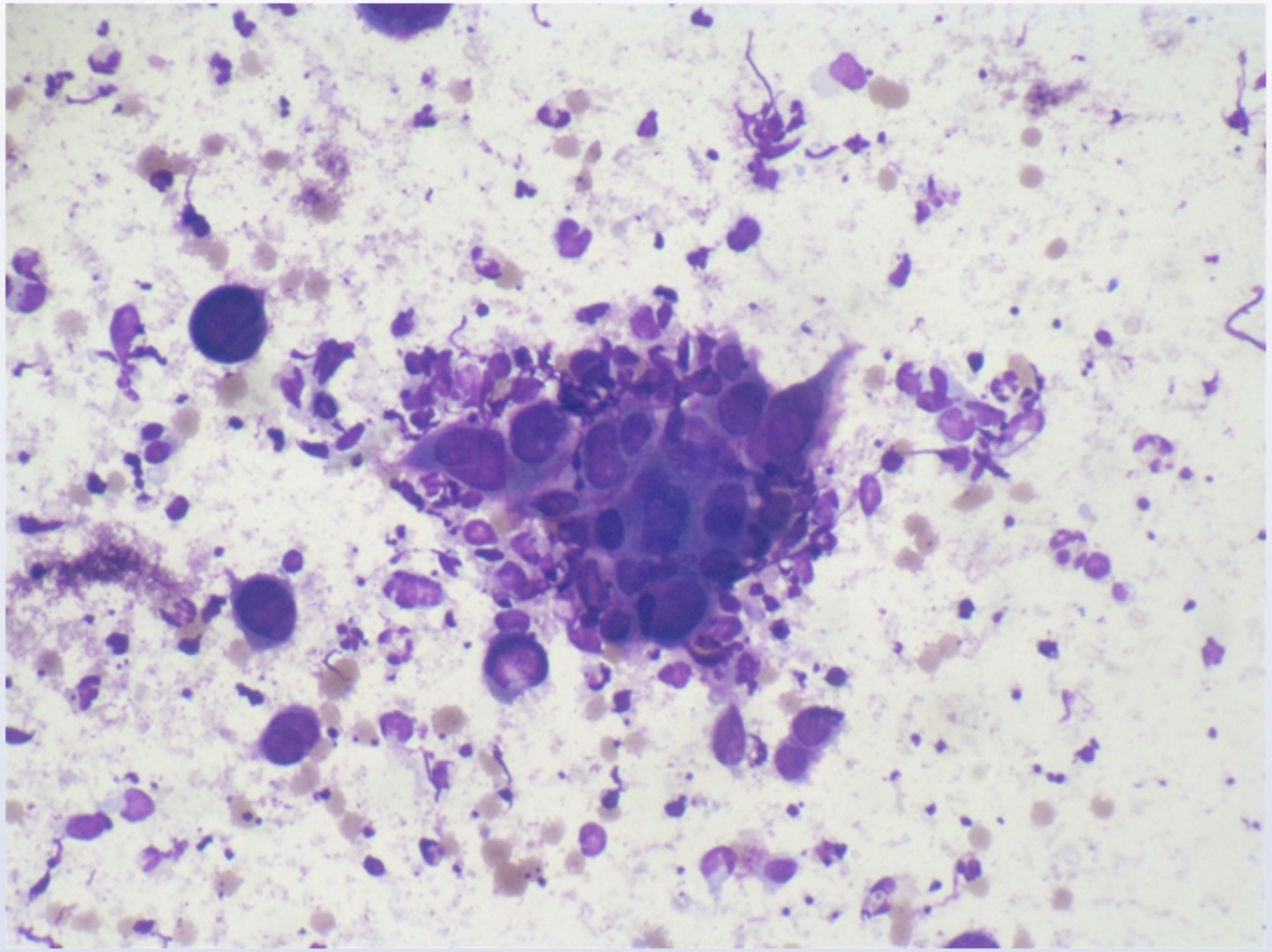

Which of the following medications is most appropriate for this patient?

1
2
3
4
5
6
7
8
9
10
11
12
13
14
15
16
17
18
19
20
21
22
23
24
25
26
27
28
29
30
31

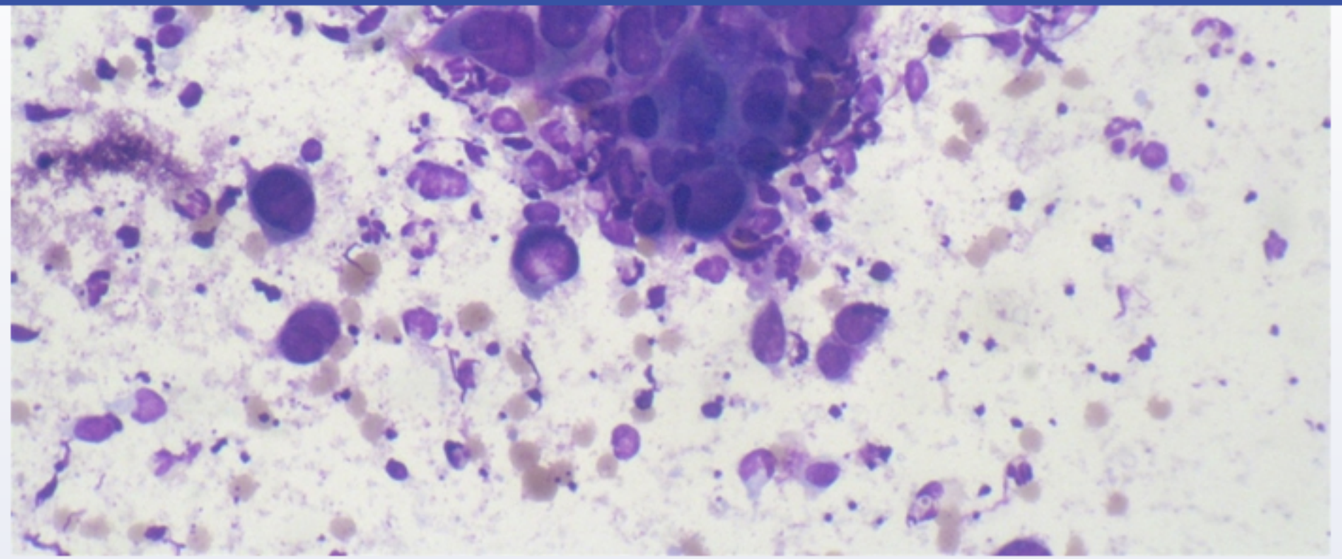

Which of the following medications is most appropriate for this patient?

- A. Acyclovir
- B. Azithromycin
- C. Doxycycline
- D. Fluconazole
- E. Penicillin
- F. Permethrin

Submit

1
2
3
4
5
6
7
8
9
10
11
12
13
14
15
16
17
18
19
20
21
22
23
24
25
26
27
28
29
30
31

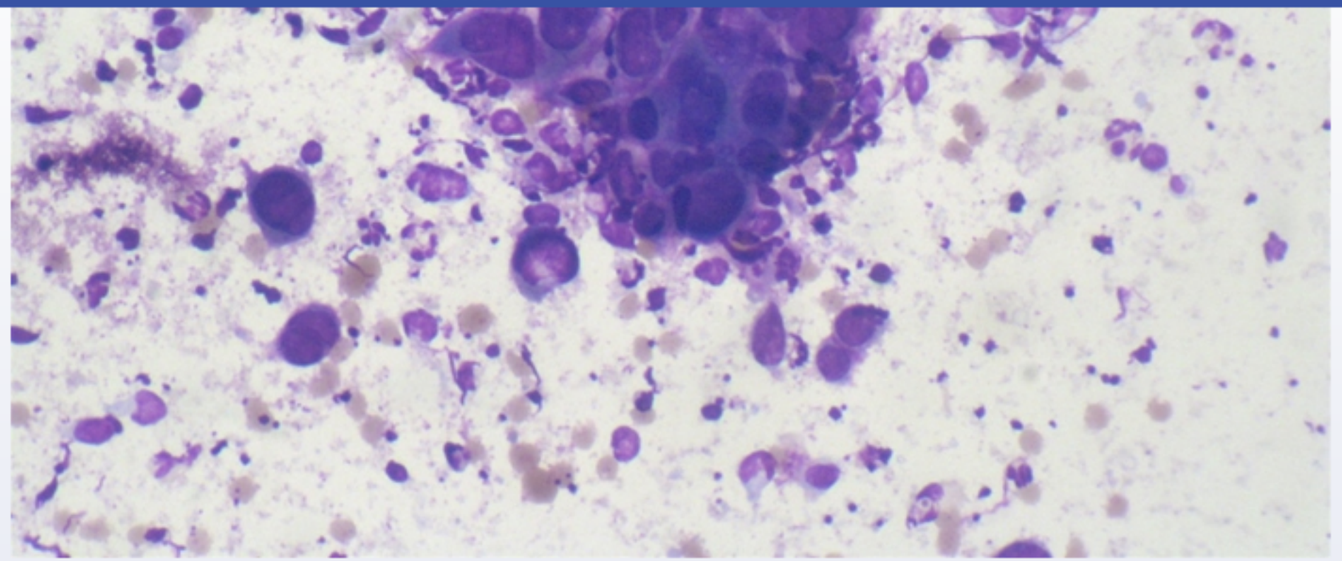

Which of the following medications is most appropriate for this patient?

- A. Acyclovir (72%)
- B. Azithromycin (6%)
- C. Doxycycline (6%)
- D. Fluconazole (0%)
- E. Penicillin (12%)
- F. Permethrin (1%)

Omitted
Correct answer

72%
Answered correctly

07 secs
Time Spent

03/08/2020
Last Updated

1
2
3
4
5
6
7
8
9
10
11
12
13
14
15
16
17
18
19
20
21
22
23
24
25
26
27
28
29
30
31

Herpes simplex

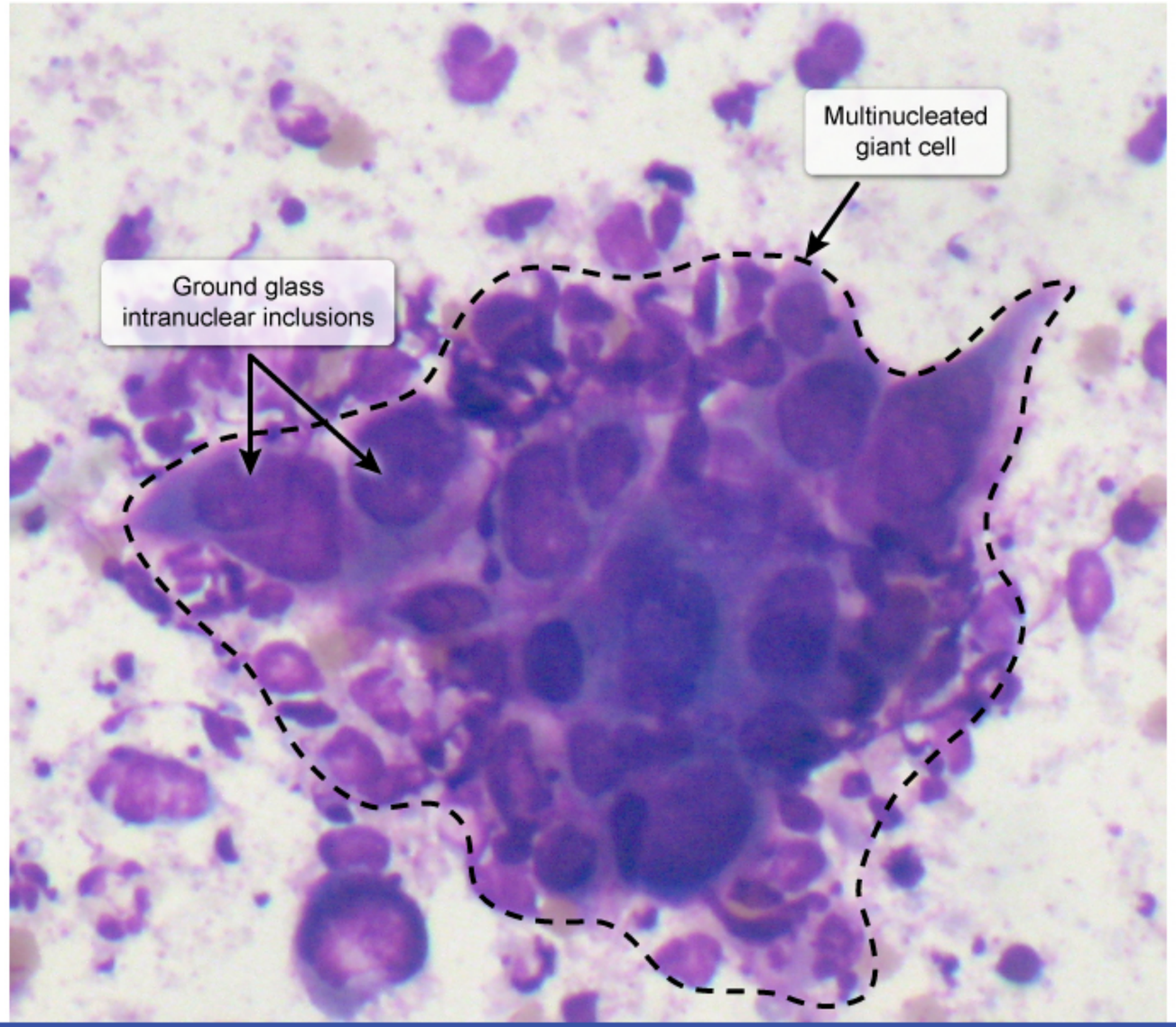

Microscopy of this patient's penis ulcer reveals a **multinucleated giant cell** with intracytoplasmic ground-glass opacities, raising strong suspicion for herpes simplex virus **(HSV) infection**. Genital HSV is usually caused by HSV type 2, which is spread primarily via direct skin contact with herpetic sores or infected genital secretions during sexual activity. Initial infection is often characterized by **painful genital ulcers**, fever, lymphadenopathy, and dysuria. Symptoms typically resolve within a few weeks, but latent infection develops in the dorsal root ganglia and can periodically reactivate, leading to recurrence.

HSV is generally diagnosed by cell culture or PCR, but **Tzanck smear** (as seen above) can reveal the cytopathic effects of the virus (eg, multinucleated giant cells, acantholytic cells, keratinocyte ballooning, nuclear molding). Oral antiviral agents such as **acyclovir**, a competitive inhibitor of viral DNA polymerase, help speed symptom resolution.

(Choice B) Azithromycin can be used to treat chancroid, which is characterized by the formation of a papule that evolves into a pustule and then an ulcer. However, it is very rare in the United States and is caused by the gram-negative organism *Haemophilus ducreyi*; multinucleated giant cells would not be seen.

(Choice C) Doxycycline can treat lymphogranuloma venereum, a genital infection caused by certain serotypes of *Chlamydia trachomatis*. This disease is marked by the formation of a small genital ulcer, followed by significant lymph node inflammation and pain in the inguinal or femoral region. *C trachomatis* appears as intravacuolar organisms in macrophages.

(Choice D) Fluconazole can treat *Candida balanitis*, which is typically marked by a painful, pruritic, erythematous rash. Yeasts and pseudohyphae can often be seen on microscopy.

(Choice E) Penicillin can be used to treat syphilis, a spirochetal infection caused by *Treponema pallidium* that begins with the formation of a chancre (painless ulcer with heaped-up borders and a clean base) at the site of inoculation. Diagnosis is generally made with serologic testing because *T pallidium* cannot be cultured; multiple ulcers and multinucleated giant cells are not typically seen.

(Choice F) Permethrin can be used to treat pubic lice, which are associated with significant pruritus of hairy genital areas. Lice can generally be visualized on the hair shaft.

Educational objective:
Herpes simplex virus is a common, sexually transmitted infection marked by the formation of painful genital ulcers. Tzanck smear can reveal the characteristic cytopathic effects of the virus, including multinucleated giant cells, ground-glass opacities, acantholytic cells, keratinocyte ballooning, and nuclear molding.

HSV is generally diagnosed by cell culture or PCR, but **Tzanck smear** (as seen above) can reveal the cytopathic effects of the virus (eg, multinucleated giant cells, acantholytic cells, keratinocyte ballooning, nuclear molding). Oral antiviral agents such as **acyclovir**, a competitive inhibitor of viral DNA polymerase, help speed symptom resolution.

(Choice B) Azithromycin can be used to treat chancroid, which is characterized by the formation of a papule that evolves into a pustule and then an ulcer. However, it is very rare in the United States and is caused by the gram-negative organism *Haemophilus ducreyi*; multinucleated giant cells would not be seen.

(Choice C) Doxycycline can treat lymphogranuloma venereum, a genital infection caused by certain serotypes of *Chlamydia trachomatis*. This disease is marked by the formation of a small genital ulcer, followed by significant lymph node inflammation and pain in the inguinal or femoral region. *C trachomatis* appears as intravacuolar organisms in macrophages.

(Choice D) Fluconazole can treat *Candida balanitis*, which is typically marked by a painful, pruritic, erythematous rash. Yeasts and pseudohyphae can often be seen on microscopy.

(Choice E) Penicillin can be used to treat syphilis, a spirochetal infection caused by *Treponema pallidium* that begins with the formation of a chancre (painless ulcer with heaped-up borders and a clean base) at the site of inoculation. Diagnosis is generally made with serologic testing because *T pallidium* cannot be cultured; multiple ulcers and multinucleated giant cells are not typically seen.

(Choice F) Permethrin can be used to treat pubic lice, which are associated with significant pruritus of hairy genital areas. Lice can generally be visualized on the hair shaft.

Educational objective:
Herpes simplex virus is a common, sexually transmitted infection marked by the formation of painful genital ulcers. Tzanck smear can reveal the characteristic cytopathic effects of the virus, including multinucleated giant cells, ground-glass opacities, acantholytic cells, keratinocyte ballooning, and nuclear molding.

Microbiology	Infectious Diseases	HSV infection
Subject	System	Topic

Copyright © UWorld. All rights reserved.

1
2
3
4
5
6
7
8
9
10
11
12
13
14
15
16
17
18
19
20
21
22
23
24
25
26
27
28
29
30
31

Exhibit Display

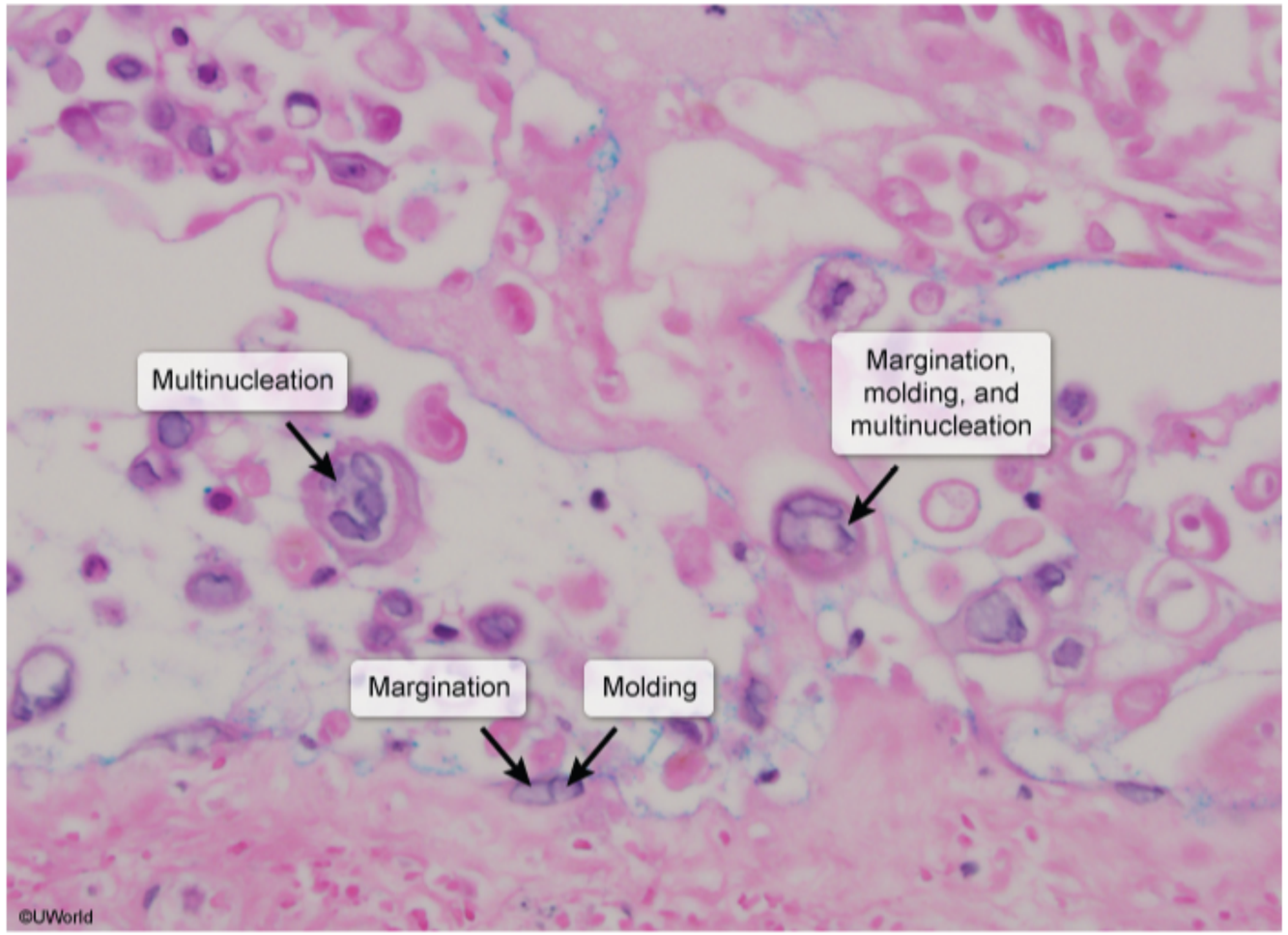

Zoom In | Zoom Out | Reset | Add To New Card | Existing Card

pseudohyphae can often be seen on microscopy.

A 74-year-old man is hospitalized with acute urinary retention complicated by urosepsis. He has a urinary catheter placed and is started on intravenous antibiotics. The patient requires endotracheal intubation and mechanical ventilation for 24 hours but is extubated successfully on the second hospitalization day. On the third day of hospitalization, he develops fever and right jaw pain. Physical examination shows firm swelling of the preauricular area on the right side extending to the angle of the mandible. Which of the following serum markers is most helpful for confirming the diagnosis?

- A. Alkaline phosphatase
- B. Amylase
- C. Gamma-glutamyl transpeptidase
- D. Lipase
- E. Parathyroid hormone

Submit

A 74-year-old man is hospitalized with acute urinary retention complicated by urosepsis. He has a urinary catheter placed and is started on intravenous antibiotics. The patient requires endotracheal intubation and mechanical ventilation for 24 hours but is extubated successfully on the second hospitalization day. On the third day of hospitalization, he develops fever and right jaw pain. Physical examination shows firm swelling of the preauricular area on the right side extending to the angle of the mandible. Which of the following serum markers is most helpful for confirming the diagnosis?

- A. Alkaline phosphatase (25%)
- ✓ B. Amylase (50%)
- C. Gamma-glutamyl transpeptidase (15%)
- D. Lipase (4%)
- E. Parathyroid hormone (4%)

Omitted
Correct answer
B

50%
Answered correctly

02 secs
Time Spent

02/11/2020
Last Updated

Explanation

Suppurative parotitis in adults	
Risk	Decreased **salivary flow** • Medications (eg, **anticholinergics**) • Obstruction (eg, **calculi**, neoplasm)

Suppurative parotitis in adults	
Risk factors	Decreased **salivary flow** • Medications (eg, **anticholinergics**) • Obstruction (eg, **calculi**, neoplasm) • **Dehydration**, postsurgical/**intubation**
Microbiology	• ***Staphylococcus aureus***, anaerobes
Clinical presentation	• Firm, erythematous pre/postauricular swelling • Trismus, dysphagia, systemic findings (fever, chills)
Diagnosis	• Imaging (ultrasound/CT): Ductal inflammation/obstruction, frank abscess • Laboratory: Elevated serum **amylase** without pancreatitis

©UWorld

This patient's presentation suggests **parotitis**, an acute viral or bacterial infection of the parotid gland. Acute bacterial suppurative parotitis can be due to ***Staphylococcus aureus*** (most common) or mixed oral aerobes/anaerobes. Risk factors include **dehydration, intubation** (elderly postoperative patients), medications that decrease salivary flow (eg, **anticholinergics**), salivary flow obstruction (eg, salivary **calculi**, oral cavitary neoplasm), or recent intense teeth cleaning.

Suppurative parotitis usually presents with acute onset of firm and erythematous pre/postauricular **swelling** that extends to the mandible. Patients can also develop trismus, dysphagia, and systemic findings (eg, fever, chills). The diagnosis can be confirmed by **imaging** (eg, ultrasound, CT) showing parotid duct inflammation, obstruction by a stone, or sometimes abscess. As the parotid gland secretes **amylase**, suppurative parotitis can present with elevated serum amylase. However, affected patients have normal serum lipase levels without clinical evidence of pancreatitis **(Choice D)**.

(Choice A) Alkaline phosphatase is an enzyme that hydrolyzes and removes phosphate from other compounds (eg, proteins, enzymes). It is

This patient's presentation suggests **parotitis**, an acute viral or bacterial infection of the parotid gland. Acute bacterial suppurative parotitis can be due to ***Staphylococcus aureus*** (most common) or mixed oral aerobes/anaerobes. Risk factors include **dehydration, intubation** (elderly postoperative patients), medications that decrease salivary flow (eg, **anticholinergics**), salivary flow obstruction (eg, salivary **calculi**, oral cavitary neoplasm), or recent intense teeth cleaning.

Suppurative parotitis usually presents with acute onset of firm and erythematous pre/postauricular **swelling** that extends to the mandible. Patients can also develop trismus, dysphagia, and systemic findings (eg, fever, chills). The diagnosis can be confirmed by **imaging** (eg, ultrasound, CT) showing parotid duct inflammation, obstruction by a stone, or sometimes abscess. As the parotid gland secretes **amylase**, suppurative parotitis can present with elevated serum amylase. However, affected patients have normal serum lipase levels without clinical evidence of pancreatitis **(Choice D)**.

(Choice A) Alkaline phosphatase is an enzyme that hydrolyzes and removes phosphate from other compounds (eg, proteins, enzymes). It is mainly found in the bone, liver, bile ducts, and placenta. Alkaline phosphatase can be elevated in biliary conditions, bone disease (eg, osteomalacia), and leukemia/lymphoma. However, it is usually not affected by parotitis.

(Choice C) Gamma-glutamyl transpeptidase (GGT) helps convert glutathione to glutamate. It can be found in many organs, including the liver. GGT elevation suggests that alkaline phosphatase elevation is due to liver (not bone) pathology.

(Choice E) Parathyroid hormone (PTH) is secreted by the chief cells of the parathyroid gland and increases serum calcium to maintain calcium homeostasis. PTH has effects on the kidney and bone but is not elevated with parotitis.

Educational objective:
Acute bacterial parotitis occurs more commonly in elderly postoperative patients who are intubated or dehydrated. *Staphylococcus aureus* is the most common bacterial etiology. Diagnosis can be confirmed by imaging and an elevated serum amylase level (with a normal serum lipase level and no evidence of pancreatitis).

References

- Acute bacterial suppurative parotitis: microbiology and management.
- Acute postsurgical suppurative parotitis: current prevalence at Hospital das Clínicas, São Paulo University Medical School.

Suppurative parotitis usually presents with acute onset of firm and erythematous pre/postauricular **swelling** that extends to the mandible. Patients can also develop trismus, dysphagia, and systemic findings (eg, fever, chills). The diagnosis can be confirmed by **imaging** (eg, ultrasound, CT) showing parotid duct inflammation, obstruction by a stone, or sometimes abscess. As the parotid gland secretes **amylase**, suppurative parotitis can present with elevated serum amylase. However, affected patients have normal serum lipase levels without clinical evidence of pancreatitis **(Choice D)**.

(Choice A) Alkaline phosphatase is an enzyme that hydrolyzes and removes phosphate from other compounds (eg, proteins, enzymes). It is mainly found in the bone, liver, bile ducts, and placenta. Alkaline phosphatase can be elevated in biliary conditions, bone disease (eg, osteomalacia), and leukemia/lymphoma. However, it is usually not affected by parotitis.

(Choice C) Gamma-glutamyl transpeptidase (GGT) helps convert glutathione to glutamate. It can be found in many organs, including the liver. GGT elevation suggests that alkaline phosphatase elevation is due to liver (not bone) pathology.

(Choice E) Parathyroid hormone (PTH) is secreted by the chief cells of the parathyroid gland and increases serum calcium to maintain calcium homeostasis. PTH has effects on the kidney and bone but is not elevated with parotitis.

Educational objective:
Acute bacterial parotitis occurs more commonly in elderly postoperative patients who are intubated or dehydrated. *Staphylococcus aureus* is the most common bacterial etiology. Diagnosis can be confirmed by imaging and an elevated serum amylase level (with a normal serum lipase level and no evidence of pancreatitis).

References

- Acute bacterial suppurative parotitis: microbiology and management.
- Acute postsurgical suppurative parotitis: current prevalence at Hospital das Clínicas, São Paulo University Medical School.

Microbiology	Infectious Diseases	Acute parotitis
Subject	System	Topic

Copyright © UWorld. All rights reserved.

1
2
3
4
5
6
7
8
9
10
11
12
13
14
15
16
17
18
19
20
21
22
23
24
25
26
27
28
29
30
31

A 21-year-old man is brought to the emergency department in a stuporous condition. He returned from a family visit to Mexico 2 weeks ago. One week ago, the patient began developing high-grade fever, headaches, severe myalgias, and joint pains. He had similar symptoms following a trip to Mexico 5 years ago, but at that time the symptoms did not progress and instead resolved spontaneously within a few days. Temperature is 38.3 C (101 F), blood pressure is 80/50 mm Hg, and pulse is 128/min. Examination shows a diffuse maculopapular rash, multiple purpuric lesions, and hepatomegaly. Laboratory studies show marked thrombocytopenia, leukopenia, and elevated liver aminotransferases. Which of the following is the most likely mechanism for this patient's current severe illness?

A. Antigenic drift in the virus

B. Blunted T-lymphocyte response

C. Infection with a different viral serotype

D. Larger viral inoculation dose

E. Viral superinfection

Submit

A 21-year-old man is brought to the emergency department in a stuporous condition. He returned from a family visit to Mexico 2 weeks ago. One week ago, the patient began developing high-grade fever, headaches, severe myalgias, and joint pains. He had similar symptoms following a trip to Mexico 5 years ago, but at that time the symptoms did not progress and instead resolved spontaneously within a few days. Temperature is 38.3 C (101 F), blood pressure is 80/50 mm Hg, and pulse is 128/min. Examination shows a diffuse maculopapular rash, multiple purpuric lesions, and hepatomegaly. Laboratory studies show marked thrombocytopenia, leukopenia, and elevated liver aminotransferases. Which of the following is the most likely mechanism for this patient's current severe illness?

A. Antigenic drift in the virus (14%)

B. Blunted T-lymphocyte response (10%)

✓ C. Infection with a different viral serotype (45%)

D. Larger viral inoculation dose (4%)

E. Viral superinfection (25%)

Omitted
Correct answer
C

45%
Answered correctly

02 secs
Time Spent

05/30/2020
Last Updated

Explanation

Clinical features of dengue fever	
Classic dengue fever	• Flulike febrile illness with marked myalgias & joint pains ("break-bone fever") • Retro-orbital pain

Clinical features of dengue fever	
Classic dengue fever	• Flulike febrile illness with marked myalgias & joint pains ("break-bone fever") • Retro-orbital pain • Rash ("white islands in sea of red")
Dengue hemorrhagic fever	• Increased vascular permeability • Thrombocytopenia (<100,000/mm^3) • Spontaneous bleeding → shock • Positive tourniquet test (petechiae after sphygmomanometer cuff inflation for 5 minutes)
Management	• Supportive care

This patient's presentation after recent travel to an endemic area suggests **dengue hemorrhagic fever (DHF)**. Dengue viruses are transmitted by the *Aedes* mosquito and are single-stranded RNA viruses (genus *Flavivirus*) with 4 different serotypes (DENV1-4). Primary (first) infection can be asymptomatic or cause a self-limited disease in most adults. Symptomatic disease can cause high-grade fever, headache, retro-orbital pain, bleeding (eg, epistaxis, petechiae/purpura), diffuse macular rash, muscle and joint pain ("break-bone fever"), leukopenia, thrombocytopenia, and elevated liver enzymes.

Primary infection leads to lifelong immunity against the same serotype, but individuals can be infected with a different serotype. **Secondary** infection with a **different** viral **serotype** can cause a **more severe** illness, possibly due to antibody-dependent enhancement of infection, enhanced immune complex formation, and/or accelerated (not blunted) T-lymphocyte responses **(Choice B)**. DHF, which can be a serious manifestation of secondary infection, is due to increased capillary permeability and can be manifested by marked thrombocytopenia, prolonged fever, respiratory/circulatory failure, and shock. Patients also develop more significant hemorrhagic tendencies (eg, petechiae with tourniquet application) and spontaneous bleeding.

(Choice A) Antigenic drift refers to minor changes in viral structure that can increase the infectivity rate and lead to localized outbreaks. Antigenic drift is common annually with the influenza virus but is not typically associated with the dengue virus.

(Choice D) The severity of secondary infection with dengue is usually independent of the dose of viral inoculation.

(Choice E) Viral superinfection can occur with hepatitis viruses such as hepatitis D, which usually co-infects with hepatitis B. However, secondary

This patient's presentation after recent travel to an endemic area suggests **dengue hemorrhagic fever (DHF)**. Dengue viruses are transmitted by the *Aedes* mosquito and are single-stranded RNA viruses (genus *Flavivirus*) with 4 different serotypes (DENV1-4). Primary (first) infection can be asymptomatic or cause a self-limited disease in most adults. Symptomatic disease can cause high-grade fever, headache, retro-orbital pain, bleeding (eg, epistaxis, petechiae/purpura), diffuse macular rash, muscle and joint pain ("break-bone fever"), leukopenia, thrombocytopenia, and elevated liver enzymes.

Primary infection leads to lifelong immunity against the same serotype, but individuals can be infected with a different serotype. **Secondary** infection with a **different** viral **serotype** can cause a **more severe** illness, possibly due to antibody-dependent enhancement of infection, enhanced immune complex formation, and/or accelerated (not blunted) T-lymphocyte responses **(Choice B)**. DHF, which can be a serious manifestation of secondary infection, is due to increased capillary permeability and can be manifested by marked thrombocytopenia, prolonged fever, respiratory/circulatory failure, and shock. Patients also develop more significant hemorrhagic tendencies (eg, petechiae with tourniquet application) and spontaneous bleeding.

(Choice A) Antigenic drift refers to minor changes in viral structure that can increase the infectivity rate and lead to localized outbreaks. Antigenic drift is common annually with the influenza virus but is not typically associated with the dengue virus.

(Choice D) The severity of secondary infection with dengue is usually independent of the dose of viral inoculation.

(Choice E) Viral superinfection can occur with hepatitis viruses such as hepatitis D, which usually co-infects with hepatitis B. However, secondary infection with dengue is due to a different viral serotype rather than superinfection.

Educational objective:
Dengue viruses are single-stranded RNA viruses with 4 different serotypes. Primary (first) infection can be asymptomatic or cause a self-limited disease in most adults. Secondary infection is due to infection with a different viral serotype and usually causes more severe illness.

References

- The pathology of dengue hemorrhagic fever.

Microbiology	Infectious Diseases	Dengue fever
Subject	System	Topic

A 10-week-old boy is brought to the office for a follow-up visit. As part of his routine immunization schedule, the patient received the first dose of the *Haemophilus influenzae* type b (Hib) conjugate vaccine when he was 8 weeks old. However, following vaccine administration, he developed anaphylaxis, requiring epinephrine administration and hospitalization. As a result, the decision was made not to administer additional doses of the Hib vaccine. The patient was born full-term by uncomplicated vaginal delivery and has otherwise been healthy. Physical examination is unremarkable. His older brother has completed the full vaccination course. This patient is at highest risk of which of the following infections compared to his brother?

A. Acute bronchiolitis
B. Bacterial conjunctivitis
C. Meningitis
D. Otitis media
E. Sinusitis

Submit

1
2
3
4
5
6
7
8
9
10
11
12
13
14
15
16
17
18
19
20
21
22
23
24
25
26
27
28
29
30
31

A 10-week-old boy is brought to the office for a follow-up visit. As part of his routine immunization schedule, the patient received the first dose of the *Haemophilus influenzae* type b (Hib) conjugate vaccine when he was 8 weeks old. However, following vaccine administration, he developed anaphylaxis, requiring epinephrine administration and hospitalization. As a result, the decision was made not to administer additional doses of the Hib vaccine. The patient was born full-term by uncomplicated vaginal delivery and has otherwise been healthy. Physical examination is unremarkable. His older brother has completed the full vaccination course. This patient is at highest risk of which of the following infections compared to his brother?

- A. Acute bronchiolitis (4%)
- B. Bacterial conjunctivitis (0%)
- ✓ C. Meningitis (72%)
- D. Otitis media (19%)
- E. Sinusitis (1%)

Omitted
Correct answer
C

72%
Answered correctly

02 secs
Time Spent

01/19/2020
Last Updated

Explanation

Haemophilus influenzae is a gram-negative coccobacillus that can be either encapsulated (serotypes a-f) or unencapsulated (nontypeable). *H influenzae* **type b** (Hib) is the most invasive strain due to its polyribosylribitol phosphate **(PRP) capsule**, which **inhibits complement-mediated phagocytosis** and allows it to invade tissues and survive in the bloodstream.

1
2
3
4
5
6
7
8
9
10
11
12
13
14
15
16
17
18
19
20
21
22
23
24
25
26
27
28
29
30
31

Avoidance of phagocytosis by *Haemophilus influenzae*

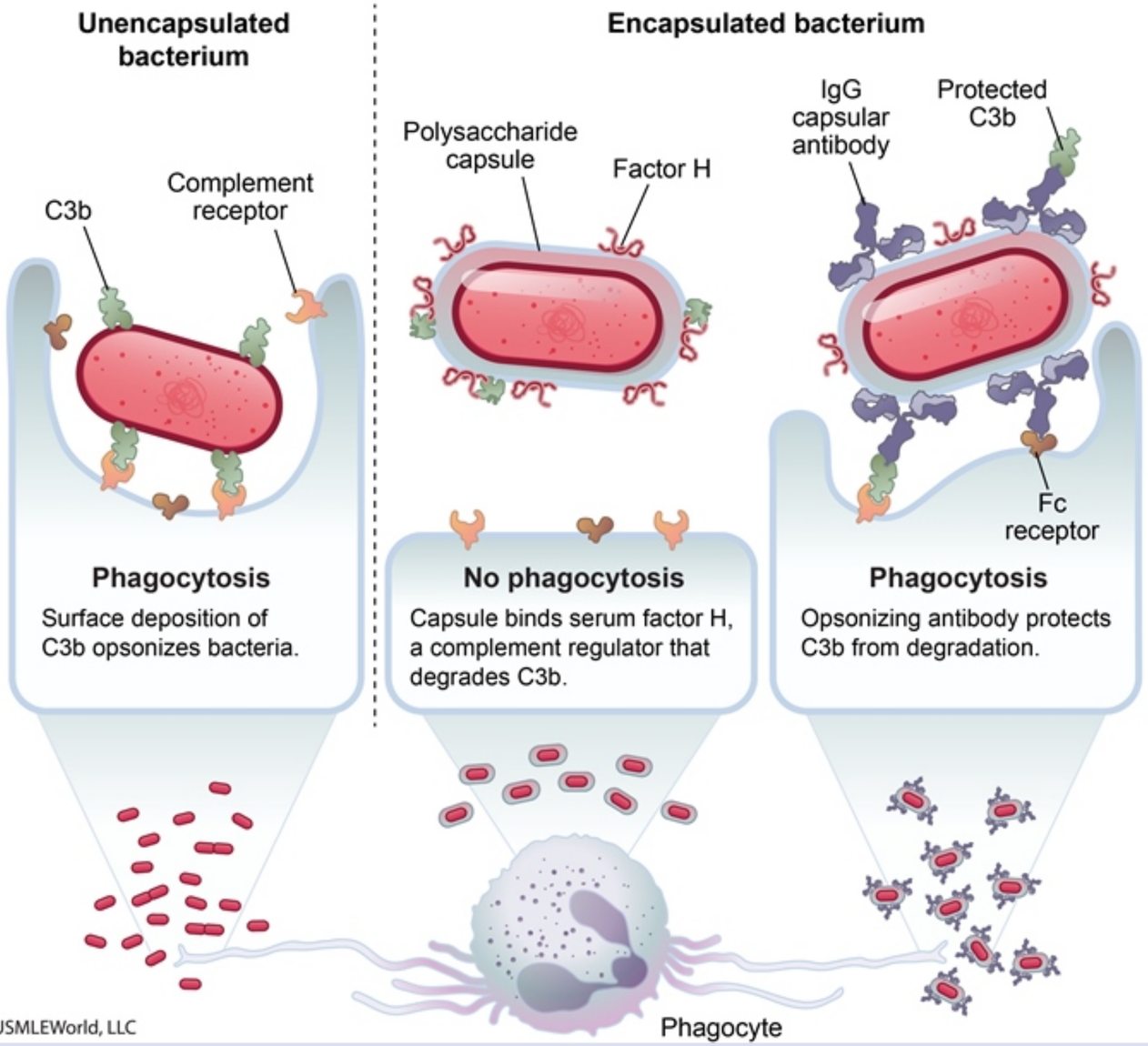

©USMLEWorld, LLC

Haemophilus influenzae is a gram-negative coccobacillus that can be either encapsulated (serotypes a-f) or unencapsulated (nontypeable). *H influenzae* **type b** (Hib) is the most invasive strain due to its polyribosylribitol phosphate **(PRP) capsule**, which **inhibits complement-mediated phagocytosis** and allows it to invade tissues and survive in the bloodstream.

During the first months of life, transient immunity to Hib is accomplished by IgG antibodies acquired transplacentally from the mother while in utero. The **Hib vaccine** is administered beginning at age 2 months to provide continued immunity. The immunization is composed of PRP conjugated with a protein toxoid (eg, tetanus, diphtheria), which induces a T cell–dependent immune response. The production of opsonizing anticapsular antibodies by B-lymphocytes allows for efficient phagocytosis of the bacterium. Without the protection from the vaccine, this child is at risk for **invasive disease** caused by Hib, such as **meningitis**, bacteremia, pneumonia, and epiglottitis.

(Choice A) Bronchiolitis is a lower respiratory infection that is almost always viral in etiology. Respiratory syncytial virus, rhinovirus, influenza, and parainfluenza are commonly implicated, but not *H influenzae*.

(Choices B, D, and E) Most causes of bacterial conjunctivitis, acute otitis media, and sinusitis in childhood are due to *Streptococcus pneumoniae*, nontypeable *H influenzae*, and *Moraxella catarrhalis*. The Hib vaccine (which has no effect on nontypeable *H influenzae*) will not protect a child from these infections.

Educational objective:
The *Haemophilus influenzae* type b (Hib) vaccine induces anticapsular antibodies that facilitate complement-mediated phagocytosis of the bacterium. The vaccination series has drastically reduced the incidence of invasive disease caused by Hib, such as meningitis, bacteremia, pneumonia, and epiglottitis.

References

- Pediatric invasive Haemophilus influenzae infections in Israel in the era of Haemophilus influenzae type b vaccine: a nationwide prospective study.

Microbiology	Infectious Diseases	Meningitis
Subject	System	Topic

Copyright © UWorld. All rights reserved.

1
2
3
4
5
6
7
8
9
10
11
12
13
14
15
16
17
18
19
20
21
22
23
24
25
26
27
28
29
30
31

A 35-year-old woman comes to the office due to a vulvar lesion. She has also experienced occasional headaches and memory loss recently. The patient has had unprotected sexual intercourse with multiple partners. Cardiovascular examination is notable for a diastolic murmur with a prominent second heart sound. There is a painless indurated nodule on her vulva. Cervical cultures are negative for gonorrhea, but a serum Venereal Disease Research Laboratory (VDRL) test is positive. Chest x-ray reveals calcifications at the level of the ascending aortic arch. Blood cultures are negative. Lumbar puncture shows mild pleocytosis and a positive VDRL result. HIV testing is negative. Which of the following best describes this patient's vulvar lesion?

A. Chancre
B. Condylomata acuminata
C. Condylomata lata
D. Granuloma inguinale
E. Gumma

Submit

1
2
3
4
5
6
7
8
9
10
11
12
13
14
15
16
17
18
19
20
21
22
23
24
25
26
27
28
29
30
31

A 35-year-old woman comes to the office due to a vulvar lesion. She has also experienced occasional headaches and memory loss recently. The patient has had unprotected sexual intercourse with multiple partners. Cardiovascular examination is notable for a diastolic murmur with a prominent second heart sound. There is a painless indurated nodule on her vulva. Cervical cultures are negative for gonorrhea, but a serum Venereal Disease Research Laboratory (VDRL) test is positive. Chest x-ray reveals calcifications at the level of the ascending aortic arch. Blood cultures are negative. Lumbar puncture shows mild pleocytosis and a positive VDRL result. HIV testing is negative. Which of the following best describes this patient's vulvar lesion?

A. Chancre (28%)
B. Condylomata acuminata (4%)
C. Condylomata lata (23%)
D. Granuloma inguinale (1%)
✓ E. Gumma (42%)

Omitted
Correct answer
E

42%
Answered correctly

02 secs
Time Spent

01/22/2020
Last Updated

Explanation

This patient with neurosyphilis (headaches, memory loss, cerebrospinal fluid with Venereal Disease Research Laboratory positivity, pleocytosis) likely has cardiovascular syphilis (asymptomatic murmur with loud second heart sound [S2], ascending aortic arch calcification). She therefore has **late (tertiary) syphilis**, and her vulvar lesion is most likely a **gumma**. A chancre would be seen in primary syphilis **(Choice A)**, and condylomata **lata** occur during secondary syphilis **(Choice C)**.

This patient with neurosyphilis (headaches, memory loss, cerebrospinal fluid with Venereal Disease Research Laboratory positivity, pleocytosis) likely has cardiovascular syphilis (asymptomatic murmur with loud second heart sound [S2], ascending aortic arch calcification). She therefore has **late (tertiary) syphilis**, and her vulvar lesion is most likely a **gumma**. A chancre would be seen in primary syphilis **(Choice A)**, and condylomata **lata** occur during secondary syphilis **(Choice C)**.

The clinical presentation of syphilis occurs in well-defined stages:

- **Primary syphilis** manifests as a painless ulceration with raised, indurated borders. This **chancre** develops at the *Treponema pallidum* inoculation site (most commonly penis or vulva) 1-3 weeks after contact and resolves in 3-6 weeks. The organism commonly disseminates systemically during this stage.
- **Secondary syphilis**, a bacteremic stage that develops 5-10 weeks following chancre resolution, presents with a diffuse macular **rash,** as shown in the exhibit, encompassing the palms and soles. **Condylomata lata**, large gray wartlike growths typically appearing in the genital/perineal region, are another typical manifestation.
- **Latent syphilis** is an asymptomatic period divided into early latent (infection within past year) and late latent (infection >1 year ago).
- **Late (tertiary) syphilis** develops many years after infection in untreated individuals. **Gummas** are characteristic and often begin as painless, indurated granulomatous lesions that progress to white-gray rubbery lesions that may ulcerate. They are most commonly cutaneous but also appear in the subcutaneous tissue, bones, liver, and other organs. Tertiary syphilis can also manifest as cardiovascular involvement with **ascending aortic aneurysms** (with calcification seen on x-ray) and resultant aortic valve **insufficiency** (murmur, high-pitched tambour S2).

Neurosyphilis, which may be asymptomatic or cause subacute meningoencephalitis, tabes dorsalis, or other neurologic sequelae, is a common manifestation of late syphilis but can occur at **any** stage.

(Choice B) Condylomata acuminata are anogenital warts due to human papillomavirus (HPV), the causative agent of cervical cancer. Common strains associated with condylomata acuminata are HPV 6 and 11, which have low oncogenic potential.

(Choice D) Patients with granuloma inguinale, a sexually transmitted disease caused by *Klebsiella granulomatis* (previously *Calymmatobacterium granulomatis*), can have inguinal swelling, ulcers, abscesses, and fistulas. Gram staining of the lesions reveals cells with rod-shaped intracytoplasmic inclusions (Donovan bodies).

inoculation site (most commonly penis or vulva) 1-3 weeks after contact and resolves in 3-6 weeks. The organism commonly disseminates systemically during this stage.

- **Secondary syphilis**, a bacteremic stage that develops 5-10 weeks following chancre resolution, presents with a diffuse macular **rash,** as shown in the exhibit, encompassing the palms and soles. **Condylomata lata**, large gray wartlike growths typically appearing in the genital/perineal region, are another typical manifestation.
- **Latent syphilis** is an asymptomatic period divided into early latent (infection within past year) and late latent (infection >1 year ago).
- **Late (tertiary) syphilis** develops many years after infection in untreated individuals. **Gummas** are characteristic and often begin as painless, indurated granulomatous lesions that progress to white-gray rubbery lesions that may ulcerate. They are most commonly cutaneous but also appear in the subcutaneous tissue, bones, liver, and other organs. Tertiary syphilis can also manifest as cardiovascular involvement with **ascending aortic aneurysms** (with calcification seen on x-ray) and resultant aortic valve **insufficiency** (murmur, high-pitched tambour S2).

Neurosyphilis, which may be asymptomatic or cause subacute meningoencephalitis, tabes dorsalis, or other neurologic sequelae, is a common manifestation of late syphilis but can occur at **any** stage.

(Choice B) Condylomata acuminata are anogenital warts due to human papillomavirus (HPV), the causative agent of cervical cancer. Common strains associated with condylomata acuminata are HPV 6 and 11, which have low oncogenic potential.

(Choice D) Patients with granuloma inguinale, a sexually transmitted disease caused by *Klebsiella granulomatis* (previously *Calymmatobacterium granulomatis*), can have inguinal swelling, ulcers, abscesses, and fistulas. Gram staining of the lesions reveals cells with rod-shaped intracytoplasmic inclusions (Donovan bodies).

Educational objective:
The clinical presentation of tertiary syphilis includes cardiovascular involvement and gummas. Gummas are necrotizing granulomas occurring on the skin, mucosa, subcutaneous tissue, and bones and within other organs. Neurosyphilis can occur at any stage of infection.

Microbiology	Infectious Diseases	Syphilis
Subject	System	Topic

Copyright © UWorld. All rights reserved.

inoculation site (most commonly penis or vulva) 1-3 weeks after contact and resolves in 3-6 weeks. The organism commonly disseminates

Exhibit Display

Zoom In | Zoom Out | Reset | Add To New Card | Existing Card

1
2
3
4
5
6
7
8
9
10
11
12
13
14
15
16
17
18
19
20
21
22
23
24
25
26
27
28
29
30
31

A 23-year-old woman comes to the emergency department due to 4 days of intermittent fever, chills, and diaphoresis accompanied by fatigue, myalgia, and dull headache. She recently returned from a 3-month trip to India, where she worked for a nongovernmental organization. The patient had similar symptoms during her first month abroad that improved after several days of treatment. She has no other medical history and takes no medications. Temperature is 38.3 C (101 F), blood pressure is 110/70 mm Hg, and pulse is 100/min. Physical examination shows mild jaundice and hepatosplenomegaly. Laboratory results reveal anemia and elevated indirect bilirubin levels. A peripheral blood smear using Giemsa stain shows intraerythrocytic ringed inclusions. This patient's current symptoms are most likely due to reactivation of a dormant infection in which of the following?

A. Gall bladder
B. Liver
C. Lung
D. Lymph nodes
E. Red blood cells
F. Spleen

Submit

A 23-year-old woman comes to the emergency department due to 4 days of intermittent fever, chills, and diaphoresis accompanied by fatigue, myalgia, and dull headache. She recently returned from a 3-month trip to India, where she worked for a nongovernmental organization. The patient had similar symptoms during her first month abroad that improved after several days of treatment. She has no other medical history and takes no medications. Temperature is 38.3 C (101 F), blood pressure is 110/70 mm Hg, and pulse is 100/min. Physical examination shows mild jaundice and hepatosplenomegaly. Laboratory results reveal anemia and elevated indirect bilirubin levels. A peripheral blood smear using Giemsa stain shows intraerythrocytic ringed inclusions. This patient's current symptoms are most likely due to reactivation of a dormant infection in which of the following?

- A. Gall bladder (1%)
- ✓ B. Liver (87%)
- C. Lung (0%)
- D. Lymph nodes (0%)
- E. Red blood cells (7%)
- F. Spleen (2%)

Omitted
Correct answer
B

87%
Answered correctly

02 secs
Time Spent

04/09/2020
Last Updated

Explanation

Malaria life cycle

1
2
3
4
5
6
7
8
9
10
11
12
13
14
15
16
17
18
19
20
21
22
23
24
25
26
27
28
29
30
31

Malaria life cycle

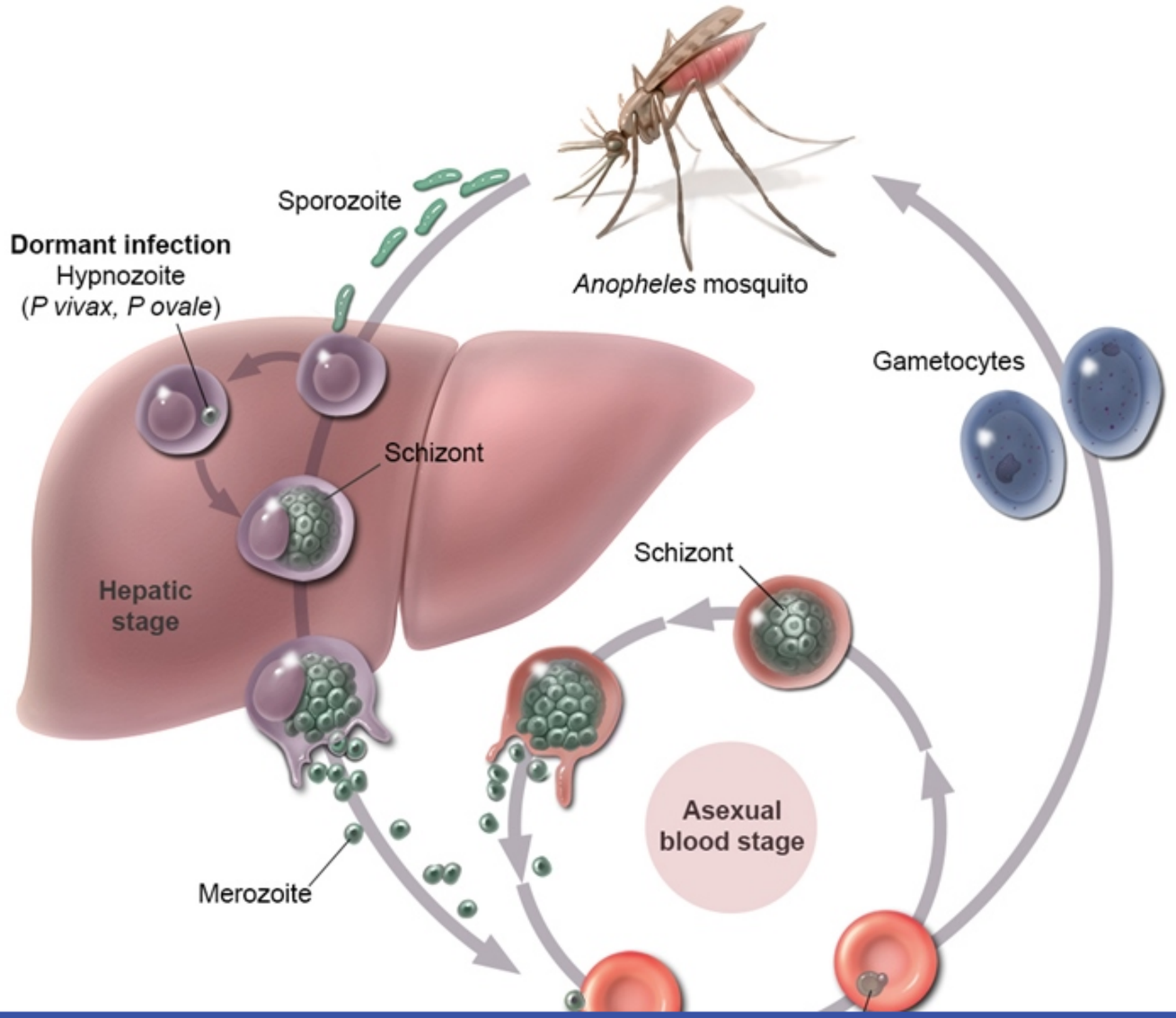

©UWorld

Red blood cell

Malaria is a mosquito-borne, protozoal infection caused by *Plasmodium* species. Transmission occurs when an infected female *Anopheles* mosquito injects *Plasmodium* sporozoites into subcutaneous capillaries during feeding. Within hours, sporozoites attach to and enter hepatocytes and undergo asexual reproduction. This results in the production of tens of thousands of daughter cells (merozoites) that eventually rupture the hepatocyte and spread to erythrocytes, where another asexual reproduction cycle occurs.

Manifestations of malaria arise due to erythrocyte rupture and include fever, flu-like symptoms (eg, myalgia, fatigue, headache, chills), anemia, and indirect bilirubinemia (hepatosplenomegaly is also common). The diagnosis is confirmed when trophozoites (intraerythrocytic, ringed inclusions) are seen on peripheral blood smear using Giemsa stain.

Although many different *Plasmodium* species cause malaria, the 2 dominant organisms are *P falciparum* (in Africa) and ***P vivax*** (in non-African countries). This patient who traveled to India was likely infected with *P vivax*. Unlike *P falciparum*, *P vivax* (and *P ovale*) sporozoites can undergo a **dormant hepatic phase** (hypnozoite stage) that may cause **recurrent parasitemia** and symptoms weeks or months after initial infection. Individuals with these strains of malaria must be treated with a combination of drugs that target both the erythrocyte phase (eg, chloroquine) and the dormant hepatic phase (ie, **primaquine**) to ensure clearance. Patients who are treated with a medication that only targets the erythrocyte phase (as was likely in this case) may initially improve but are likely to develop recurrent symptoms when the dormant hepatic hypnozoites reactivate.

(Choice A) *Salmonella typhi* can spread from the gastrointestinal tract to the gallbladder, which can lead to long-term gallbladder colonization. Typhoid fever is usually associated with a week of stepwise fever followed by a week of "rose spots" and abdominal pain and then possible complications such as abdominal bleeding/perforation and hepatosplenomegaly.

(Choice C) Tuberculosis most commonly reactivates from granulomas in the lung, but reactivation can also arise from latent foci in the liver, spleen, or kidneys (~15% of cases). Tuberculosis reactivation usually causes fever, weight loss, and pulmonary manifestations (eg, cough, dyspnea, cavitary disease).

(Choice D) Numerous infections can reactivate from the lymph nodes, including HIV, Epstein-Barr virus, and tuberculosis. These infections are not associated with intraerythrocytic, ringed organisms.

(Choice E) Malaria infects and lyses erythrocytes. However, dormant infection occurs in the liver.

Educational objective:

countries). This patient who traveled to India was likely infected with *P vivax*. Unlike *P falciparum*, *P vivax* (and *P ovale*) sporozoites can undergo a **dormant hepatic phase** (hypnozoite stage) that may cause **recurrent parasitemia** and symptoms weeks or months after initial infection. Individuals with these strains of malaria must be treated with a combination of drugs that target both the erythrocyte phase (eg, chloroquine) and the dormant hepatic phase (ie, **primaquine**) to ensure clearance. Patients who are treated with a medication that only targets the erythrocyte phase (as was likely in this case) may initially improve but are likely to develop recurrent symptoms when the dormant hepatic hypnozoites reactivate.

(Choice A) *Salmonella typhi* can spread from the gastrointestinal tract to the gallbladder, which can lead to long-term gallbladder colonization. Typhoid fever is usually associated with a week of stepwise fever followed by a week of "rose spots" and abdominal pain and then possible complications such as abdominal bleeding/perforation and hepatosplenomegaly.

(Choice C) Tuberculosis most commonly reactivates from granulomas in the lung, but reactivation can also arise from latent foci in the liver, spleen, or kidneys (~15% of cases). Tuberculosis reactivation usually causes fever, weight loss, and pulmonary manifestations (eg, cough, dyspnea, cavitary disease).

(Choice D) Numerous infections can reactivate from the lymph nodes, including HIV, Epstein-Barr virus, and tuberculosis. These infections are not associated with intraerythrocytic, ringed organisms.

(Choice E) Malaria infects and lyses erythrocytes. However, dormant infection occurs in the liver.

Educational objective:
Plasmodium vivax is the most common cause of malaria in non-African countries. It is transmitted by the female *Anopheles* mosquito and is associated with a latent liver phase that must be treated (with primaquine) independently of the erythrocytic phase to fully eliminate the organism.

References

- Malaria.

Microbiology	Infectious Diseases	Malaria
Subject	System	Topic

Copyright © UWorld. All rights reserved.

1
2
3
4
5
6
7
8
9
10
11
12
13
14
15
16
17
18
19
20
21
22
23
24
25
26
27
28
29
30
31

Exhibit Display

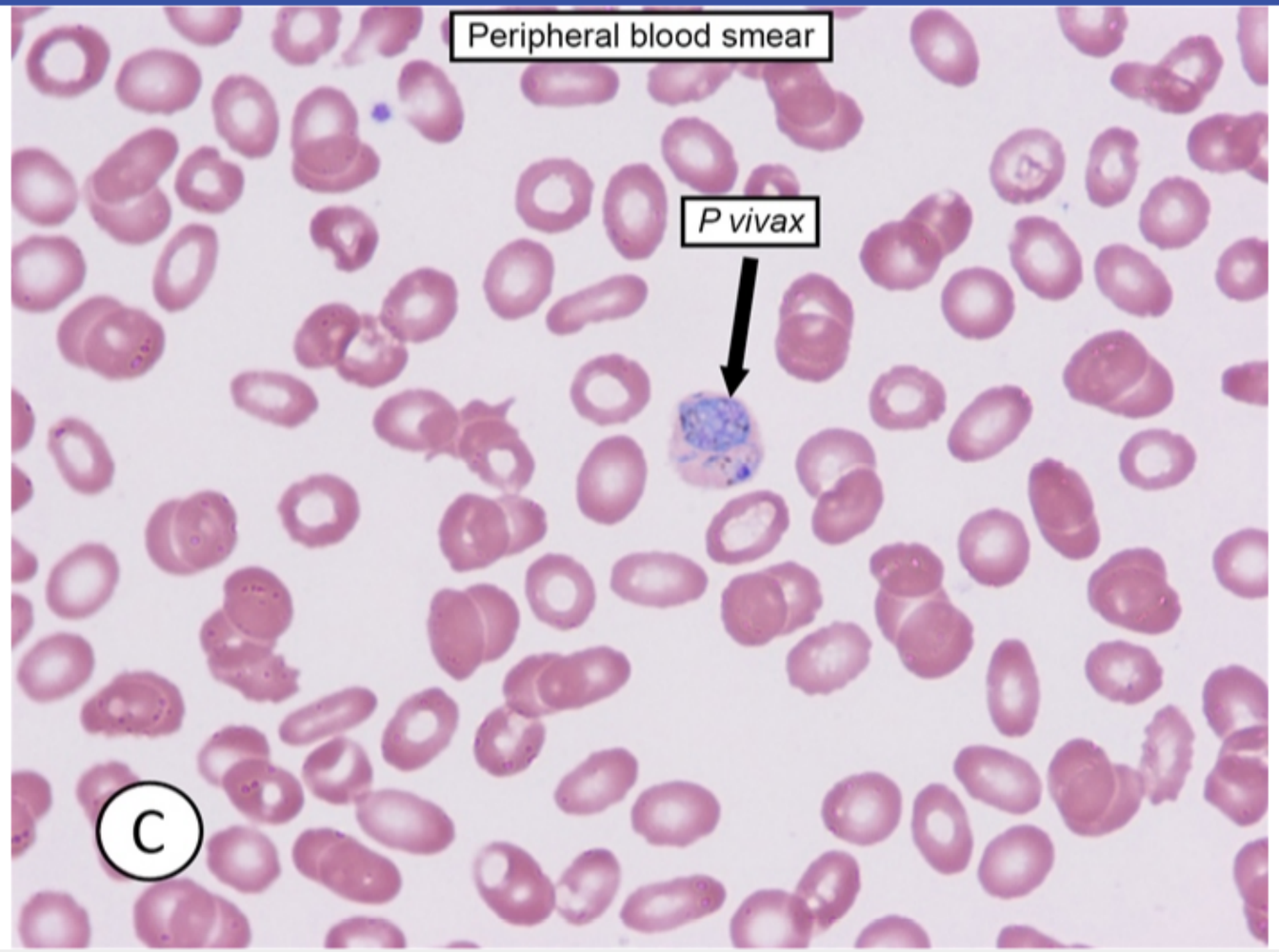

Zoom In | Zoom Out | Reset | Add To New Card | Existing Card

complications such as abdominal bleeding/perforation and hepatosplenomegaly

1
2
3
4
5
6
7
8
9
10
11
12
13
14
15
16
17
18
19
20
21
22
23
24
25
26
27
28
29
30
31

A 45-year-old man comes to the physician due to pain, swelling, and erythema affecting his right leg. He says that he suffered a minor cut to his leg a few days ago while cleaning his garage. Physical examination shows an indurated region surrounding a minor laceration that is draining a purulent exudate. He is diagnosed with cellulitis and started on the appropriate treatment. Gram stain of the exudate shows gram-positive cocci in clusters. The organism most likely responsible for this patient's infection synthesizes a protein as part of its peptidoglycan cell wall that does which of the following?

A. Activates complement

B. Binds the Fc portion of IgG

C. Causes hemolysis

D. Cleaves IgA

E. Interacts with MHC class II antigens

Submit

A 45-year-old man comes to the physician due to pain, swelling, and erythema affecting his right leg. He says that he suffered a minor cut to his leg a few days ago while cleaning his garage. Physical examination shows an indurated region surrounding a minor laceration that is draining a purulent exudate. He is diagnosed with cellulitis and started on the appropriate treatment. Gram stain of the exudate shows gram-positive cocci in clusters. The organism most likely responsible for this patient's infection synthesizes a protein as part of its peptidoglycan cell wall that does which of the following?

- A. Activates complement (8%)
- ✓ B. Binds the Fc portion of IgG (56%)
- C. Causes hemolysis (11%)
- D. Cleaves IgA (15%)
- E. Interacts with MHC class II antigens (8%)

Omitted
Correct answer
B

56%
Answered correctly

02 secs
Time Spent

06/11/2020
Last Updated

Explanation

Protein A

1
2
3
4
5
6
7
8
9
10
11
12
13
14
15
16
17
18
19
20
21
22
23
24
25
26
27
28
29
30
31

Protein A

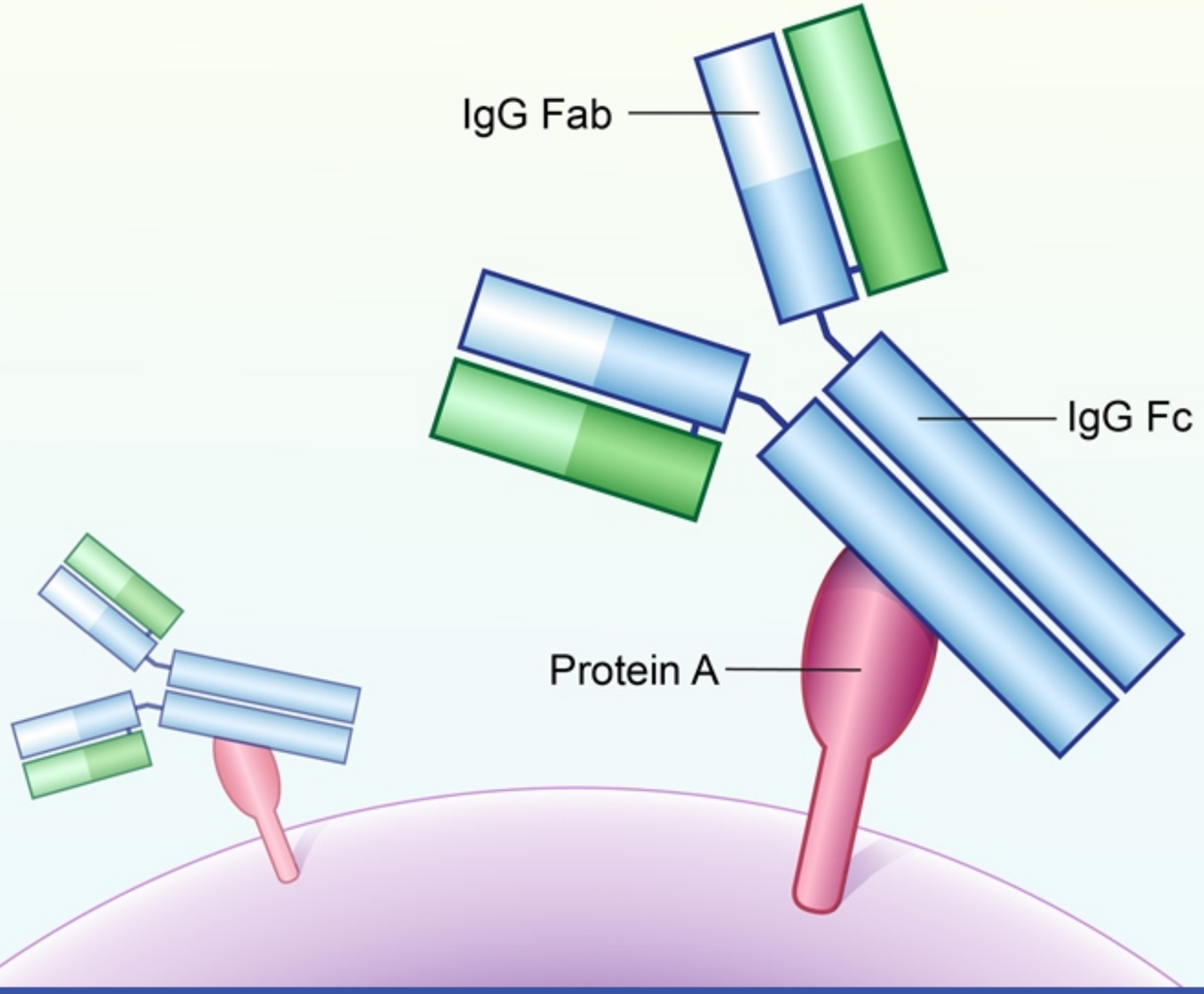

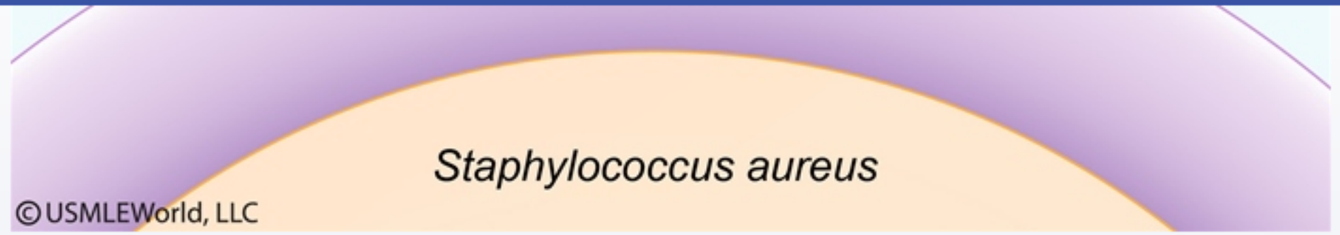

Clusters of gram-positive cocci on Gram stain is a characteristic finding of staphylococcal species such as *Staphylococcus aureus*. Protein A is a virulence factor that forms part of the outer peptidoglycan layer of *S aureus*. Protein A binds with the Fc portion of IgG antibodies at the complement-binding site, preventing complement activation **(Choice A)**. This results in decreased production of C3b, leading to impaired opsonization and phagocytosis.

(Choice C) Hemolysin is secreted by staphylococci and causes hemolysis as well as the destruction of neutrophils, macrophages, and platelets. It is a secreted factor that is not bound to the cell wall.

(Choice D) *Streptococcus pneumoniae* and *Neisseria gonorrhoeae* produce IgA proteases that cause cleavage of IgA antibodies, preventing them from interfering with bacterial adhesion to mucous membranes.

(Choice E) Major histocompatibility complex (MHC) class II (found on an antigen presenting cells) normally interacts with processed antigens, presenting them to T-lymphocytes to initiate an immune response. In contrast, superantigens (enterotoxins, toxic shock syndrome toxin) interact with MHC class II and the T-cell receptor outside of standard antigen binding sites to initiate widespread and nonspecific activation of T-lymphocytes. Although superantigens are synthesized by staphylococci, they are not bound to the peptidoglycan cell wall.

Educational objective:
Protein A is a virulence factor found in the peptidoglycan cell wall of *Staphylococcus aureus* that binds to the Fc portion of IgG, leading to impaired complement activation, opsonization, and phagocytosis.

Microbiology	Infectious Diseases	Skin and soft tissue infections
Subject	System	Topic

Copyright © UWorld. All rights reserved.

1
2
3
4
5
6
7
8
9
10
11
12
13
14
15
16
17
18
19
20
21
22
23
24
25
26
27
28
29
30
31

Researchers develop a novel drug to treat HIV infection. In an in vitro experiment, wild-type viral isolates are cultured with human CD4 T lymphocytes in the presence of the drug. Microscopic evaluation of these cells reveals no cytopathic changes, and no intracellular viral particles can be detected. Further analysis reveals that in the presence of the drug the virus attaches to the cellular membrane, but fusion of the viral and cell membranes does not occur. Which of the following is the most likely target of this medication?

A. Viral integrase enzyme

B. Viral *Nef* gene product

C. Viral *Tat* gene product

D. T-cell antigen receptor-CD3 complex

E. T-cell chemokine receptor

F. T-cell CTLA4 (CD152)

Submit

Researchers develop a novel drug to treat HIV infection. In an in vitro experiment, wild-type viral isolates are cultured with human CD4 T lymphocytes in the presence of the drug. Microscopic evaluation of these cells reveals no cytopathic changes, and no intracellular viral particles can be detected. Further analysis reveals that in the presence of the drug the virus attaches to the cellular membrane, but fusion of the viral and cell membranes does not occur. Which of the following is the most likely target of this medication?

- A. Viral integrase enzyme (13%)
- B. Viral *Nef* gene product (13%)
- C. Viral *Tat* gene product (6%)
- D. T-cell antigen receptor-CD3 complex (17%)
- ✓ E. T-cell chemokine receptor (24%)
- F. T-cell CTLA4 (CD152) (23%)

Omitted
Correct answer
E

24%
Answered correctly

03 secs
Time Spent

05/25/2020
Last Updated

Explanation

HIV attaches to host cells using the viral surface glycoprotein **gp120**. This glycoprotein **binds to the CD4** molecule as the primary receptor and the **chemokine receptor CCR5** (or CXCR4) as a coreceptor. Binding of the primary receptor and coreceptor induces a conformational change in gp120 that exposes the underlying transmembrane glycoprotein **gp41**, which **mediates viral fusion** to the host cell and release of the viral capsid into the cytoplasm.

1
2
3
4
5
6
7
8
9
10
11
12
13
14
15
16
17
18
19
20
21
22
23
24
25
26
27
28
29
30
31

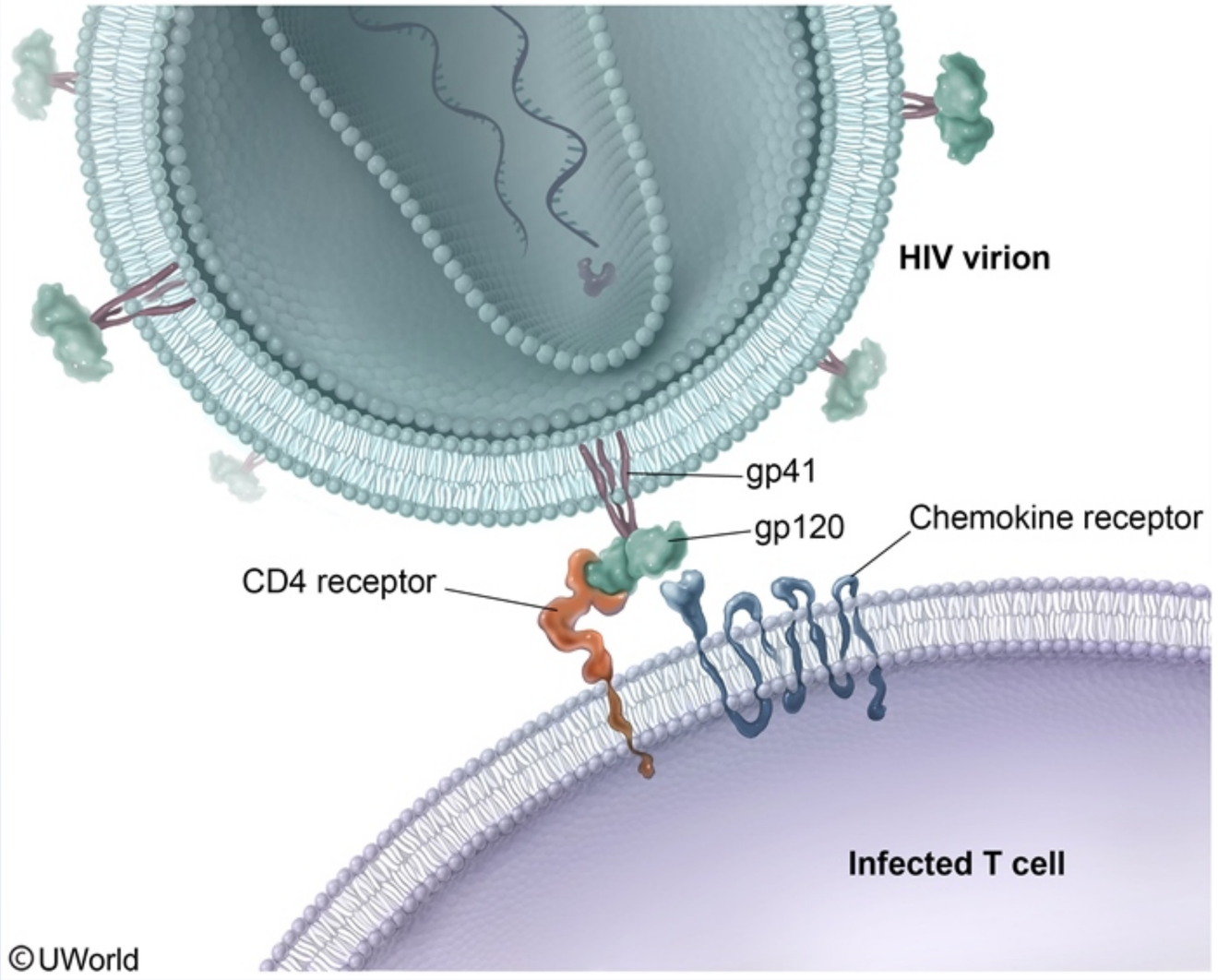

HIV attaches to host cells using the viral surface glycoprotein **gp120**. This glycoprotein **binds to the CD4** molecule as the primary receptor and the **chemokine receptor CCR5** (or CXCR4) as a coreceptor. Binding of the primary receptor and coreceptor induces a conformational change in

©UWorld

HIV attaches to host cells using the viral surface glycoprotein **gp120**. This glycoprotein **binds to the CD4** molecule as the primary receptor and the **chemokine receptor CCR5** (or CXCR4) as a coreceptor. Binding of the primary receptor and coreceptor induces a conformational change in gp120 that exposes the underlying transmembrane glycoprotein **gp41**, which **mediates viral fusion** to the host cell and release of the viral capsid into the cytoplasm.

The drug described in this case does not interfere with viral attachment but does interfere with viral fusion. This implies that gp120 is still able to bind to the primary CD4 receptor but may be blocked from binding to the chemokine coreceptor, which would prevent the conformational change to gp120 required for viral fusion. **Chemokine receptor antagonists** (eg, maraviroc) block this step in the HIV replication cycle. The drug described in this case could also be a fusion inhibitor (eg, enfuvirtide), which blocks gp41 from fusing the viral and host plasma membranes.

(Choices B and C) *Nef* and *tat* are HIV regulatory genes. The *nef* gene product downregulates the expression of class I major histocompatibility complex proteins on the surface of infected cells, which limits immune recognition by cytotoxic T cells. The *tat* gene product is a transcriptional activator that promotes viral gene expression.

(Choice A) HIV integrase is a viral enzyme that inserts the viral cDNA into the host cell chromosome.

(Choice D) The CD3 receptor is found on the surface of mature T lymphocytes. Monoclonal antibodies against CD3 are being investigated for autoimmune disorders, but this receptor does not play a role in HIV entry.

(Choice F) CTLA4 (CD-152) is a negative regulator of T-cell activation. Antagonists of CTLA4 are used as immune checkpoint inhibitors in cancer therapy (eg, melanoma).

Educational objective:
The chemokine receptor CCR5 is a coreceptor that enables the HIV virus to enter cells. Blockade of CCR5 by chemokine receptor antagonists prevents viral entry into host cells.

Microbiology	Infectious Diseases	HIV
Subject	System	Topic

Copyright © UWorld. All rights reserved.

©UWorld

HIV attaches to host cells
the **chemokine receptor**
gp120 that exposes the u
into the cytoplasm.

The drug described in this
bind to the primary CD4 re
to gp120 required for viral
described in this case cou

(Choices B and C) *Nef a*
complex proteins on the s
activator that promotes vir

(Choice A) HIV integrase

(Choice D) The CD3 rece
autoimmune disorders, bu

(Choice F) CTLA4 (CD-1
cancer therapy (eg, melan

Educational objective:
The chemokine receptor C
prevents viral entry into ho

Microbiology
Subject

Infectious Diseases
System

HIV
Topic

Exhibit Display

HIV regulatory & accessory proteins	
Tat	Promotes transcription of viral genes
Rev	Enhances export of unspliced viral transcripts from nucleus to cytoplasm
Nef	Downregulates host CD4 & MHC I proteins (inhibits immune recognition)
Vpu	Aids viral assembly & release
Vpr	Facilitates nuclear entry & inhibits host cell division
Vif	Increases infectivity & viral yield

MHC = major histocompatibility complex.

Add To New Card | Existing Card

1
2
3
4
5
6
7
8
9
10
11
12
13
14
15
16
17
18
19
20
21
22
23
24
25
26
27
28
29
30
31

A 5-week-old girl is brought to the emergency department due to several hours of fever, irritability, and vomiting. This morning she was warm to the touch and refused to drink. Her temperature is 40.1 C (104.2 F). Lumbar puncture reveals cerebrospinal fluid pleocytosis; additional fluid is sent for Gram stain and culture. Empiric cefotaxime and vancomycin therapy is initiated. However, no clinical improvement is seen. Cerebrospinal fluid culture yields an organism that is resistant to cefotaxime. Which of the following organisms is most likely causing this patient's infection?

A. *Haemophilus influenzae*

B. *Listeria monocytogenes*

C. *Neisseria meningitidis*

D. *Streptococcus agalactiae*

E. *Streptococcus pneumoniae*

Submit

1
2
3
4
5
6
7
8
9
10
11
12
13
14
15
16
17
18
19
20
21
22
23
24
25
26
27
28
29
30
31

A 5-week-old girl is brought to the emergency department due to several hours of fever, irritability, and vomiting. This morning she was warm to the touch and refused to drink. Her temperature is 40.1 C (104.2 F). Lumbar puncture reveals cerebrospinal fluid pleocytosis; additional fluid is sent for Gram stain and culture. Empiric cefotaxime and vancomycin therapy is initiated. However, no clinical improvement is seen. Cerebrospinal fluid culture yields an organism that is resistant to cefotaxime. Which of the following organisms is most likely causing this patient's infection?

A. *Haemophilus influenzae* (12%)
✓ B. *Listeria monocytogenes* (55%)
C. *Neisseria meningitidis* (8%)
D. *Streptococcus agalactiae* (18%)
E. *Streptococcus pneumoniae* (4%)

Omitted
Correct answer
B

55%
Answered correctly

04 secs
Time Spent

04/13/2020
Last Updated

Explanation

Cephalosporin-resistant organisms	
Organism	Reason

Cephalosporin-resistant organisms	
Organism	**Reason**
Listeria monocytogenes	Resistant penicillin-binding proteins
Methicillin-resistant *Staphylococcus*	
Enterococci	
Atypicals (eg *Mycoplasma*, *Chlamydia*)	No cell wall

©UWorld

This infant with high fever, irritability, vomiting, and cerebrospinal fluid pleocytosis has **meningitis**. Empiric treatment with cefotaxime and vancomycin would cover the majority of likely pathogens in this age group including *Streptococcus pneumoniae*, *Neisseria meningitidis*, *Haemophilus influenzae*, group B streptococcus, and *Escherichia coli*. However, it would not cover ***Listeria monocytogenes***, which has **intrinsic resistance** to third-generation **cephalosporins** (eg, cefotaxime, ceftriaxone) due to the presence of **penicillin-binding proteins** that have a **low-affinity** for this drug class. Coverage of *Listeria* requires the addition of **ampicillin**, a beta-lactam antibiotic with a specialized side-group that allows it to bind to and inactivate the penicillin binding proteins of *Listeria*.

(Choice A) Although many *Haemophilus influenzae* organisms produce beta lactamases, they are effectively treated with a beta lactam/beta lactamase inhibitor (eg, amoxicillin/clavulanate) or with third-generation cephalosporins.

(Choice C) *Neisseria meningitidis* is effectively treated with third-generation cephalosporins.

(Choice D) *Streptococcus agalactiae* (group B *Streptococcus*) is universally susceptible to ampicillin or penicillin as well as third-generation cephalosporins.

(Choice E) *Streptococcus pneumoniae* is the most common cause of meningitis in older infants and children. Although this organism has

©UWorld

This infant with high fever, irritability, vomiting, and cerebrospinal fluid pleocytosis has **meningitis**. Empiric treatment with cefotaxime and vancomycin would cover the majority of likely pathogens in this age group including *Streptococcus pneumoniae*, *Neisseria meningitidis*, *Haemophilus influenzae*, group B streptococcus, and *Escherichia coli*. However, it would not cover ***Listeria monocytogenes***, which has **intrinsic resistance** to third-generation **cephalosporins** (eg, cefotaxime, ceftriaxone) due to the presence of **penicillin-binding proteins** that have a **low-affinity** for this drug class. Coverage of *Listeria* requires the addition of **ampicillin**, a beta-lactam antibiotic with a specialized side-group that allows it to bind to and inactivate the penicillin binding proteins of *Listeria*.

(Choice A) Although many *Haemophilus influenzae* organisms produce beta lactamases, they are effectively treated with a beta lactam/beta lactamase inhibitor (eg, amoxicillin/clavulanate) or with third-generation cephalosporins.

(Choice C) *Neisseria meningitidis* is effectively treated with third-generation cephalosporins.

(Choice D) *Streptococcus agalactiae* (group B *Streptococcus*) is universally susceptible to ampicillin or penicillin as well as third-generation cephalosporins.

(Choice E) *Streptococcus pneumoniae* is the most common cause of meningitis in older infants and children. Although this organism has increasing penicillin and cephalosporin resistance, vancomycin provides effective coverage (and would result in symptomatic improvement).

Educational objective:
Ampicillin is the treatment of choice for *Listeria*, which is not sensitive to cephalosporins. *Listeria* most commonly causes disease in those with deficient cell-mediated immunity, such as young infants or immunocompromised patients.

References

- https://www.ncbi.nlm.nih.gov/pmc/articles/PMC172923/pdf/100345.pdf

Microbiology	Infectious Diseases	Meningitis
Subject	System	Topic

Copyright © UWorld. All rights reserved.

1
2
3
4
5
6
7
8
9
10
11
12
13
14
15
16
17
18
19
20
21
22
23
24
25
26
27
28
29
30
31

A 6-year-old boy whose family recently immigrated to the United States is brought to the office due to sore throat and fever. Examination shows mild tonsillar erythema with exudates. A sample from the exudates is obtained. On microscopic evaluation, there are clumped, gram-positive bacteria with polar granules that stain deeply with aniline dyes. Which of the following best explains the pathogenicity of the organism most likely responsible for this patient's condition?

A. Activation of electrolyte transport

B. Blockade of neurotransmitter release

C. Cellular membrane disruption

D. Impairment of protein synthesis

E. Widespread T cell activation

Submit

1
2
3
4
5
6
7
8
9
10
11
12
13
14
15
16
17
18
19
20
21
22
23
24
25
26
27
28
29
30
31

A 6-year-old boy whose family recently immigrated to the United States is brought to the office due to sore throat and fever. Examination shows mild tonsillar erythema with exudates. A sample from the exudates is obtained. On microscopic evaluation, there are clumped, gram-positive bacteria with polar granules that stain deeply with aniline dyes. Which of the following best explains the pathogenicity of the organism most likely responsible for this patient's condition?

- A. Activation of electrolyte transport (2%)
- B. Blockade of neurotransmitter release (2%)
- C. Cellular membrane disruption (19%)
- ✓ D. Impairment of protein synthesis (67%)
- E. Widespread T cell activation (9%)

Omitted
Correct answer
D

67%
Answered correctly

02 secs
Time Spent

03/01/2020
Last Updated

Explanation

Diphtheria	
Epidemiology	• Endemic in developing countries due to inadequate vaccination but rare in developed countries

Diphtheria	
Epidemiology	• Endemic in developing countries due to inadequate vaccination but rare in developed countries
Microbiology/ pathogenesis	• ***Corynebacterium diphtheriae*** colonize respiratory tract & secrete diphtheria toxin, the primary virulence factor • **Diphtheria toxin** is an AB exotoxin that inhibits protein synthesis by ADP-ribosylation of EF-2 • Toxin acts locally, causing respiratory cell necrosis with formation of fibrinous, coagulative exudates
Clinical symptoms	• Sore throat • Fever • Cervical adenopathy • Pharyngeal exudates/**coalescing pseudomembrane**

Complications	• Submucosal edema & pseudomembrane aspiration can obstruct respiratory tract, causing **suffocation**
	• Systemically absorbed diphtheria toxin has predilection for brain & heart tissue
	  ○ **Myocarditis/heart failure**
	  ○ **Neurologic toxicity**

EF-2 = elongation factor-2.

©UWorld

Corynebacterium diphtheriae are nonmotile, unencapsulated, gram-positive rods. On microscopic examination, they are often found in clumps (classically said to resemble Chinese characters) or joined in V- or Y-shaped chains. Their cytoplasm contains metachromatic **granules** that stain with **aniline** dyes (eg, methylene blue).

C diphtheriae produce classic 2-subunit **AB exotoxin**. The B (binding) subunit binds specifically to the heparin-binding epidermal growth factor receptor on cardiac and neural cells, which explains the toxin's affinity for heart and brain tissue. The B subunit induces endocytosis of the toxin, and the subsequently released A (active) subunit inhibits host cell protein synthesis by catalyzing the ADP-ribosylation of protein elongation factor 2 (EF-2). EF-2 is necessary for tRNA to insert new amino acids into the growing protein chain during translation. Therefore, the toxin causes cell death by inhibiting cell protein synthesis.

(Choice A) Certain virulent enteric bacteria (eg, *Campylobacter jejuni, Vibrio cholerae*) release AB exotoxins that activate electrolyte transport. These toxins have 5 B subunits responsible for cell binding and toxin endocytosis and 1 A subunit that stimulates a G protein to increase intracellular cAMP concentrations. As a result, active efflux of sodium and chloride ions occurs, and the subsequent cell water loss into the gut lumen leads to watery diarrhea and dehydration.

(Choice B) Botulinum toxin is a neurotoxin that blocks exocytosis of acetylcholine-containing presynaptic vesicles from peripheral nerve terminals, causing cranial and peripheral nerve palsies, muscle weakness, and respiratory paralysis. Tetanus toxin inhibits the release of the inhibitory neurotransmitters gamma-aminobutyric acid and glycine. Classic manifestations of tetanus include muscle spasms and autonomic hyperactivity.

(Choice C) *Clostridium perfringens* releases a cytolytic toxin (alpha-toxin, or phospholipase C) that degrades cell membrane phospholipids, causing cell destruction.

(Choice E) Superantigens (eg, staphylococcal and streptococcal toxic shock toxins) bind nonspecifically to T cell receptors and major histocompatibility complex class II molecules on antigen-presenting cells, leading to widespread T cell stimulation and inflammation. However, they are classically implicated in toxic shock syndrome related to tampon use or nasal packing, not upper respiratory infections.

Educational objective:
Diphtheria exotoxin inhibits host cell protein synthesis by catalyzing the ADP-ribosylation of host cell elongation factor-2.

Microbiology Infectious Diseases Diphtheria

C diphtheriae produce classic 2-subunit **AB exotoxin**. The B (binding) subunit binds specifically to the heparin-binding epidermal growth factor receptor on cardiac and neural cells, which explains the toxin's affinity for heart and brain tissue. The B subunit induces endocytosis of the toxin, and the subsequently released A (active) subunit inhibits host cell protein synthesis by catalyzing the ADP-ribosylation of protein elongation factor 2 (EF-2). EF-2 is necessary for tRNA to insert new amino acids into the growing protein chain during translation. Therefore, the toxin causes cell death by inhibiting cell protein synthesis.

(Choice A) Certain virulent enteric bacteria (eg, *Campylobacter jejuni, Vibrio cholerae*) release AB exotoxins that activate electrolyte transport. These toxins have 5 B subunits responsible for cell binding and toxin endocytosis and 1 A subunit that stimulates a G protein to increase intracellular cAMP concentrations. As a result, active efflux of sodium and chloride ions occurs, and the subsequent cell water loss into the gut lumen leads to watery diarrhea and dehydration.

(Choice B) Botulinum toxin is a neurotoxin that blocks exocytosis of acetylcholine-containing presynaptic vesicles from peripheral nerve terminals, causing cranial and peripheral nerve palsies, muscle weakness, and respiratory paralysis. Tetanus toxin inhibits the release of the inhibitory neurotransmitters gamma-aminobutyric acid and glycine. Classic manifestations of tetanus include muscle spasms and autonomic hyperactivity.

(Choice C) *Clostridium perfringens* releases a cytolytic toxin (alpha-toxin, or phospholipase C) that degrades cell membrane phospholipids, causing cell destruction.

(Choice E) Superantigens (eg, staphylococcal and streptococcal toxic shock toxins) bind nonspecifically to T cell receptors and major histocompatibility complex class II molecules on antigen-presenting cells, leading to widespread T cell stimulation and inflammation. However, they are classically implicated in toxic shock syndrome related to tampon use or nasal packing, not upper respiratory infections.

Educational objective:
Diphtheria exotoxin inhibits host cell protein synthesis by catalyzing the ADP-ribosylation of host cell elongation factor-2.

Microbiology	Infectious Diseases	Diphtheria
Subject	System	Topic

Copyright © UWorld. All rights reserved.

1
2
3
4
5
6
7
8
9
10
11
12
13
14
15
16
17
18
19
20
21
22
23
24
25
26
27
28
29
30
31

An outbreak of hepatitis in New Delhi was characterized by high incidence of fulminant hepatitis in pregnant women, who experienced a mortality rate of 20%. The virus responsible for the outbreak:

A. Is an unenveloped RNA virus

B. Is transmitted parenterally

C. Is associated with chronic hepatitis

D. Infects only HBsAg-positive individuals

E. Has oncogenic properties

Submit

An outbreak of hepatitis in New Delhi was characterized by high incidence of fulminant hepatitis in pregnant women, who experienced a mortality rate of 20%. The virus responsible for the outbreak:

- ✓ A. Is an unenveloped RNA virus (64%)
- B. Is transmitted parenterally (11%)
- C. Is associated with chronic hepatitis (6%)
- D. Infects only HBsAg-positive individuals (14%)
- E. Has oncogenic properties (3%)

Omitted
Correct answer
A

64%
Answered correctly

02 secs
Time Spent

02/03/2020
Last Updated

Explanation

Hepatitis E virus is an unenveloped, single-stranded RNA virus spread through the fecal-oral route. Infection with HEV occurs primarily in young and middle-aged adults living in Asia, sub-Saharan Africa, and Mexico, with an average incubation period of six weeks. While the virus is shed in the stool during the acute illness, the disease is typically self-limited and not associated with either chronic liver disease or a carrier state. HEV Ag or HEV RNA can be detected in the stool or liver in the earliest stages of infection (when the patient is asymptomatic). Later, serum transaminases and IgM anti-HEV titers rise in association with clinical illness. The most concerning feature of hepatitis E is the high mortality rate observed in infected pregnant women.

(Choice B) While hepatitis B, C, and D can be transmitted parenterally (with intravenous drug abusers and hemophiliacs are particularly high risk),

A

Answered correctly
Time Spent
Last Updated

Explanation

Hepatitis E virus is an unenveloped, single-stranded RNA virus spread through the fecal-oral route. Infection with HEV occurs primarily in young and middle-aged adults living in Asia, sub-Saharan Africa, and Mexico, with an average incubation period of six weeks. While the virus is shed in the stool during the acute illness, the disease is typically self-limited and not associated with either chronic liver disease or a carrier state. HEV Ag or HEV RNA can be detected in the stool or liver in the earliest stages of infection (when the patient is asymptomatic). Later, serum transaminases and IgM anti-HEV titers rise in association with clinical illness. The most concerning feature of hepatitis E is the high mortality rate observed in infected pregnant women.

(Choice B) While hepatitis B, C, and D can be transmitted parenterally (with intravenous drug abusers and hemophiliacs are particularly high risk), hepatitis A and E are primarily transmitted via the fecal-oral route.

(Choice C) Hepatitis E causes an acute illness and is not associated with chronic infection.

(Choice D) Unlike hepatitis D virus, hepatitis E is not dependent on HBsAg for infection and multiplication.

(Choice E) Because of their association with hepatocellular carcinoma, hepatitis B and C have been suggested to have oncogenic properties. Hepatitis E is not associated with an increased risk of hepatocellular carcinoma, however.

Educational Objective:
Hepatitis E virus is an unenveloped, single-stranded RNA virus spread through the fecal-oral route. The most concerning feature of hepatitis E infection is the high mortality rate observed in infected pregnant women.

Microbiology	Infectious Diseases	Hepatitis e
Subject	System	Topic

Copyright © UWorld. All rights reserved.

1
2
3
4
5
6
7
8
9
10
11
12
13
14
15
16
17
18
19
20
21
22
23
24
25
26
27
28
29
30
31

A 12-year-old boy is brought to the office with fever, chills, and a rash that appeared this morning. Two days earlier, the child started complaining of a sore throat. His temperature is 38.3 C (101 F). Examination shows a diffuse erythematous rash on his chest and abdomen that blanches with pressure, along with numerous 1- to 2-mm papules. The throat is erythematous with gray-white tonsillar exudates and the tongue is bright red. Which of the following complications is most likely to develop in this patient?

A. Aplastic anemia

B. Coronary artery aneurysm

C. Encephalitis

D. Orchitis

E. Rheumatic fever

Submit

A 12-year-old boy is brought to the office with fever, chills, and a rash that appeared this morning. Two days earlier, the child started complaining of a sore throat. His temperature is 38.3 C (101 F). Examination shows a diffuse erythematous rash on his chest and abdomen that blanches with pressure, along with numerous 1- to 2-mm papules. The throat is erythematous with gray-white tonsillar exudates and the tongue is bright red. Which of the following complications is most likely to develop in this patient?

- A. Aplastic anemia (2%)
- B. Coronary artery aneurysm (16%)
- C. Encephalitis (10%)
- D. Orchitis (6%)
- ✓ E. Rheumatic fever (63%)

Omitted
Correct answer
E

63%
Answered correctly

03 secs
Time Spent

04/07/2020
Last Updated

Explanation

This patient most likely has scarlet fever, which is caused by strains of **Group A streptococcus** that produce pyrogenic exotoxins. Scarlet fever is most often associated with streptococcal **pharyngitis**, which begins acutely after an incubation period of 1-5 days. Initial symptoms include fever, malaise, abdominal pain, and sore throat. The pharynx is typically erythematous, swollen, and possibly covered with gray-white exudates. In addition, the tongue can have inflamed red papillae with an appearance similar to that of a red strawberry.

After 1-2 days, a rash appears on the neck, armpits, and groin that subsequently generalizes to the rest of the body. The rash begins as scarlet spots or blotches, giving a boiled lobster appearance. As the rash progresses and becomes more widespread, it begins to resemble a sunburn

This patient most likely has scarlet fever, which is caused by strains of **Group A streptococcus** that produce pyrogenic exotoxins. Scarlet fever is most often associated with streptococcal **pharyngitis**, which begins acutely after an incubation period of 1-5 days. Initial symptoms include fever, malaise, abdominal pain, and sore throat. The pharynx is typically erythematous, swollen, and possibly covered with gray-white exudates. In addition, the tongue can have inflamed red papillae with an appearance similar to that of a red strawberry.

After 1-2 days, a rash appears on the neck, armpits, and groin that subsequently generalizes to the rest of the body. The rash begins as scarlet spots or blotches, giving a boiled lobster appearance. As the rash progresses and becomes more widespread, it begins to resemble a sunburn with goose pimples ("**sandpaper-like**" rash). The cheeks commonly appear flushed, giving the area around the mouth a pale appearance in comparison (circumoral pallor). Toward the end of the first week, desquamation begins and is most pronounced in the armpits, groin, and tips of the fingers and toes.

As with any streptococcal upper respiratory infection, scarlet fever can predispose to **acute rheumatic fever** and **glomerulonephritis**. Treatment with penicillin V can prevent the development of rheumatic fever, although its role in preventing glomerulonephritis is uncertain.

(Choice A) Aplastic anemia can complicate parvovirus B19 infection in patients with sickle cell anemia or immunocompromisation.

(Choice B) Coronary artery aneurysm is the most dreaded complication of Kawasaki disease, which can present with fever, strawberry tongue, and a rash. However, tonsillar exudates are more typical of bacterial disease, and this patient lacks other manifestations of Kawasaki disease (eg, bilateral conjunctival injection).

(Choice C) Measles virus infection is associated with a rash that classically starts on the face and Koplik spots (small whitish/blue lesions on buccal mucosa). Neurological complications can include encephalitis (acutely), acute disseminated encephalomyelitis (during recovery), and subacute sclerosing panencephalitis (years later).

(Choice D) Orchitis is one of the most common complications of mumps. Mumps characteristically presents with fever, malaise, headaches, and myalgias followed by the development of parotitis within 48 hours.

Educational objective:
Scarlet fever is characterized by fever, pharyngitis, sandpaper-like rash, circumoral pallor, and a strawberry tongue. It is caused by strains of Group A streptococcus that produce pyrogenic exotoxins. Scarlet fever can predispose to acute rheumatic fever and glomerulonephritis.

1
2
3
4
5
6
7
8
9
10
11
12
13
14
15
16
17
18
19
20
21
22
23
24
25
26
27
28
29
30
31

Explanation

This patient most likely ha ... er
is most often associated w
fever, malaise, abdominal ... s.
In addition, the tongue car

After 1-2 days, a rash app ... et
spots or blotches, giving a ... h
with goose pimples ("sand
comparison (circumoral pa ... of
the fingers and toes.

As with any streptococcal ... nent
with penicillin V can preve

(Choice A) Aplastic anen

(Choice B) Coronary arte ... e,
and a rash. However, ton ... (eg,
bilateral conjunctival injec

(Choice C) Measles virus
buccal mucosa). Neurolo
subacute sclerosing pane

(Choice D) Orchitis is on ... and
myalgias followed by the c

Educational objective:
Scarlet fever is characterized by fever, pharyngitis, sandpaper-like rash, circumoral pallor, and a strawberry tongue. It is caused by strains of Group A streptococcus that produce pyrogenic exotoxins. Scarlet fever can predispose to acute rheumatic fever and glomerulonephritis.

Exhibit Display

Erythematous childhood rashes

Disease	Agent	Clinical presentation	Important complications
Chickenpox	Varicella-zoster virus	• **Pruritic, vesicular rash** on face, trunk & extremities • Lesions in different stages of development	Shingles (in adulthood)
Erythema infectiosum	Parvovirus B19	• Malar rash with "slapped cheek" appearance	Aplastic crisis in sickle cell and immunocompromised patients
German measles (rubella)	Rubella virus	• Maculopapular rash starting on head, progressing to trunk & extremities • **Occipital and postauricular lymphadenopathy**	Congenital rubella syndrome
Measles (rubeola)	Measles virus	• Maculopapular rash starting on head that progresses to trunk & extremities • Rash preceded by cough, coryza, conjunctivitis & **Koplik spots** (pathognomonic)	Bronchopneumonia, encephalitis
Roseola infantum	HHV 6	• High fever for 3-5 days with **rash appearing once fever subsides** • Macules & papules initially on trunk that spread to extremities	Self-limited
Scarlet fever	*Streptococcus pyogenes*	• **Sandpaper-like rash** that begins on the neck & upper trunk & then generalizes • Associated with fever & sore throat	Rheumatic fever, glomerulonephritis

©UWorld

Zoom In | Zoom Out | Reset | Add To New Card | Existing Card

Explanation

This patient most likely ha ... er
is most often associated w ...
fever, malaise, abdominal ... s.
In addition, the tongue car ...

After 1-2 days, a rash app ... et
spots or blotches, giving a ... n
with goose pimples ("**sand** ...
comparison (circumoral pa ... of
the fingers and toes.

As with any streptococcal ... ment
with penicillin V can preve ...

(Choice A) Aplastic anem ...

(Choice B) Coronary arte ... e,
and a rash. However, ton ... (eg,
bilateral conjunctival injec ...

(Choice C) Measles virus ...
buccal mucosa). Neurolo ...
subacute sclerosing panen ...

(Choice D) Orchitis is on ... and
myalgias followed by the c ...

Educational objective:
Scarlet fever is characterized by fever, pharyngitis, sandpaper-like rash, circumoral pallor, and a strawberry tongue. It is caused by strains of Group A streptococcus that produce pyrogenic exotoxins. Scarlet fever can predispose to acute rheumatic fever and glomerulonephritis.

Exhibit Display

Disease	Agent	Clinical presentation	Important complications
Chickenpox	Varicella-zoster virus	• **Pruritic, vesicular rash** on face, trunk & extremities • Lesions in different stages of development	Shingles (in adulthood)
Erythema infectiosum	Parvovirus B19	• Malar rash with "slapped cheek" appearance	Aplastic crisis in sickle cell and immunocompromised patients
German measles (rubella)	Rubella virus	• Maculopapular rash starting on head, progressing to trunk & extremities • **Occipital and postauricular lymphadenopathy**	Congenital rubella syndrome
Measles (rubeola)	Measles virus	• Maculopapular rash starting on head that progresses to trunk & extremities • Rash preceded by cough, coryza, conjunctivitis & **Koplik spots** (pathognomonic)	Bronchopneumonia, encephalitis
Roseola infantum	HHV 6	• High fever for 3-5 days with **rash appearing once fever subsides** • Macules & papules initially on trunk that spread to extremities	Self-limited
Scarlet fever	*Streptococcus pyogenes*	• **Sandpaper-like rash** that begins on the neck & upper trunk & then generalizes • Associated with fever	Rheumatic fever, glomerulonephritis

Zoom In | Zoom Out | Reset | Add To New Card | Existing Card

Explanation

This patient most likely ha ... er
is most often associated w
fever, malaise, abdominal ... s.
In addition, the tongue car

After 1-2 days, a rash app ... et
spots or blotches, giving a ... n
with goose pimples ("sand
comparison (circumoral pa ... of
the fingers and toes.

As with any streptococcal ... nent
with penicillin V can preve

(Choice A) Aplastic anem

(Choice B) Coronary arte ... e,
and a rash. However, ton ... (eg,
bilateral conjunctival injec

(Choice C) Measles virus
buccal mucosa). Neurolo
subacute sclerosing pane

(Choice D) Orchitis is on ... and
myalgias followed by the c

Educational objective:

Exhibit Display

Disease	Agent	Clinical presentation	Important complications
Chickenpox	Varicella-zoster virus	• **Pruritic, vesicular rash** on face, trunk & extremities • Lesions in different stages of development	Shingles (in adulthood)
Erythema infectiosum	Parvovirus B19	• Malar rash with "slapped cheek" appearance	Aplastic crisis in sickle cell and immunocompromised patients
German measles (rubella)	Rubella virus	• Maculopapular rash starting on head, progressing to trunk & extremities • **Occipital and postauricular lymphadenopathy**	Congenital rubella syndrome
Measles (rubeola)	Measles virus	• Maculopapular rash starting on head that progresses to trunk & extremities • Rash preceded by cough, coryza, conjunctivitis & **Koplik spots** (pathognomonic)	Bronchopneumonia, encephalitis
Roseola infantum	HHV 6	• High fever for 3-5 days with **rash appearing once fever subsides** • Macules & papules	Self-limited

Zoom In | Zoom Out | Reset | Add To New Card | Existing Card

This patient most likely ha ... er
is most often associated w
fever, malaise, abdominal ... s.
In addition, the tongue car

After 1-2 days, a rash app ... et
spots or blotches, giving a ... n
with goose pimples ("**sand**
comparison (circumoral pa ... of
the fingers and toes.

As with any streptococcal ... nent
with penicillin V can preve

(Choice A) Aplastic anem

(Choice B) Coronary arte ... e,
and a rash. However, ton ... (eg,
bilateral conjunctival injec

(Choice C) Measles virus
buccal mucosa). Neurolog
subacute sclerosing panen

(Choice D) Orchitis is on ... and
myalgias followed by the c

Educational objective:
Scarlet fever is characterized by fever, pharyngitis, sandpaper-like rash, circumoral pallor, and a strawberry tongue. It is caused by strains of Group A streptococcus that produce pyrogenic exotoxins. Scarlet fever can predispose to acute rheumatic fever and glomerulonephritis.

Exhibit Display

infectiosum	Parvovirus B19	"slapped cheek" appearance	immunocompromised patients
German measles (rubella)	Rubella virus	• Maculopapular rash starting on head, progressing to trunk & extremities • **Occipital and postauricular lymphadenopathy**	Congenital rubella syndrome
Measles (rubeola)	Measles virus	• Maculopapular rash starting on head that progresses to trunk & extremities • Rash preceded by cough, coryza, conjunctivitis & **Koplik spots** (pathognomonic)	Bronchopneumonia, encephalitis
Roseola infantum	HHV 6	• High fever for 3-5 days with **rash appearing once fever subsides** • Macules & papules initially on trunk that spread to extremities	Self-limited
Scarlet fever	*Streptococcus pyogenes*	• **Sandpaper-like rash** that begins on the neck & upper trunk & then generalizes • Associated with fever & sore throat	Rheumatic fever, glomerulonephritis

©UWorld

Zoom In | Zoom Out | Reset | Add To New Card | Existing Card

1
2
3
4
5
6
7
8
9
10
11
12
13
14
15
16
17
18
19
20
21
22
23
24
25
26
27
28
29
30
31

Explanation

Exhibit Display

Zoom In | Zoom Out | Reset | Add To New Card | Existing Card

1
2
3
4
5
6
7
8
9
10
11
12
13
14
15
16
17
18
19
20
21
22
23
24
25
26
27
28
29
30
31

Explanation

Exhibit Display

Scarlet fever sandpaper-like rash

Zoom In Zoom Out Reset Add To New Card | Existing Card

1
2
3
4
5
6
7
8
9
10
11
12
13
14
15
16
17
18
19
20
21
22
23
24
25
26
27
28
29
30
31

Explanation

Exhibit Display

Scarlet fever sandpaper-like rash

Zoom In Zoom Out Reset Add To New Card | Existing Card

1
2
3
4
5
6
7
8
9
10
11
12
13
14
15
16
17
18
19
20
21
22
23
24
25
26
27
28
29
30
31

Explanation

Exhibit Display

Zoom In | Zoom Out | Reset | Add To New Card | Existing Card

After 1-2 days, a rash appears on the neck, armpits, and groin that subsequently generalizes to the rest of the body. The rash begins as scarlet spots or blotches, giving a boiled lobster appearance. As the rash progresses and becomes more widespread, it begins to resemble a sunburn with goose pimples ("**sandpaper-like**" rash). The cheeks commonly appear flushed, giving the area around the mouth a pale appearance in comparison (circumoral pallor). Toward the end of the first week, desquamation begins and is most pronounced in the armpits, groin, and tips of the fingers and toes.

As with any streptococcal upper respiratory infection, scarlet fever can predispose to **acute rheumatic fever** and **glomerulonephritis**. Treatment with penicillin V can prevent the development of rheumatic fever, although its role in preventing glomerulonephritis is uncertain.

(Choice A) Aplastic anemia can complicate parvovirus B19 infection in patients with sickle cell anemia or immunocompromisation.

(Choice B) Coronary artery aneurysm is the most dreaded complication of Kawasaki disease, which can present with fever, strawberry tongue, and a rash. However, tonsillar exudates are more typical of bacterial disease, and this patient lacks other manifestations of Kawasaki disease (eg, bilateral conjunctival injection).

(Choice C) Measles virus infection is associated with a rash that classically starts on the face and Koplik spots (small whitish/blue lesions on buccal mucosa). Neurological complications can include encephalitis (acutely), acute disseminated encephalomyelitis (during recovery), and subacute sclerosing panencephalitis (years later).

(Choice D) Orchitis is one of the most common complications of mumps. Mumps characteristically presents with fever, malaise, headaches, and myalgias followed by the development of parotitis within 48 hours.

Educational objective:
Scarlet fever is characterized by fever, pharyngitis, sandpaper-like rash, circumoral pallor, and a strawberry tongue. It is caused by strains of Group A streptococcus that produce pyrogenic exotoxins. Scarlet fever can predispose to acute rheumatic fever and glomerulonephritis.

Microbiology	Infectious Diseases	Scarlet fever
Subject	System	Topic

Copyright © UWorld. All rights reserved.

1
2
3
4
5
6
7
8
9
10
11
12
13
14
15
16
17
18
19
20
21
22
23
24
25
26
27
28
29
30
31

A 4-year-old boy is brought to the physician by his mother with decreased appetite, abdominal cramps, and diarrhea over the last 3 days. The stools were initially watery but have now become bloody. On physical examination, his temperature is 100.4 F (38 C). There are signs of dehydration and he has a mildly distended abdomen with diffuse pain elicited on palpation. Stool studies are positive for fecal leukocytes and occult blood. Fecal cultures grow non-lactose fermenting, gram-negative rods on MacConkey agar. The bacteria ferment glucose without gas production, do not generate hydrogen sulfide when grown on triple sugar iron agar, and cannot replicate at refrigeration temperatures. Which of the following bacterial factors is the most important during the pathogenesis of this patient's disease?

A. Exotoxin production

B. Intestinal colonization

C. Mucosal invasion

D. Proliferation in lymph nodes

E. Survival in the circulation

Submit

A 4-year-old boy is brought to the physician by his mother with decreased appetite, abdominal cramps, and diarrhea over the last 3 days. The stools were initially watery but have now become bloody. On physical examination, his temperature is 100.4 F (38 C). There are signs of dehydration and he has a mildly distended abdomen with diffuse pain elicited on palpation. Stool studies are positive for fecal leukocytes and occult blood. Fecal cultures grow non-lactose fermenting, gram-negative rods on MacConkey agar. The bacteria ferment glucose without gas production, do not generate hydrogen sulfide when grown on triple sugar iron agar, and cannot replicate at refrigeration temperatures. Which of the following bacterial factors is the most important during the pathogenesis of this patient's disease?

- A. Exotoxin production (31%)
- B. Intestinal colonization (8%)
- ✓ C. Mucosal invasion (55%)
- D. Proliferation in lymph nodes (2%)
- E. Survival in the circulation (1%)

Omitted
Correct answer
C

55%
Answered correctly

04 secs
Time Spent

03/27/2020
Last Updated

Explanation

Characteristics of gram-negative bacteria

Gram-negative rods

1
2
3
4
5
6
7
8
9
10
11
12
13
14
15
16
17
18
19
20
21
22
23
24
25
26
27
28
29
30
31

Characteristics of gram-negative bacteria

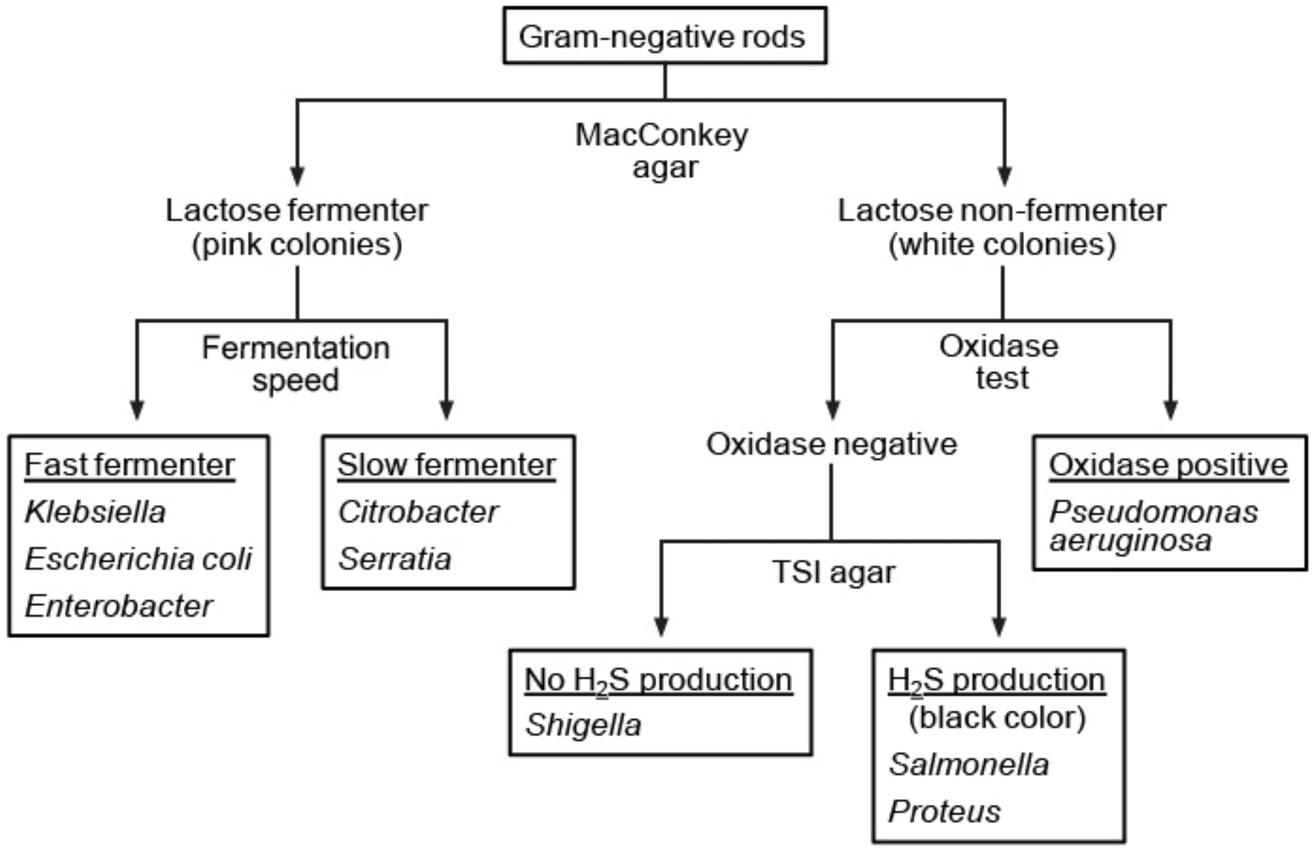

©UWorld

This patient's fever, abdominal cramps, and bloody diarrhea (**dysentery**) are consistent with bacterial enteritis. His stool culture results are most specific for a *Shigella* species (*Shigella sonnei* being most common in the United States). ***Shigella*** is transmitted via the fecal-oral route and is never a component of the normal bacterial gut flora. Shigellosis is primarily a pediatric disease but also shows a predilection for men who have sex with men and adults in skilled nursing facilities. *Shigella* species are non-lactose fermenting organisms that produce acid (not gas) during glucose fermentation (in contrast to *Escherichia coli*). Furthermore, *Shigella* species are non-motile and do not produce H_2S (in contrast to

This patient's fever, abdominal cramps, and bloody diarrhea (**dysentery**) are consistent with bacterial enteritis. His stool culture results are most specific for a *Shigella* species (*Shigella sonnei* being most common in the United States). ***Shigella*** is transmitted via the fecal-oral route and is never a component of the normal bacterial gut flora. Shigellosis is primarily a pediatric disease but also shows a predilection for men who have sex with men and adults in skilled nursing facilities. *Shigella* species are non-lactose fermenting organisms that produce acid (not gas) during glucose fermentation (in contrast to *Escherichia coli*). Furthermore, *Shigella* species are non-motile and do not produce H_2S (in contrast to *Salmonella*).

Mucosal invasion is the essential pathogenic mechanism for *Shigella* infection. *Shigella* invades the gastrointestinal mucosa, particularly via the M cells that overlie Peyer's patches. After cell entry, *Shigella* is able to lyse its containment vacuole and enter the cytosolic compartment. It then can induce apoptosis of the host cell and spread to adjacent cells via protrusions created through host-cell **actin polymerization**. *Shigella* invasion triggers a robust host inflammatory response that is largely mediated by neutrophils.

(Choice A) Some strains of *Shigella* produce shiga toxin, which damages the intestinal mucosa by inactivating the 60S ribosomal subunit, halting cellular protein synthesis. However, shiga toxin plays a minor, nonessential role in the disease process, as nontoxigenic strains also cause shigellosis.

(Choice B) Intestinal colonization with *Shigella* does not occur as the bacterium is highly pathogenic; transmission of as few as 10-100 organisms is sufficient to cause disease. If *Shigella* is isolated from a stool culture, an active infection is taking place.

(Choice D) Proliferation in lymph nodes is not a characteristic of *Shigella*. In contrast, both *Salmonella typhi* and *Yersinia enterocolitica* (grows at low temperatures like *Listeria*) can gain access to the lymphatics and proliferate in the mesenteric lymph nodes. *Y enterocolitica* can cause inflammation and enlargement of the lymphoid tissue around the appendix and terminal ileum ("pseudoappendicitis"), leading to right lower quadrant pain that can be confused with acute appendicitis.

(Choice E) *Shigella* infections rarely cause bacteremia, as the bacterium is readily phagocytosed and destroyed after entering the bloodstream. Enteric bacteremia is more likely to be caused by *E coli, S typhi* (typhoid fever), *Klebsiella*, and *Proteus*.

Educational objective:
Shigella is a non-motile, non-lactose fermenting organism that does not produce H_2S when grown on triple sugar iron agar. Mucosal invasion of the M cells that overlie Peyer's patches is an essential pathogenic mechanism for *Shigella* infection. *Shigella* then escapes the phagosome and spreads laterally to other epithelial cells via actin polymerization.

M cells that overlie Peyer's patches. After cell entry, *Shigella* is able to lyse its containment vacuole and enter the cytosolic compartment. It then can induce apoptosis of the host cell and spread to adjacent cells via protrusions created through host-cell **actin polymerization**. *Shigella* invasion triggers a robust host inflammatory response that is largely mediated by neutrophils.

(Choice A) Some strains of *Shigella* produce shiga toxin, which damages the intestinal mucosa by inactivating the 60S ribosomal subunit, halting cellular protein synthesis. However, shiga toxin plays a minor, nonessential role in the disease process, as nontoxigenic strains also cause shigellosis.

(Choice B) Intestinal colonization with *Shigella* does not occur as the bacterium is highly pathogenic; transmission of as few as 10-100 organisms is sufficient to cause disease. If *Shigella* is isolated from a stool culture, an active infection is taking place.

(Choice D) Proliferation in lymph nodes is not a characteristic of *Shigella*. In contrast, both *Salmonella typhi* and *Yersinia enterocolitica* (grows at low temperatures like *Listeria*) can gain access to the lymphatics and proliferate in the mesenteric lymph nodes. *Y enterocolitica* can cause inflammation and enlargement of the lymphoid tissue around the appendix and terminal ileum ("pseudoappendicitis"), leading to right lower quadrant pain that can be confused with acute appendicitis.

(Choice E) *Shigella* infections rarely cause bacteremia, as the bacterium is readily phagocytosed and destroyed after entering the bloodstream. Enteric bacteremia is more likely to be caused by *E coli, S typhi* (typhoid fever), *Klebsiella*, and *Proteus*.

Educational objective:
Shigella is a non-motile, non-lactose fermenting organism that does not produce H_2S when grown on triple sugar iron agar. Mucosal invasion of the M cells that overlie Peyer's patches is an essential pathogenic mechanism for *Shigella* infection. *Shigella* then escapes the phagosome and spreads laterally to other epithelial cells via actin polymerization.

References

- Shigellosis

Microbiology	Infectious Diseases	Acute diarrhea
Subject	System	Topic

Copyright © UWorld. All rights reserved.

1
2
3
4
5
6
7
8
9
10
11
12
13
14
15
16
17
18
19
20
21
22
23
24
25
26
27
28
29
30
31

A 22-year-old woman comes to the office due to worsening cough. The patient has been coughing every day for the past several months, but over the last 4 weeks, the cough has worsened, with increased amounts of thick sputum and shortness of breath. Streaks of blood have been present in the sputum on several occasions. The patient also has a history of chronic sinusitis and repeated hospitalizations for airway infections. She takes pancreatic enzyme supplements for chronic diarrhea. She does not use tobacco, alcohol, or illicit drugs. Physical examination reveals nasal polyps, a barrel-shaped chest, bilateral coarse lung crackles, and digital clubbing. Chest x-ray shows hyperinflated lungs and dilated, thickened airways. Sputum culture from this patient is most likely to yield which of the following organisms?

A. *Aspergillus fumigatus*

B. *Moraxella catarrhalis*

C. *Mycobacterium tuberculosis*

D. *Pseudomonas aeruginosa*

E. *Streptococcus pneumoniae*

Submit

A 22-year-old woman comes to the office due to worsening cough. The patient has been coughing every day for the past several months, but over the last 4 weeks, the cough has worsened, with increased amounts of thick sputum and shortness of breath. Streaks of blood have been present in the sputum on several occasions. The patient also has a history of chronic sinusitis and repeated hospitalizations for airway infections. She takes pancreatic enzyme supplements for chronic diarrhea. She does not use tobacco, alcohol, or illicit drugs. Physical examination reveals nasal polyps, a barrel-shaped chest, bilateral coarse lung crackles, and digital clubbing. Chest x-ray shows hyperinflated lungs and dilated, thickened airways. Sputum culture from this patient is most likely to yield which of the following organisms?

A. *Aspergillus fumigatus* (9%)
B. *Moraxella catarrhalis* (6%)
C. *Mycobacterium tuberculosis* (3%)
✓ D. *Pseudomonas aeruginosa* (68%)
E. *Streptococcus pneumoniae* (11%)

Omitted
Correct answer
D

68%
Answered correctly

03 secs
Time Spent

02/23/2020
Last Updated

Explanation

Cystic fibrosis (CF) is a progressive, fatal illness characterized by the development of thick, viscous, clogging secretions in a multitude of organs. Young adults with CF typically have several manifestations of the disorder, including pancreatic insufficiency (eg, diarrhea), chronic sinusitis, nasal polyps, and chronic bronchitis (eg, long-standing productive cough, hyperinflated lungs, barrel chest). However, **persistent lower respiratory tract infection** is the major source of morbidity and death.

Cystic fibrosis (CF) is a progressive, fatal illness characterized by the development of thick, viscous, clogging secretions in a multitude of organs. Young adults with CF typically have several manifestations of the disorder, including pancreatic insufficiency (eg, diarrhea), chronic sinusitis, nasal polyps, and chronic bronchitis (eg, long-standing productive cough, hyperinflated lungs, barrel chest). However, **persistent lower respiratory tract infection** is the major source of morbidity and death.

Early in the course of the disease, thick airway secretions obstruct mucociliary clearance and lead to the colonization of the lower respiratory tract with pathogenic bacteria. Although *Haemophilus influenzae* and *Staphylococcus aureus* are seen in children with CF, ***Pseudomonas aeruginosa*** is the major pathogen in **adults**. This organism forms a biofilm and switches to a mucoid phenotype to prevent its full elimination (even with antibiotics). Neutrophils respond by releasing elastase, myeloperoxidase, and reactive oxygen species, but these compounds are insufficient to clear the infection and progressively destroy the walls of the airway, leading to **bronchiectasis** and respiratory decline.

(Choice A) Allergic bronchopulmonary aspergillosis (ABPA) is a hypersensitivity reaction to *Aspergillus fumigatus* that primarily manifests with asthma-like symptoms. Although ABPA can occur in patients with CF, it is far less common than *Pseudomonas* lower respiratory infections.

(Choice B) *Moraxella catarrhalis* is an upper respiratory pathogen that frequently causes otitis media, sinusitis, bronchitis, and laryngitis. Although this organism is a common cause of exacerbations of chronic obstructive pulmonary disease, it is not a frequent colonizer of patients with CF.

(Choice C) *Mycobacterium tuberculosis* infections can cause coughing for several weeks or months and, occasionally, hemoptysis. However, thick sputum production is uncommon. In addition, chest x-ray typically reveals cavitary lesions in the upper lobes.

(Choice E) *Streptococcus pneumoniae* is the leading cause of community-acquired pneumonia and a frequent underlying pathogen in sinusitis, bronchitis, and otitis media. It is not a typical cause of persistent infection in patients with CF.

Educational objective:
In patients with cystic fibrosis, pathogenic bacteria colonize the respiratory tract early in the disease course. The leading pathogen in adults is *Pseudomonas aeruginosa*, which forms a thick biofilm to prevent its full elimination from the body.

Microbiology	Infectious Diseases	Cystic fibrosis
Subject	System	Topic

1
2
3
4
5
6
7
8
9
10
11
12
13
14
15
16
17
18
19
20
21
22
23
24
25
26
27
28
29
30
31

Exhibit Display

Cystic fibrosis pathogenesis

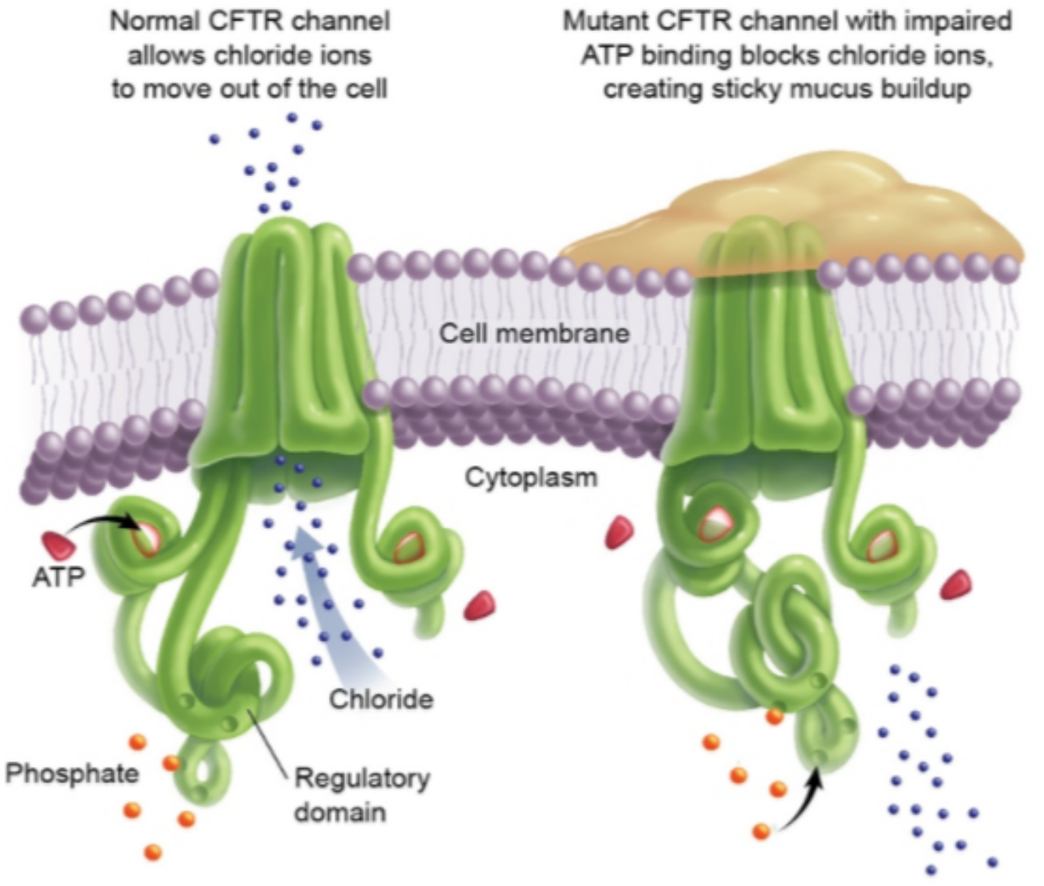

CFTR = cystic fibrosis transmembrane conductance regulator.

©UWorld

Zoom In | Zoom Out | Reset | Add To New Card | Existing Card

Subject System Topic

1
2
3
4
5
6
7
8
9
10
11
12
13
14
15
16
17
18
19
20
21
22
23
24
25
26
27
28
29
30
31

Exhibit Display

Cystic fibrosis features

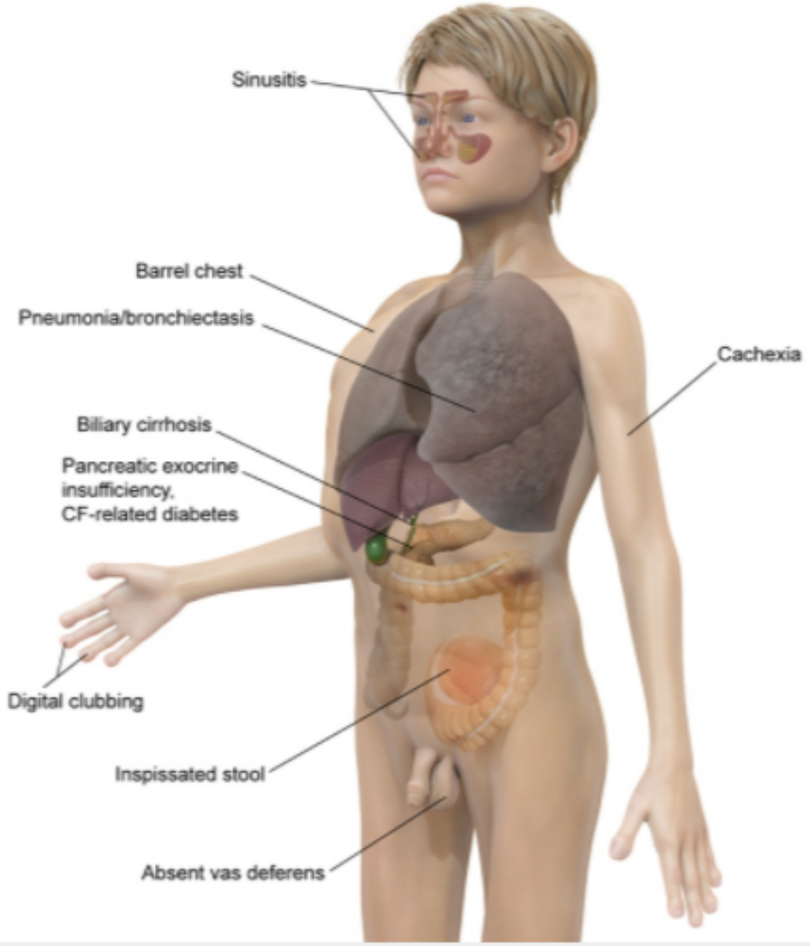

Zoom In | Zoom Out | Reset | Add To New Card | Existing Card

Subject System Topic

organs. Young adults with CF typically have several manifestations of the disorder, including pancreatic insufficiency (eg, diarrhea), chronic

Exhibit Display

Cavitary lung lesion

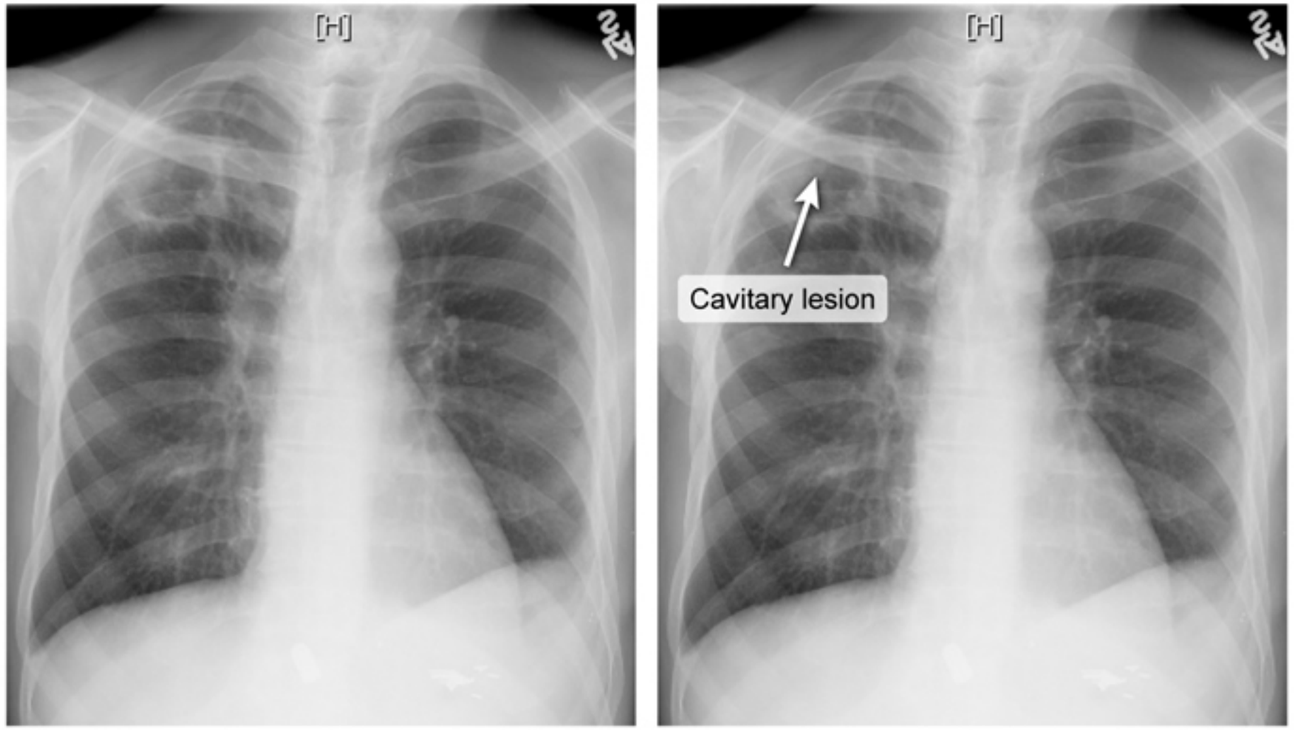

©UWorld

Zoom In | Zoom Out | Reset | Add To New Card | Existing Card

1
2
3
4
5
6
7
8
9
10
11
12
13
14
15
16
17
18
19
20
21
22
23
24
25
26
27
28
29
30
31

A 26-year-old previously healthy man comes to the emergency department due to fever, malaise, anorexia, and painless swelling of the left eye. His symptoms began after a month-long anthropology trip to rural Bolivia. During his stay, he lived in an adobe house with a thatched roof and unnetted windows and doors. Temperature is 38.3 C (101 F). Physical examination shows left-sided periorbital swelling and conjunctival erythema with no discharge. The remainder of the physical examination, including right eye examination, shows no abnormalities. Giemsa-stained peripheral blood smear is shown below:

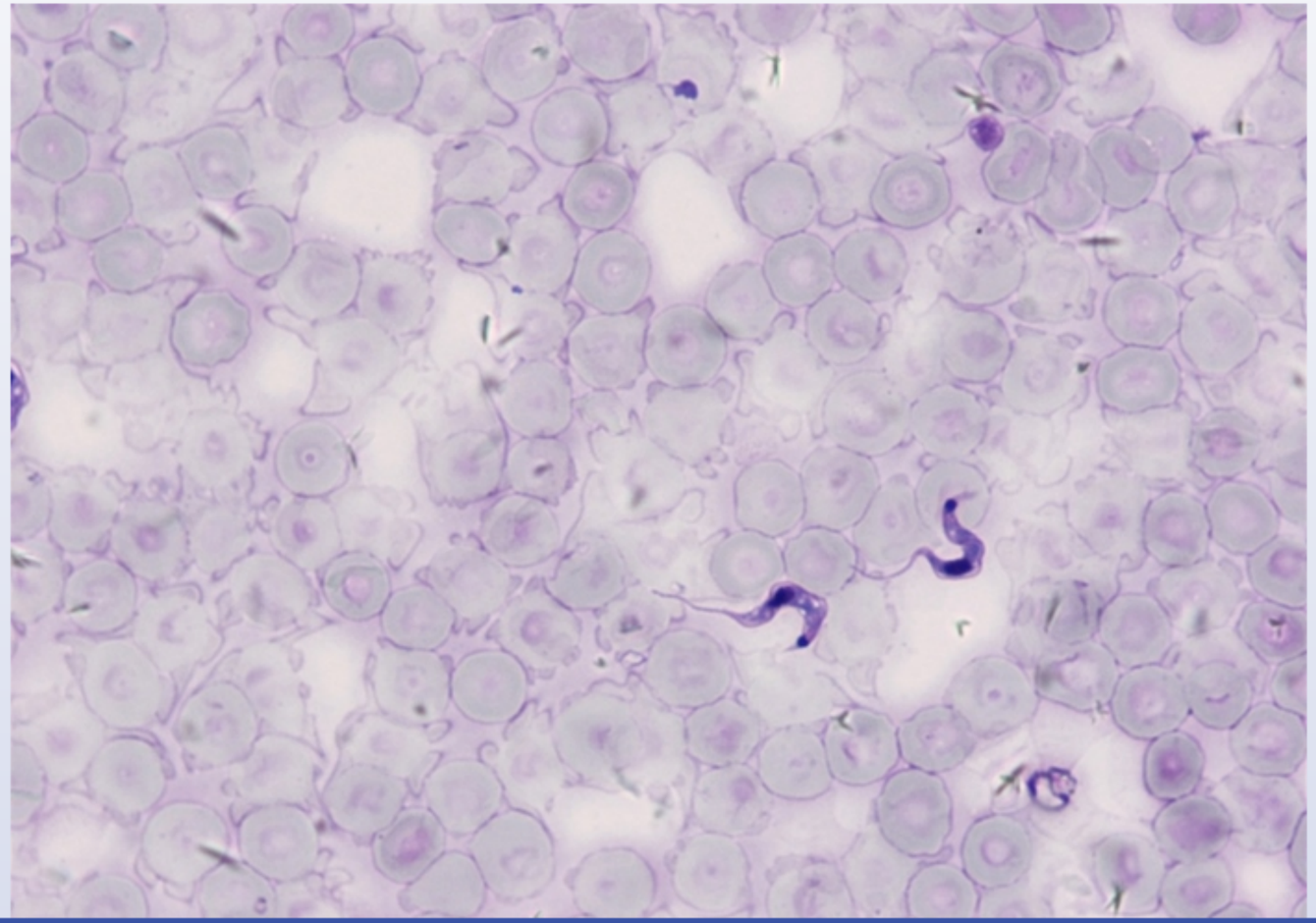

1
2
3
4
5
6
7
8
9
10
11
12
13
14
15
16
17
18
19
20
21
22
23
24
25
26
27
28
29
30
31

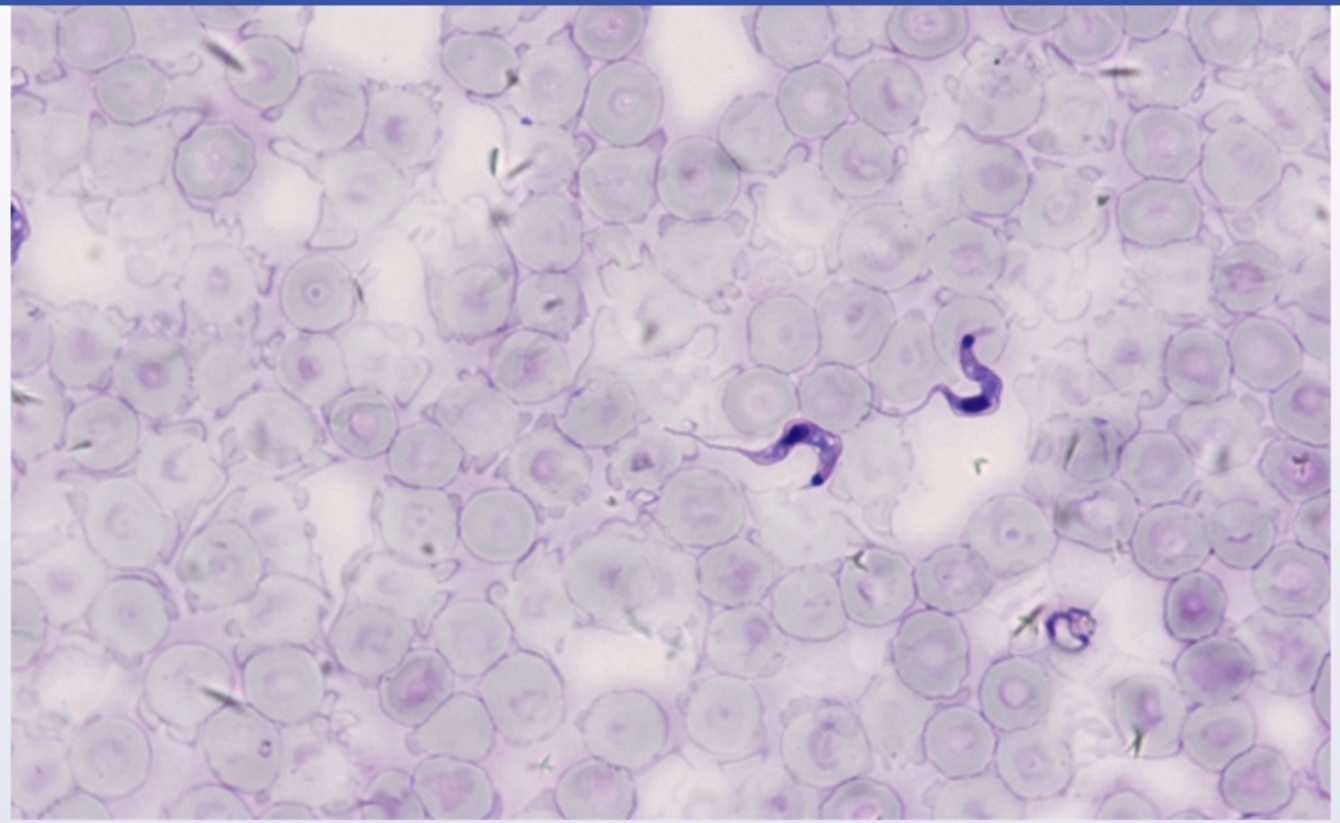

This patient is at greatest risk for which of the following complications if his condition is left untreated?

- A. Ascending aortic aneurysm
- B. Calcified brain lesions
- C. Cardiac arrhythmias
- D. Large joint arthritis
- E. Periportal liver fibrosis

1
2
3
4
5
6
7
8
9
10
11
12
13
14
15
16
17
18
19
20
21
22
23
24
25
26
27
28
29
30
31

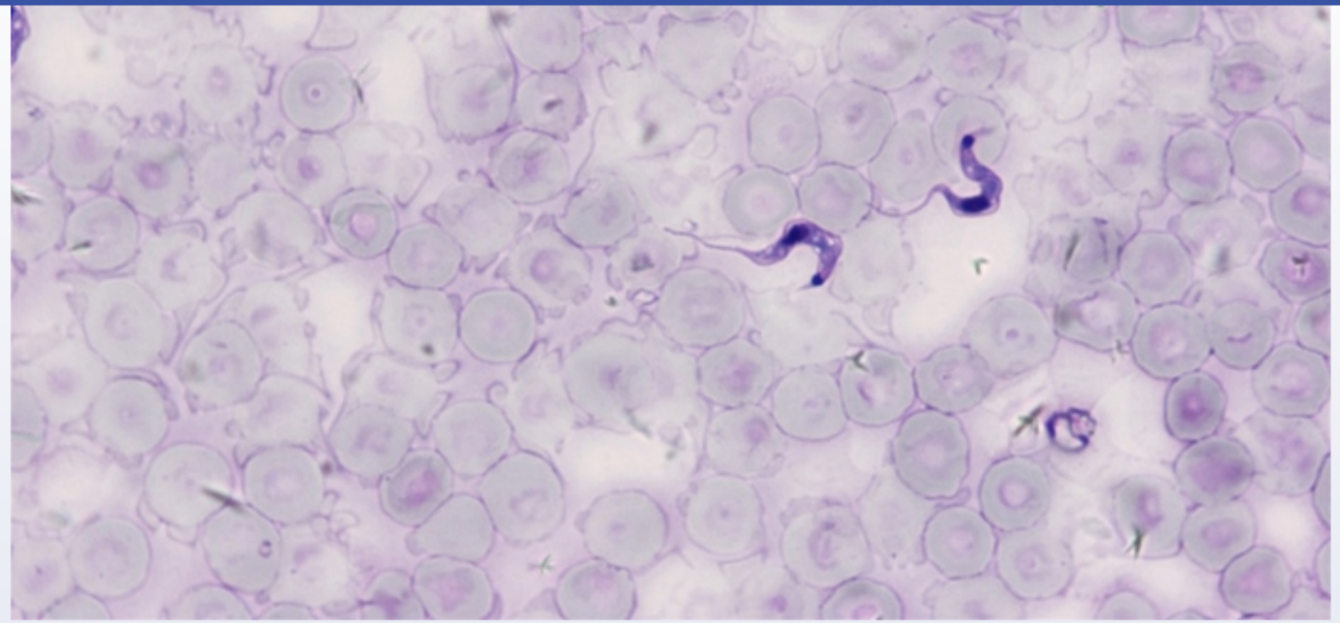

This patient is at greatest risk for which of the following complications if his condition is left untreated?

- A. Ascending aortic aneurysm
- B. Calcified brain lesions
- C. Cardiac arrhythmias
- D. Large joint arthritis
- E. Periportal liver fibrosis

Submit

1
2
3
4
5
6
7
8
9
10
11
12
13
14
15
16
17
18
19
20
21
22
23
24
25
26
27
28
29
30
31

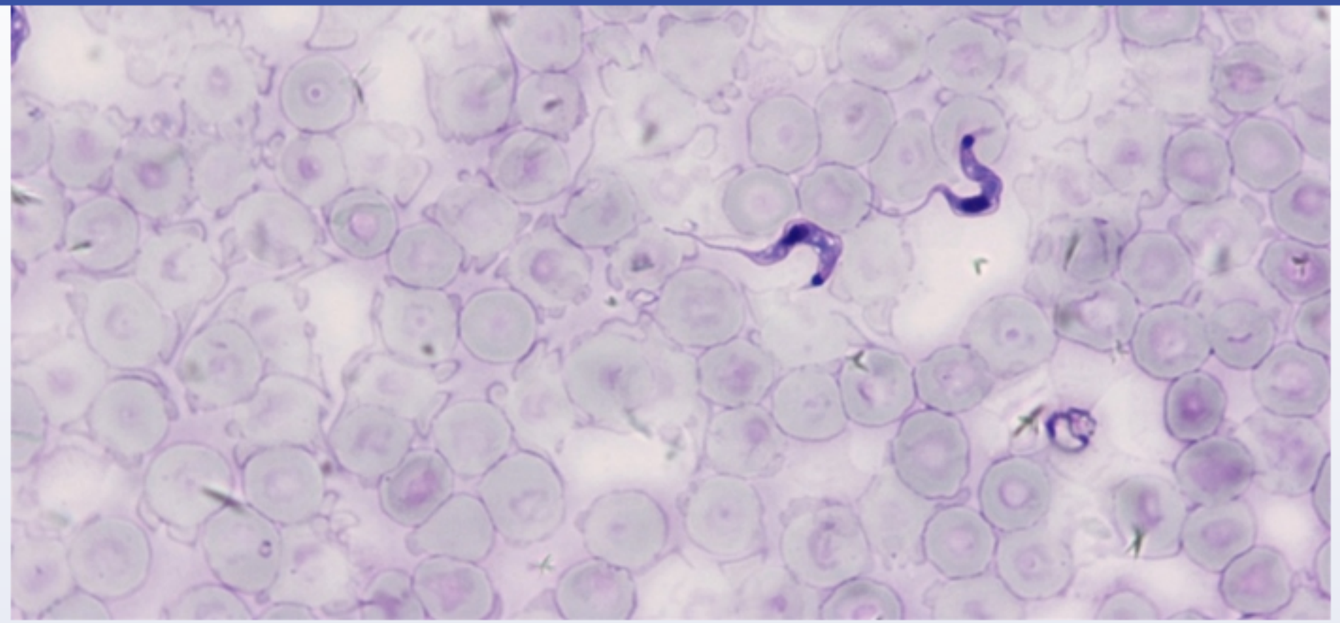

This patient is at greatest risk for which of the following complications if his condition is left untreated?

- A. Ascending aortic aneurysm (4%)
- B. Calcified brain lesions (10%)
- ✓ C. Cardiac arrhythmias (57%)
- D. Large joint arthritis (7%)
- E. Periportal liver fibrosis (19%)

Omitted
Correct answer

57%
Answered correctly

14 secs
Time Spent

05/20/2020
Last Updated

Chagas disease is a vector-borne protozoan illness endemic to most Latin American countries. Risk is greatest in those with long-term domestic exposure to the **Triatomine bug**, which nests in thatched roofing and the cracks of adobe or unfinished brick. Transmission occurs when the bug feeds on human blood during the night and defecates the underlying pathogen, ***Trypanosoma cruzi***, into the bite wound.

Chagas disease is divided into 2 phases:

- The acute phase (8-12 weeks after transmission) is characterized by circulating trypomastigotes that are detectable on blood microscopy. Most patients are asymptomatic, but a minority develop nonspecific symptoms (eg, fever, malaise, anorexia) and inflammation/swelling at the site of inoculation (eg, eye swelling following conjunctival inoculation).
- The chronic phase begins when the immune system eliminates circulating parasitemia, leading to resolution of acute symptoms. Patients subsequently develop a prolonged asymptomatic phase ("indeterminate form"), whereby serology is positive for *T cruzi*, but there are no symptoms, signs, detectable parasitemia, or indications of end-organ damage. After 1-3 decades, a minority of those with asymptomatic chronic infection develop end-organ disease of the heart or gastrointestinal system.

Chronic Chagas cardiomyopathy is the most common complication of Chagas disease. It is thought to be caused by chronic, low-grade, parasite-mediated myocarditis, which leads to the progressive destruction of cardiac fibers and subsequent cardiac fibrosis. Common complications include biventricular heart failure, cardiac **arrhythmias** (particularly ventricular arrhythmias), and **ventricular aneurysm** with intracardiac thrombus (leads to thromboembolic disease/stroke).

(Choice A) *Treponema pallidum* has an affinity for the aortic wall and can cause ascending aortic aneurysms (syphilitic aortitis) in patients with tertiary syphilis. Diagnosis is made with serology; treponemes are not visible on standard microscopy.

(Choice B) Neurocysticercosis, which is caused by the larval stage of the pork tapeworm *Taneia solium*, is characterized by the formation of multiple calcified brain lesions that may result in seizures and/or focal neurologic signs several years after transmission. Diagnosis is made with imaging and serology, not blood microscopy.

(Choice D) Lyme disease is a tick-borne illness caused by *Borrelia burgdorferi*. Early localized disease is characterized by a migrating erythematous, bull's-eye rash (erythema migrans) and nonspecific symptoms. Months or years later, patients can develop late manifestations, such as large joint arthritis or Lyme encephalopathy. *B burgdorferi* is a spirochete and cannot be seen on standard blood microscopy.

(Choice E) Schistosomiasis is transmitted to humans who swim or bathe in fresh water contaminated with cercariae from infected snails. The

chronic infection develop end-organ disease of the heart or gastrointestinal system.

Chronic Chagas cardiomyopathy is the most common complication of Chagas disease. It is thought to be caused by chronic, low-grade, parasite-mediated myocarditis, which leads to the progressive destruction of cardiac fibers and subsequent cardiac fibrosis. Common complications include biventricular heart failure, cardiac **arrhythmias** (particularly ventricular arrhythmias), and **ventricular aneurysm** with intracardiac thrombus (leads to thromboembolic disease/stroke).

(Choice A) *Treponema pallidum* has an affinity for the aortic wall and can cause ascending aortic aneurysms (syphilitic aortitis) in patients with tertiary syphilis. Diagnosis is made with serology; treponemes are not visible on standard microscopy.

(Choice B) Neurocysticercosis, which is caused by the larval stage of the pork tapeworm *Taneia solium*, is characterized by the formation of multiple calcified brain lesions that may result in seizures and/or focal neurologic signs several years after transmission. Diagnosis is made with imaging and serology, not blood microscopy.

(Choice D) Lyme disease is a tick-borne illness caused by *Borrelia burgdorferi*. Early localized disease is characterized by a migrating erythematous, bull's-eye rash (erythema migrans) and nonspecific symptoms. Months or years later, patients can develop late manifestations, such as large joint arthritis or Lyme encephalopathy. *B burgdorferi* is a spirochete and cannot be seen on standard blood microscopy.

(Choice E) Schistosomiasis is transmitted to humans who swim or bathe in fresh water contaminated with cercariae from infected snails. The fluke matures in the liver and spreads to the mesenteric vessels, where it releases eggs that can cause end-organ inflammation and fibrosis (eg, periportal liver fibrosis). Diagnosis is made by identifying eggs in urine or stool, not on blood microscopy.

Educational objective:
Chagas disease is a protozoal illness that is endemic to Latin America. Patients in rural areas are at greatest risk when their houses harbor the vector (Triatome bug) in adobe walls or thatched roofs. Acute infections are often asymptomatic, but patients can develop Chagas cardiomyopathy (eg, heart failure, ventricular arrhythmias, ventricular aneurysms) several decades later.

Microbiology	Infectious Diseases	Chagas disease
Subject	System	Topic

Copyright © UWorld. All rights reserved.

D. Large joint arthritis (7%)

Exhibit Display

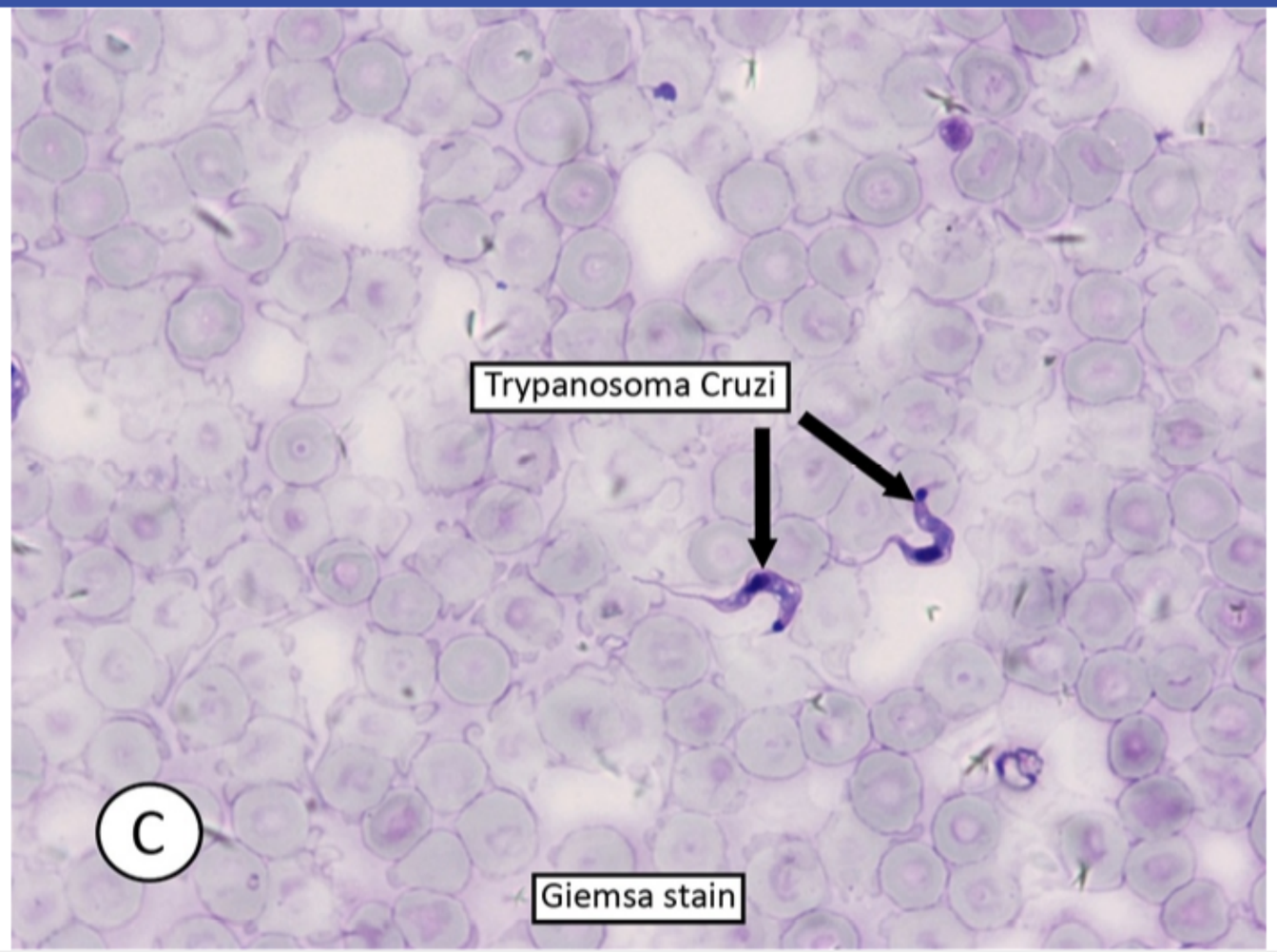

Zoom In | Zoom Out | Reset | Add To New Card | Existing Card

intracardiac thrombus (leads to thromboembolic disease/stroke).

1
2
3
4
5
6
7
8
9
10
11
12
13
14
15
16
17
18
19
20
21
22
23
24
25
26
27
28
29
30
31

A 64-year-old man comes to the office due to 3 days of diarrhea. He began to have nausea, vomiting, abdominal cramps, and diarrhea 24 hours after eating chicken salad at a fast-food restaurant. The patient continues to have 4-6 episodes of diarrhea per day with no blood in the stool. His wife, who ate the same food, had a few loose stools but felt well afterward. The patient takes a tumor necrosis factor inhibitor for psoriatic arthritis and a proton pump inhibitor for gastritis. Temperature is 38 C (100.4 F), blood pressure is 120/70 mm Hg, and pulse is 88/min. Abdominal examination reveals mild diffuse tenderness to palpation and increased bowel sounds. Cultures of the stool yield gram-negative bacilli that are non-lactose fermenting and oxidase negative. Which of the following is the most likely complication associated with this patient's current infection?

A. Chronic malabsorption

B. Generalized seizure

C. Guillain-Barré syndrome

D. Hemolytic uremic syndrome

E. Long-bone osteomyelitis

Submit

A 64-year-old man comes to the office due to 3 days of diarrhea. He began to have nausea, vomiting, abdominal cramps, and diarrhea 24 hours after eating chicken salad at a fast-food restaurant. The patient continues to have 4-6 episodes of diarrhea per day with no blood in the stool. His wife, who ate the same food, had a few loose stools but felt well afterward. The patient takes a tumor necrosis factor inhibitor for psoriatic arthritis and a proton pump inhibitor for gastritis. Temperature is 38 C (100.4 F), blood pressure is 120/70 mm Hg, and pulse is 88/min. Abdominal examination reveals mild diffuse tenderness to palpation and increased bowel sounds. Cultures of the stool yield gram-negative bacilli that are non-lactose fermenting and oxidase negative. Which of the following is the most likely complication associated with this patient's current infection?

- A. Chronic malabsorption (16%)
- B. Generalized seizure (4%)
- C. Guillain-Barré syndrome (15%)
- D. Hemolytic uremic syndrome (15%)
- ✓ E. Long-bone osteomyelitis (48%)

Omitted
Correct answer
E

48%
Answered correctly

02 secs
Time Spent

06/13/2020
Last Updated

Explanation

	Nontyphoidal *Salmonella*	Typhoidal *Salmonella*
Epidemiology	• *S enterica* • **Poultry/eggs**, exotic pets	• *S typhi*, *S paratyphi* • Humans only

	Nontyphoidal *Salmonella*	Typhoidal *Salmonella*
Epidemiology	• *S enterica* • **Poultry/eggs**, exotic pets • **Foodborne** (primarily) • Industrialized countries	• *S typhi*, *S paratyphi* • Humans only • Water/food contamination • **Developing countries**
Pathophysiology	Invasion of enterocytes → massive neutrophil-mediated inflammatory response in lamina propria/Peyer's patches → control of infection (usually)	Invasion of enterocytes → blunted neutrophil response due to **capsular antigen Vi** → extensive intracellular replication in macrophages → spread through lymphatics and RES
Manifestations	**Gastroenteritis** • Self-limited watery diarrhea • Rarely invasive (<5%): osteomyelitis, mycotic aneurysm, endocarditis	**Typhoid fever** • Progressive fever (pulse-temperature dissociation) • Rose spots, abdominal pain • HSM, GI bleed, perforation

GI = gastrointestinal; HSM = hepatosplenomegaly; RES = reticuloendothelial system.

Salmonella species are enteric gram-negative bacilli that are oxidase negative and generally non-lactose fermenting. Nontyphoidal strains such as *S enterica* are a major cause of **foodborne gastroenteritis**; there are an estimated 2-4 million cases in the United States annually. Transmission typically occurs after the consumption of contaminated **poultry products** (eg, chicken salad), including eggs. However, handling amphibians and reptiles can also lead to infection.

Ingested *Salmonella* must survive the acidic environment of the stomach prior to traveling to the small intestine to cause disease. Therefore, patients on acid suppression (eg, proton pump inhibitors) require smaller infectious doses and are generally at greater risk. In the small intestine, the organism swims through the mucus barrier, attaches to and penetrates enterocytes, and then travels within vacuoles from the apical end to the basolateral membrane and on to the lamina propria. Here, the pathogen is phagocytosed by macrophages and neutrophils and elicits a profound inflammatory response.

Salmonella species are enteric gram-negative bacilli that are oxidase negative and generally non-lactose fermenting. Nontyphoidal strains such as *S enterica* are a major cause of **foodborne gastroenteritis**; there are an estimated 2-4 million cases in the United States annually. Transmission typically occurs after the consumption of contaminated **poultry products** (eg, chicken salad), including eggs. However, handling amphibians and reptiles can also lead to infection.

Ingested *Salmonella* must survive the acidic environment of the stomach prior to traveling to the small intestine to cause disease. Therefore, patients on acid suppression (eg, proton pump inhibitors) require smaller infectious doses and are generally at greater risk. In the small intestine, the organism swims through the mucus barrier, attaches to and penetrates enterocytes, and then travels within vacuoles from the apical end to the basolateral membrane and on to the lamina propria. Here, the pathogen is phagocytosed by macrophages and neutrophils and elicits a profound inflammatory response.

Manifestations may be quite mild or may feature fever, nausea, vomiting, and watery diarrhea. Most cases resolve spontaneously within 3-4 days, but a minority of individuals develop **invasive disease** with spread through the bloodstream and reticuloendothelial system. **Long-bone osteomyelitis** is a common complication, particularly at sites of prior bone injury/prosthesis or in those with sickle cell disease. Endocarditis, mycotic aneurysm, and visceral abscesses can also occur. The risk of invasion is greatest in patients at the extremes of age and in those with **impaired immunity** (eg, AIDS, tumor necrosis factor-alpha inhibitor).

(Choice A) Chronic malabsorption can occur with *Giardia* infection due to blunting of the small intestine villi. *Giardia* is usually acquired from contaminated water, and symptoms (watery diarrhea, foul-smelling stool, bloating, nausea) typically begin >7 days after transmission.

(Choice B) Generalized seizures are often seen in children infected with *Shigella* and are thought to be due to the systemic absorption of *Shigella* enterotoxins. *Shigella* is often transmitted in day care centers but may be passed via contaminated vegetables. Infections are typically marked by high fever, abdominal pain, and hemorrhagic colitis.

(Choice C) Guillain-Barré syndrome is most often caused by preceding *Campylobacter jejuni* infection. Although *Campylobacter* is often transmitted by poultry and can cause a clinical illness similar to *Salmonella*, the organism is oxidase positive.

(Choice D) Hemolytic uremic syndrome is characterized by the triad of acute renal insufficiency, thrombocytopenia, and microangiopathic hemolytic anemia. It is frequently linked to infections with enterohemorrhagic *Escherichia coli*, a gram-negative, lactose-fermenting organism. *E coli* is typically transmitted through consumption of contaminated, undercooked ground beef and is usually associated with bloody diarrhea.

Manifestations may be quite mild or may feature fever, nausea, vomiting, and watery diarrhea. Most cases resolve spontaneously within 3-4 days, but a minority of individuals develop **invasive disease** with spread through the bloodstream and reticuloendothelial system. **Long-bone osteomyelitis** is a common complication, particularly at sites of prior bone injury/prosthesis or in those with sickle cell disease. Endocarditis, mycotic aneurysm, and visceral abscesses can also occur. The risk of invasion is greatest in patients at the extremes of age and in those with **impaired immunity** (eg, AIDS, tumor necrosis factor-alpha inhibitor).

(Choice A) Chronic malabsorption can occur with *Giardia* infection due to blunting of the small intestine villi. *Giardia* is usually acquired from contaminated water, and symptoms (watery diarrhea, foul-smelling stool, bloating, nausea) typically begin >7 days after transmission.

(Choice B) Generalized seizures are often seen in children infected with *Shigella* and are thought to be due to the systemic absorption of *Shigella* enterotoxins. *Shigella* is often transmitted in day care centers but may be passed via contaminated vegetables. Infections are typically marked by high fever, abdominal pain, and hemorrhagic colitis.

(Choice C) Guillain-Barré syndrome is most often caused by preceding *Campylobacter jejuni* infection. Although *Campylobacter* is often transmitted by poultry and can cause a clinical illness similar to *Salmonella*, the organism is oxidase positive.

(Choice D) Hemolytic uremic syndrome is characterized by the triad of acute renal insufficiency, thrombocytopenia, and microangiopathic hemolytic anemia. It is frequently linked to infections with enterohemorrhagic *Escherichia coli*, a gram-negative, lactose-fermenting organism. *E coli* is typically transmitted through consumption of contaminated, undercooked ground beef and is usually associated with bloody diarrhea.

Educational objective:
Nontyphoidal *Salmonella* is a leading cause of foodborne gastroenteritis. Most cases are marked by 3-4 days of self-limited fever, nausea, vomiting, and watery diarrhea. A minority of individuals develop subsequent invasive disease with spread to the long bones (osteomyelitis), vasculature (mycotic aneurysm), or heart (endocarditis). Risk of invasion is greatest in those with sickle cell disease or impaired immunity or at the extremes of age.

Microbiology	Infectious Diseases	Acute diarrhea
Subject	System	Topic

Copyright © UWorld. All rights reserved.

1
2
3
4
5
6
7
8
9
10
11
12
13
14
15
16
17
18
19
20
21
22
23
24
25
26
27
28
29
30
31

A 42-year-old man comes to the office due to 2 weeks of progressive fever, chills, abdominal discomfort, and loose stools, which began during a trip to Southeast Asia. He received no pre-travel vaccinations and did not strictly follow food and water safety precautions during the trip. The patient has no chronic medical conditions but has experienced a prior episode of *Salmonella enteritidis* gastroenteritis, which resolved with symptomatic care. Temperature is 39.4 C (103 F), blood pressure is 110/64 mm Hg, pulse is 62/min, and respirations are 18/min. Physical examination reveals a faint macular rash on the trunk. There is mild tenderness on palpation of lower abdominal quadrants with no guarding or rebound tenderness. Blood culture grows non-lactose fermenting gram-negative rods. Which of the following best explains the prolonged and severe disease course from this pathogen compared to the patient's previous bacterial infection?

- A. Contact-dependent host cytotoxicity
- B. Cross-reacting antibody formation
- C. Extensive intra-phagocytic multiplication
- D. Potent exotoxin production
- E. Villus epithelial cell destruction

Submit

A 42-year-old man comes to the office due to 2 weeks of progressive fever, chills, abdominal discomfort, and loose stools, which began during a trip to Southeast Asia. He received no pre-travel vaccinations and did not strictly follow food and water safety precautions during the trip. The patient has no chronic medical conditions but has experienced a prior episode of *Salmonella enteritidis* gastroenteritis, which resolved with symptomatic care. Temperature is 39.4 C (103 F), blood pressure is 110/64 mm Hg, pulse is 62/min, and respirations are 18/min. Physical examination reveals a faint macular rash on the trunk. There is mild tenderness on palpation of lower abdominal quadrants with no guarding or rebound tenderness. Blood culture grows non-lactose fermenting gram-negative rods. Which of the following best explains the prolonged and severe disease course from this pathogen compared to the patient's previous bacterial infection?

- A. Contact-dependent host cytotoxicity (6%)
- B. Cross-reacting antibody formation (12%)
- ✓ C. Extensive intra-phagocytic multiplication (34%)
- D. Potent exotoxin production (26%)
- E. Villus epithelial cell destruction (19%)

Omitted
Correct answer
C

34%
Answered correctly

02 secs
Time Spent

03/27/2020
Last Updated

Explanation

	Nontyphoidal *Salmonella*	Typhoidal *Salmonella*
	• *S enterica*	• *S typhi*, *S paratyphi*

	Nontyphoidal *Salmonella*	Typhoidal *Salmonella*
Epidemiology	• *S enterica* • **Poultry/eggs**, exotic pets • **Foodborne** (primarily) • Industrialized countries	• *S typhi*, *S paratyphi* • Humans only • Water/food contamination • **Developing countries**
Pathophysiology	Invasion of enterocytes → massive neutrophil-mediated inflammatory response in lamina propria/Peyer's patches → control of infection (usually)	Invasion of enterocytes → blunted neutrophil response due to **capsular antigen Vi** → extensive intracellular replication in macrophages → spread through lymphatics and RES
Manifestations	**Gastroenteritis** • Self-limited watery diarrhea • Rarely invasive (<5%): osteomyelitis, mycotic aneurysm, endocarditis	**Typhoid fever** • Progressive fever (pulse-temperature dissociation) • Rose spots, abdominal pain • HSM, GI bleed, perforation

GI = gastrointestinal; HSM = hepatosplenomegaly; RES = reticuloendothelial system.

Salmonella are gram-negative, non-lactose–fermenting, motile enteric rods that are divided into nontyphoidal (eg, *S enteritidis*) and typhoidal (eg, *S typhi*, *S paratyphi*) strains. Both strains are able to cause disease by penetrating enterocytes, where they then travel in vacuoles from the apical to the basolateral end of the cell to invade the lamina propria. However, the pathogenesis then diverges, as follows:

- **Nontyphoidal species** are phagocytosed by neutrophils and macrophages in the lamina propria and induce a massive inflammatory response marked by dramatic neutrophil infiltration. The cytokine-mediated inflammatory response typically results in 1-5 days of **gastroenteritis** (eg, watery diarrhea, abdominal pain, and fever). Most cases resolve without intervention.
- In contrast, **typhoidal species** contain a specialized **capsular antigen** called **Vi** (short for virulence) that inhibits neutrophil recruitment and phagocytosis. This limits the acute inflammatory response that helps contain the nontyphoidal species. It also inhibits macrophages from generating an oxidative burst to destroy the bacteria, which allows the pathogen to undergo extensive **unchecked intracellular replication** and subsequently disseminate through the lymphatic and reticuloendothelial system. This results in **typhoid fever**.

Salmonella are gram-negative, non-lactose–fermenting, motile enteric rods that are divided into nontyphoidal (eg, *S enteritidis*) and typhoidal (eg, *S typhi*, *S paratyphi*) strains. Both strains are able to cause disease by penetrating enterocytes, where they then travel in vacuoles from the apical to the basolateral end of the cell to invade the lamina propria. However, the pathogenesis then diverges, as follows:

- **Nontyphoidal species** are phagocytosed by neutrophils and macrophages in the lamina propria and induce a massive inflammatory response marked by dramatic neutrophil infiltration. The cytokine-mediated inflammatory response typically results in 1-5 days of **gastroenteritis** (eg, watery diarrhea, abdominal pain, and fever). Most cases resolve without intervention.
- In contrast, **typhoidal species** contain a specialized **capsular antigen** called **Vi** (short for virulence) that inhibits neutrophil recruitment and phagocytosis. This limits the acute inflammatory response that helps contain the nontyphoidal species. It also inhibits macrophages from generating an oxidative burst to destroy the bacteria, which allows the pathogen to undergo extensive **unchecked intracellular replication** and subsequently disseminate through the lymphatic and reticuloendothelial system. This results in **typhoid fever**.

Typhoidal strains of *Salmonella* are found only in humans and are typically transmitted by the consumption of food or water contaminated by human feces. Typhoid *Salmonella* is endemic to areas where sanitation is poor. Travelers may become ill if they are unvaccinated (typhoid vaccine) and do not strictly adhere to food and water safety precautions. Manifestations begin approximately a week after transmission with an **escalating fever** that is often associated with relative bradycardia (**pulse-temperature dissociation**). Approximately a week later, patients typically develop abdominal pain, diarrhea or constipation, and transient salmon-colored macules (**rose spots**) on the trunk. Serious complications such as intestinal bleeding and perforation can occur later.

(Choice A) Contact between *Entamoeba histolytica* and the host cell results in the insertion of an amebic channel-forming protein in the host cell membrane that causes cell death. Manifestations of *E histolytica* infection typically include bloody diarrhea (colitis) and/or extraintestinal manifestations (eg, liver abscess).

(Choice B) *Campylobacter* infection is a common cause of self-limited acute infectious diarrhea and may result in the formation of cross-reacting antibodies to GM1 ganglioside, leading to Guillain-Barré syndrome. *Campylobacter* symptoms usually last <7 days and do not include rose spots or temperature dissociation.

(Choice D) *Shigella* and enterohemorrhagic *Escherichia coli* produce a potent exotoxin that can result in cell death, hemorrhagic colitis, and systemic manifestations (eg, hemolytic-uremic syndrome). Exotoxins do not play a prominent role in *Salmonella* infection.

(Choice E) Rotavirus and *giardia* damage intestinal villi, which leads to intestinal malabsorption due to villous blunting and decreased levels of

Typhoidal strains of *Salmonella* are found only in humans and are typically transmitted by the consumption of food or water contaminated by human feces. Typhoid *Salmonella* is endemic to areas where sanitation is poor. Travelers may become ill if they are unvaccinated (typhoid vaccine) and do not strictly adhere to food and water safety precautions. Manifestations begin approximately a week after transmission with an **escalating fever** that is often associated with relative bradycardia (**pulse-temperature dissociation**). Approximately a week later, patients typically develop abdominal pain, diarrhea or constipation, and transient salmon-colored macules (**rose spots**) on the trunk. Serious complications such as intestinal bleeding and perforation can occur later.

(Choice A) Contact between *Entamoeba histolytica* and the host cell results in the insertion of an amebic channel-forming protein in the host cell membrane that causes cell death. Manifestations of *E histolytica* infection typically include bloody diarrhea (colitis) and/or extraintestinal manifestations (eg, liver abscess).

(Choice B) *Campylobacter* infection is a common cause of self-limited acute infectious diarrhea and may result in the formation of cross-reacting antibodies to GM1 ganglioside, leading to Guillain-Barré syndrome. *Campylobacter* symptoms usually last <7 days and do not include rose spots or temperature dissociation.

(Choice D) *Shigella* and enterohemorrhagic *Escherichia coli* produce a potent exotoxin that can result in cell death, hemorrhagic colitis, and systemic manifestations (eg, hemolytic-uremic syndrome). Exotoxins do not play a prominent role in *Salmonella* infection.

(Choice E) Rotavirus and *giardia* damage intestinal villi, which leads to intestinal malabsorption due to villous blunting and decreased levels of brush border enzymes (eg, maltase, sucrase, lactase).

Educational objective:
Typhoid strains of *Salmonella* contain a capsular antigen (Vi) that inhibits neutrophil phagocytosis, neutrophil recruitment, and macrophage-mediated destruction. Therefore, typhoid strains are able to undergo extensive replication within the intracellular space of macrophages with subsequent spread through the lymphatic and reticuloendothelial system, leading to a widespread systemic disease (typhoid fever).

Microbiology	Infectious Diseases	Typhoid
Subject	System	Topic

Copyright © UWorld. All rights reserved.

1
2
3
4
5
6
7
8
9
10
11
12
13
14
15
16
17
18
19
20
21
22
23
24
25
26
27
28
29
30
31

A 1-year-old boy is brought to the emergency department by his mother because of high fever, irritability, and photophobia. He recently underwent ventriculoperitoneal shunt placement for congenital hydrocephalus. On physical examination, his temperature is 38.3° C (101° F), and passive flexion of the neck results in spontaneous flexion of the hips and knees. Blood cultures grow coagulase-negative *Staphylococcus*. Which of the following is the most important virulence mechanism by which this bacterium causes disease?

A. Intracellular existence

B. Outer polysaccharide capsule

C. Presence of protein A on the cell wall

D. Release of exotoxins

E. Synthesis of an extracellular polysaccharide matrix

Submit

1
2
3
4
5
6
7
8
9
10
11
12
13
14
15
16
17
18
19
20
21
22
23
24
25
26
27
28
29
30
31

A 1-year-old boy is brought to the emergency department by his mother because of high fever, irritability, and photophobia. He recently underwent ventriculoperitoneal shunt placement for congenital hydrocephalus. On physical examination, his temperature is 38.3° C (101° F), and passive flexion of the neck results in spontaneous flexion of the hips and knees. Blood cultures grow coagulase-negative *Staphylococcus*. Which of the following is the most important virulence mechanism by which this bacterium causes disease?

A. Intracellular existence (1%)

B. Outer polysaccharide capsule (15%)

C. Presence of protein A on the cell wall (27%)

D. Release of exotoxins (13%)

✓ E. Synthesis of an extracellular polysaccharide matrix (42%)

Omitted
Correct answer
E

42%
Answered correctly

01 sec
Time Spent

01/15/2020
Last Updated

Explanation

1
2
3
4
5
6
7
8
9
10
11
12
13
14
15
16
17
18
19
20
21
22
23
24
25
26
27
28
29
30
31

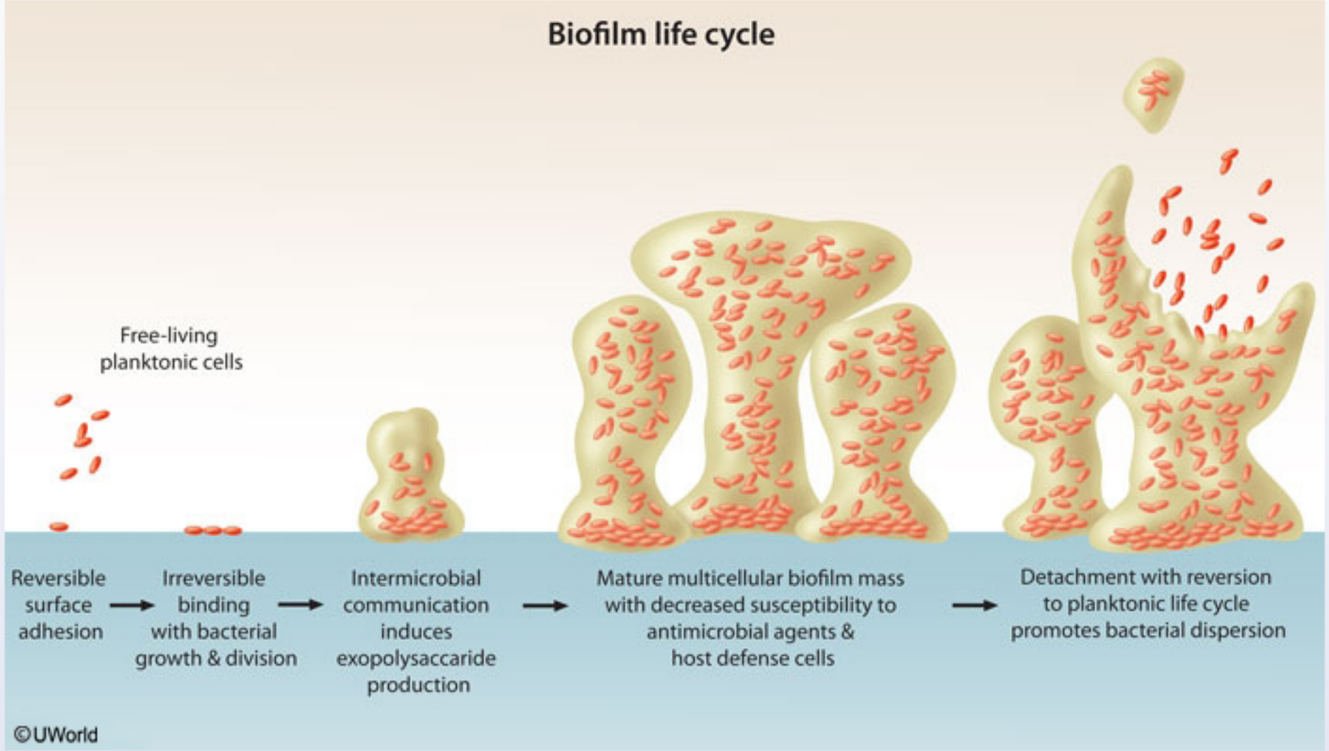

Staphylococcus epidermidis, a coagulase-negative *Staphylococcus* species and a component of normal skin flora, is one of the most common causes of infections associated with foreign bodies (including ventriculoperitoneal shunts). *S epidermidis* is adept at causing foreign body infections because of its ability to form biofilms.

Once introduced into the body, foreign bodies quickly become coated with a layer of host proteins, including fibrinogen and fibronectin. These proteins then serve as binding sites for *S epidermidis*. After attachment occurs, the bacteria multiply and communicate with one another to induce synthesis of an extracellular polysaccharide matrix that encases the bacteria. The resulting biofilm functions as a barrier to antibiotic penetration and interferes with host defenses, including opsonization, neutrophil migration, and even T lymphocyte activation. Once mature, these biofilms can disperse individual pathogen "seeds" (planktonic cells) into the bloodstream and surrounding areas, further disseminating the infection. Definitive treatment of infections caused by biofilm-producing organisms often requires removal of the foreign body.

©UWorld

Staphylococcus epidermidis, a coagulase-negative *Staphylococcus* species and a component of normal skin flora, is one of the most common causes of infections associated with foreign bodies (including ventriculoperitoneal shunts). *S epidermidis* is adept at causing foreign body infections because of its ability to form biofilms.

Once introduced into the body, foreign bodies quickly become coated with a layer of host proteins, including fibrinogen and fibronectin. These proteins then serve as binding sites for *S epidermidis*. After attachment occurs, the bacteria multiply and communicate with one another to induce synthesis of an extracellular polysaccharide matrix that encases the bacteria. The resulting biofilm functions as a barrier to antibiotic penetration and interferes with host defenses, including opsonization, neutrophil migration, and even T lymphocyte activation. Once mature, these biofilms can disperse individual pathogen "seeds" (planktonic cells) into the bloodstream and surrounding areas, further disseminating the infection. Definitive treatment of infections caused by biofilm-producing organisms often requires removal of the foreign body.

(Choice A) *S epidermidis* is not an intracellular organism. Examples of obligate intracellular organisms include *Chlamydiae* and *Rickettsiae*. Facultative intracellular organisms include *Legionella*, *Listeria*, *Mycobacterium*, *Neisseria*, and *Salmonella*.

(Choice B) *S epidermidis* is not an encapsulated bacterium. Examples of encapsulated bacteria are *Streptococcus pneumoniae*, *Haemophilus influenzae* type B, and *Neisseria meningitidis*. Asplenic individuals are unable to opsonize encapsulated pathogens and are at risk of infection from these organisms.

(Choice C) Protein A is a surface protein found on the cell wall of *Staphylococcus aureus* that binds to the Fc region of immunoglobulins. *S aureus* uses Protein A to inhibit opsonization and phagocytic engulfment.

(Choice D) Exotoxin production is not a known pathogenic mechanism of *S epidermidis*. Examples of well- known exotoxins include staphylococcal enterotoxins (food poisoning), botulinum toxin, diphtheria toxin, tetanus toxin, and pertussis toxin.

Educational objective:
Staphylococcus epidermidis is a common cause of foreign body infections due to its ability to produce adherent biofilms.

References

- Biofilms: microbes and disease.

Once introduced into the body, foreign bodies quickly become coated with a layer of host proteins, including fibrinogen and fibronectin. These proteins then serve as binding sites for *S epidermidis*. After attachment occurs, the bacteria multiply and communicate with one another to induce synthesis of an extracellular polysaccharide matrix that encases the bacteria. The resulting biofilm functions as a barrier to antibiotic penetration and interferes with host defenses, including opsonization, neutrophil migration, and even T lymphocyte activation. Once mature, these biofilms can disperse individual pathogen "seeds" (planktonic cells) into the bloodstream and surrounding areas, further disseminating the infection. Definitive treatment of infections caused by biofilm-producing organisms often requires removal of the foreign body.

(Choice A) *S epidermidis* is not an intracellular organism. Examples of obligate intracellular organisms include *Chlamydiae* and *Rickettsiae*. Facultative intracellular organisms include *Legionella*, *Listeria*, *Mycobacterium*, *Neisseria*, and *Salmonella*.

(Choice B) *S epidermidis* is not an encapsulated bacterium. Examples of encapsulated bacteria are *Streptococcus pneumoniae*, *Haemophilus influenzae* type B, and *Neisseria meningitidis*. Asplenic individuals are unable to opsonize encapsulated pathogens and are at risk of infection from these organisms.

(Choice C) Protein A is a surface protein found on the cell wall of *Staphylococcus aureus* that binds to the Fc region of immunoglobulins. *S aureus* uses Protein A to inhibit opsonization and phagocytic engulfment.

(Choice D) Exotoxin production is not a known pathogenic mechanism of *S epidermidis*. Examples of well- known exotoxins include staphylococcal enterotoxins (food poisoning), botulinum toxin, diphtheria toxin, tetanus toxin, and pertussis toxin.

Educational objective:
Staphylococcus epidermidis is a common cause of foreign body infections due to its ability to produce adherent biofilms.

References

- Biofilms: microbes and disease.

Microbiology	Infectious Diseases	Staphylococci
Subject	System	Topic

Copyright © UWorld. All rights reserved.

Exhibit Display

Biofilm-producing organism	Common settings
Staphylococcus epidermidis	Prosthetic devices, intravenous catheters
Streptococcus mutans & *Streptococcus sanguinis*	Dental plaques
Pseudomonas aeruginosa	Cystic fibrosis pneumonia, contact lenses
Viridans group streptococci	Endocarditis
Nontypable *Hemophilus influenza*	Otitis media

©UWorld

Zoom In Zoom Out Reset Add To New Card | Existing Card

1
2
3
4
5
6
7
8
9
10
11
12
13
14
15
16
17
18
19
20
21
22
23
24
25
26
27
28
29
30
31

An 8-year-old boy who recently moved to the United States from Indonesia is brought to the emergency department due to fever, sore throat, and difficulty breathing. His immunization status cannot be determined. Physical examination shows extensive, coalescing, gray pharyngeal exudate and cervical adenopathy. Several days after being admitted to the hospital, he dies of myocarditis and severe heart failure. The presence of which of the following would most likely have prevented this patient's death?

A. Activated CD8 T lymphocytes

B. Complement-fixing IgM

C. IgA against capsular proteins

D. IgG against circulating proteins

E. IgM from T-cell–independent response

Submit

An 8-year-old boy who recently moved to the United States from Indonesia is brought to the emergency department due to fever, sore throat, and difficulty breathing. His immunization status cannot be determined. Physical examination shows extensive, coalescing, gray pharyngeal exudate and cervical adenopathy. Several days after being admitted to the hospital, he dies of myocarditis and severe heart failure. The presence of which of the following would most likely have prevented this patient's death?

A. Activated CD8 T lymphocytes (8%)

B. Complement-fixing IgM (5%)

C. IgA against capsular proteins (12%)

✓ D. IgG against circulating proteins (68%)

E. IgM from T-cell–independent response (5%)

Omitted
Correct answer
D

68%
Answered correctly

02 secs
Time Spent

02/18/2020
Last Updated

Explanation

Diphtheria	
Epidemiology	• Rare in developed countries due to widespread vaccination • Risk: inadequate vaccination/10-year booster shot
Pathogenesis	• **Toxigenic *Corynebacterium diphtheriae*** colonizes respiratory tract → secretes **diphtheria toxin** → inhibits host protein synthesis (ADP-ribosylation of EF-2) → local and

Diphtheria	
Epidemiology	• Rare in developed countries due to widespread vaccination • Risk: inadequate vaccination/10-year booster shot
Pathogenesis	• **Toxigenic *Corynebacterium diphtheriae*** colonizes respiratory tract → secretes **diphtheria toxin** → inhibits host protein synthesis (ADP-ribosylation of EF-2) → local and systemic toxin-mediated effects
Manifestations	• Local: **pseudomembranous pharyngitis**, cervical LAD • Systemic: **myocarditis**/heart failure, neurologic toxicity • Pharyngeal edema/pseudomembrane spread can obstruct respiratory tract
Treatment	• **Diphtheria antitoxin** (most important) • Antibiotics

EF-2 = elongation factor-2; LAD = lymphadenopathy.

This patient with an uncertain vaccination history likely died from **diphtheria**, a clinical illness caused by **toxigenic strains** of *Corynebacterium diphtheriae*. The disease is rare in the developed world due to widespread vaccination with diphtheria toxoid, but outbreaks often occur in regions where vaccination efforts are insufficient (eg, Southeast Asia). Most cases are transmitted by aerosolized droplets from asymptomatic carriers or infected patients. Although the pathogen has little capacity for invasion, it generates a **potent exotoxin** (diphtheria toxin) that irreversibly inhibits protein synthesis through ADP-ribosylation of elongation factor-2, leading to host cell death and necrosis. Local effects of the toxin include pharyngitis and laryngotracheitis, often with an **extensive**, **coalescing exudate** (pseudomembrane). Absorption of the toxin into the bloodstream results in potentially life-threatening **myocarditis** and neuritis.

Diphtheria can be prevented with the diphtheria-pertussis-tetanus (DPT) childhood vaccination, which generates **neutralizing IgG antibodies** against the binding component (B subunit) of the diphtheria exotoxin. The vaccine inhibits toxin-mediated cell damage and also reduces the competitive advantage of toxigenic strains, thereby reducing toxigenic carriage rates within the population.

(Choice A) CD8 lymphocytes destroy cells infected with intracellular pathogens (eg, viruses) as well as cells damaged by cancer. They do not

1
2
3
4
5
6
7
8
9
10
11
12
13
14
15
16
17
18
19
20
21
22
23
24
25
26
27
28
29
30
31

This patient with an uncertain vaccination history likely died from **diphtheria**, a clinical illness caused by **toxigenic strains** of *Corynebacterium diphtheriae*. The disease is rare in the developed world due to widespread vaccination with diphtheria toxoid, but outbreaks often occur in regions where vaccination efforts are insufficient (eg, Southeast Asia). Most cases are transmitted by aerosolized droplets from asymptomatic carriers or infected patients. Although the pathogen has little capacity for invasion, it generates a **potent exotoxin** (diphtheria toxin) that irreversibly inhibits protein synthesis through ADP-ribosylation of elongation factor-2, leading to host cell death and necrosis. Local effects of the toxin include pharyngitis and laryngotracheitis, often with an **extensive**, **coalescing exudate** (pseudomembrane). Absorption of the toxin into the bloodstream results in potentially life-threatening **myocarditis** and neuritis.

Diphtheria can be prevented with the diphtheria-pertussis-tetanus (DPT) childhood vaccination, which generates **neutralizing IgG antibodies** against the binding component (B subunit) of the diphtheria exotoxin. The vaccine inhibits toxin-mediated cell damage and also reduces the competitive advantage of toxigenic strains, thereby reducing toxigenic carriage rates within the population.

(Choice A) CD8 lymphocytes destroy cells infected with intracellular pathogens (eg, viruses) as well as cells damaged by cancer. They do not bind to and eliminate circulating exotoxins.

(Choices B and E) IgM opsonization and complement fixation are important mechanisms for combating extracellular infections, particularly with encapsulated organisms. Although vaccination may stimulate an IgM response, long-term protection is primarily mediated by IgG antibodies.

(Choice C) IgA is the primary immunoglobulin found on mucosal surfaces and in secretions. It does not have significant opsonizing or complement-activating properties. Instead, it prevents infection by inhibiting bacterial interaction with epithelial cells (eg, attachment, invasion). IgA antibodies may help prevent diphtheria colonization. However, *C diphtheriae* does not have a polysaccharide capsule.

Educational objective:
Toxigenic strains of *Corynebacterium diphtheriae* produce diphtheria toxin, which irreversibly inhibits host protein synthesis due to ADP-ribosylation of elongation factor-2. Local effects include pseudomembranous pharyngitis; systemic effects include potentially life-threatening myocarditis and neuritis. Immunization with diphtheria toxoid generates protective circulating IgG against the exotoxin B subunit.

Microbiology	Infectious Diseases	Diphtheria
Subject	System	Topic

1
2
3
4
5
6
7
8
9
10
11
12
13
14
15
16
17
18
19
20
21
22
23
24
25
26
27
28
29
30
31

diphtheriae. The disease is rare in the developed world due to widespread vaccination with diphtheria toxoid, but outbreaks often occur in regions where vaccination efforts are insufficient (eg, Southeast Asia). Most cases are transmitted by aerosolized droplets from asymptomatic carriers or infected patients. Although the pathogen has little capacity for invasion, it generates a **potent exotoxin** (diphtheria toxin) that irreversibly inhibits protein synthesis through ADP-ribosylation of elongation factor-2, leading to host cell death and necrosis. Local effects of the toxin include pharyngitis and laryngotracheitis, often with an **extensive**, **coalescing exudate** (pseudomembrane). Absorption of the toxin into the bloodstream results in potentially life-threatening **myocarditis** and neuritis.

Diphtheria can be prevented with the diphtheria-pertussis-tetanus (DPT) childhood vaccination, which generates **neutralizing IgG antibodies** against the binding component (B subunit) of the diphtheria exotoxin. The vaccine inhibits toxin-mediated cell damage and also reduces the competitive advantage of toxigenic strains, thereby reducing toxigenic carriage rates within the population.

(Choice A) CD8 lymphocytes destroy cells infected with intracellular pathogens (eg, viruses) as well as cells damaged by cancer. They do not bind to and eliminate circulating exotoxins.

(Choices B and E) IgM opsonization and complement fixation are important mechanisms for combating extracellular infections, particularly with encapsulated organisms. Although vaccination may stimulate an IgM response, long-term protection is primarily mediated by IgG antibodies.

(Choice C) IgA is the primary immunoglobulin found on mucosal surfaces and in secretions. It does not have significant opsonizing or complement-activating properties. Instead, it prevents infection by inhibiting bacterial interaction with epithelial cells (eg, attachment, invasion). IgA antibodies may help prevent diphtheria colonization. However, *C diphtheriae* does not have a polysaccharide capsule.

Educational objective:
Toxigenic strains of *Corynebacterium diphtheriae* produce diphtheria toxin, which irreversibly inhibits host protein synthesis due to ADP-ribosylation of elongation factor-2. Local effects include pseudomembranous pharyngitis; systemic effects include potentially life-threatening myocarditis and neuritis. Immunization with diphtheria toxoid generates protective circulating IgG against the exotoxin B subunit.

Microbiology	Infectious Diseases	Diphtheria
Subject	System	Topic

Copyright © UWorld. All rights reserved.

1
2
3
4
5
6
7
8
9
10
11
12
13
14
15
16
17
18
19
20
21
22
23
24
25
26
27
28
29
30
31

A 21-year-old man comes to the urgent care clinic with a lesion on his penis. He noted a painful ulcer on the right side of the penis 4 days ago and it has progressively increased in size since then. The patient has had no dysuria, hematuria, or penile discharge. He is a tourist visiting New York City from Botswana. He is HIV-positive and is sexually active. The patient currently takes no medications. He appears comfortable and is afebrile. On genitourinary examination, there is a 1.5-cm ulceration on the right side of the base of the penis; this lesion is very tender and soft; has irregular, ragged borders; and is covered with grey exudate. There is no penile discharge. There is a palpable, tender, enlarged inguinal lymph node in the right groin. The examination is otherwise unremarkable. A scraping of the ulcer is performed. Polymerase chain reaction testing for herpes simplex virus is negative, and darkfield microscopy reveals no organisms. Which of the following is the most likely diagnosis?

A. Chancroid
B. Condyloma acuminatum
C. Cytomegalovirus infection
D. Gonorrhea
E. Granuloma inguinale
F. Molluscum contagiosum
G. Secondary syphilis
H. Squamous cell carcinoma

Submit

A 21-year-old man comes to the urgent care clinic with a lesion on his penis. He noted a painful ulcer on the right side of the penis 4 days ago and it has progressively increased in size since then. The patient has had no dysuria, hematuria, or penile discharge. He is a tourist visiting New York City from Botswana. He is HIV-positive and is sexually active. The patient currently takes no medications. He appears comfortable and is afebrile. On genitourinary examination, there is a 1.5-cm ulceration on the right side of the base of the penis; this lesion is very tender and soft; has irregular, ragged borders; and is covered with grey exudate. There is no penile discharge. There is a palpable, tender, enlarged inguinal lymph node in the right groin. The examination is otherwise unremarkable. A scraping of the ulcer is performed. Polymerase chain reaction testing for herpes simplex virus is negative, and darkfield microscopy reveals no organisms. Which of the following is the most likely diagnosis?

- ✓ A. Chancroid (60%)
- B. Condyloma acuminatum (5%)
- C. Cytomegalovirus infection (2%)
- D. Gonorrhea (2%)
- E. Granuloma inguinale (19%)
- F. Molluscum contagiosum (2%)
- G. Secondary syphilis (2%)
- H. Squamous cell carcinoma (4%)

Omitted
Correct answer
A

60%
Answered correctly

01 sec
Time Spent

03/15/2020
Last Updated

Explanation

1 2 3 4 5 6 7 8 9 10 11 12 13 14 15 16 17 18 19 20 21 22 23 24 25 26 27 28 29 30 31

Characteristics of ulcerative sexually transmitted diseases

Disease	Causative agent	Features of primary lesion	Initial lesion painful?
Chancroid	*Haemophilus ducreyi*	• Multiple & deep ulcers • Base may have gray to yellow exudate • Organisms often clump in long parallel strands ("school of fish")	**Yes**
Genital herpes	Herpes simplex virus 1 & 2	• **Multiple**, small, grouped ulcers • Shallow with erythematous base • Multinucleated giant cells & intranuclear inclusions (Cowdry type A)	**Yes**
Granuloma inguinale (donovanosis)	*Klebsiella granulomatis*	• Extensive & progressive ulcerative lesions without lymphadenopathy • Base may have granulation-like tissue • Deeply staining gram-negative intracytoplasmic cysts	No

Genital herpes	Herpes simplex virus 1 & 2	• Multiple, small, grouped ulcers • Shallow with erythematous base • Multinucleated giant cells & intranuclear inclusions (Cowdry type A)	**Yes**
Granuloma inguinale (donovanosis)	*Klebsiella granulomatis*	• Extensive & progressive ulcerative lesions without lymphadenopathy • Base may have granulation-like tissue • Deeply staining gram-negative intracytoplasmic cysts (Donovan bodies)	No
Syphilis	*Treponema pallidum*	• Single, indurated, well-circumscribed ulcer • Clean base • Thin, delicate, corkscrew-shaped organisms on dark-field microscopy	No
Lymphogranuloma venereum	*Chlamydia trachomatis*	• Small & shallow ulcers • Large, painful, coalesced inguinal lymph nodes ("buboes") • Intracytoplasmic chlamydial	No

		(Donovan bodies)	
Syphilis	*Treponema pallidum*	• Single, indurated, well-circumscribed ulcer • Clean base • Thin, delicate, corkscrew-shaped organisms on dark-field microscopy	No
Lymphogranuloma venereum	*Chlamydia trachomatis*	• Small & shallow ulcers • Large, painful, coalesced inguinal lymph nodes ("buboes") • Intracytoplasmic chlamydial inclusion bodies in epithelial cells & leukocytes	No

©UWorld

Chancroid is caused by ***Haemophilus ducreyi***, a gram-negative bacterium transmitted through sexual contact. It presents as one or more deep, **painful** ulcers (you "do cry" with *H ducreyi*) with **ragged borders** that are associated with a **grey exudate** and inguinal lymphadenopathy. On Gram stain, the organism appears as curved, gram-negative rods, often in a **clumping** pattern. The disease is relatively uncommon in the United States but has much higher prevalence in sub-Saharan Africa, Latin America, and regions of Asia.

(Choice B) Condyloma acuminata, or genital warts, are caused by the human papillomavirus. They present as skin-colored, white, or grey verrucous and filiform papules usually in the penile glans and shaft in men and the vulvovaginal and cervical areas in women.

(Choice C) In immunocompromised patients, manifestations of cytomegalovirus infection include febrile illness, pneumonitis, hepatitis, and retinitis, among others.

(Choice D) Gonorrhea and chlamydia most commonly present with dysuria and penile discharge, neither of which is present in this patient.

1
2
3
4
5
6
7
8
9
10
11
12
13
14
15
16
17
18
19
20
21
22
23
24
25
26
27
28
29
30
31

Chancroid is caused by ***Haemophilus ducreyi***, a gram-negative bacterium transmitted through sexual contact. It presents as one or more deep, **painful** ulcers (you "do cry" with *H ducreyi*) with **ragged borders** that are associated with a **grey exudate** and inguinal lymphadenopathy. On Gram stain, the organism appears as curved, gram-negative rods, often in a **clumping** pattern. The disease is relatively uncommon in the United States but has much higher prevalence in sub-Saharan Africa, Latin America, and regions of Asia.

(Choice B) Condyloma acuminata, or genital warts, are caused by the human papillomavirus. They present as skin-colored, white, or grey verrucous and filiform papules usually in the penile glans and shaft in men and the vulvovaginal and cervical areas in women.

(Choice C) In immunocompromised patients, manifestations of cytomegalovirus infection include febrile illness, pneumonitis, hepatitis, and retinitis, among others.

(Choice D) Gonorrhea and chlamydia most commonly present with dysuria and penile discharge, neither of which is present in this patient. Although it may be appropriate to perform testing for other sexually transmitted infections, gonorrhea would be an unlikely explanation for this patient's painful genital ulcer.

(Choice E) Granuloma inguinale is characterized by painless, extensive ulcerative lesions, typically without lymphadenopathy.

(Choice F) Molluscum contagiosum is a contagious disease caused by infection with a DNA poxvirus. Lesions are smooth, whitish or skin-colored, firm, somewhat pearly papules that measure about 2-6 mm and often have a central umbilication.

(Choice G) Primary syphilis commonly presents as a characteristically painless single genital ulcer called a chancre. The diagnosis is established by identification of the organisms on darkfield microscopy, serologic testing, or syphilis antibody testing. Secondary syphilis is often characterized by systemic symptoms, lymphadenopathy, grey mucous patches, raised grey genital papules (condylomata lata), and a diffuse rash involving the palms and soles.

(Choice H) Penile squamous cell cancer can present as lumps or ulcers, sometimes with adenopathy. However, the lesions are typically painless, and average age at presentation is 50.

Educational objective:
Chancroid, due to *Haemophilus ducreyi*, presents as deep, painful (you "do cry" with *H ducreyi*) ulcers with ragged borders that are associated with a grey exudate and inguinal lymphadenopathy. Diagnosis is established by Gram stain and culture of the organism from a scraping of the ulcer base.

1
2
3
4
5
6
7
8
9
10
11
12
13
14
15
16
17
18
19
20
21
22
23
24
25
26
27
28
29
30
31

(Choice D) Gonorrhea and chlamydia most commonly present with dysuria and penile discharge, neither of which is present in this patient. Although it may be appropriate to perform testing for other sexually transmitted infections, gonorrhea would be an unlikely explanation for this patient's painful genital ulcer.

(Choice E) Granuloma inguinale is characterized by painless, extensive ulcerative lesions, typically without lymphadenopathy.

(Choice F) Molluscum contagiosum is a contagious disease caused by infection with a DNA poxvirus. Lesions are smooth, whitish or skin-colored, firm, somewhat pearly papules that measure about 2-6 mm and often have a central umbilication.

(Choice G) Primary syphilis commonly presents as a characteristically painless single genital ulcer called a chancre. The diagnosis is established by identification of the organisms on darkfield microscopy, serologic testing, or syphilis antibody testing. Secondary syphilis is often characterized by systemic symptoms, lymphadenopathy, grey mucous patches, raised grey genital papules (condylomata lata), and a diffuse rash involving the palms and soles.

(Choice H) Penile squamous cell cancer can present as lumps or ulcers, sometimes with adenopathy. However, the lesions are typically painless, and average age at presentation is 50.

Educational objective:
Chancroid, due to *Haemophilus ducreyi*, presents as deep, painful (you "do cry" with *H ducreyi*) ulcers with ragged borders that are associated with a grey exudate and inguinal lymphadenopathy. Diagnosis is established by Gram stain and culture of the organism from a scraping of the ulcer base.

References

- Diagnosis and management of genital ulcers.
- Chancroid: clinical manifestations, diagnosis and management

Microbiology	Infectious Diseases	Chancroid
Subject	System	Topic

Copyright © UWorld. All rights reserved.

1
2
3
4
5
6
7
8
9
10
11
12
13
14
15
16
17
18
19
20
21
22
23
24
25
26
27
28
29
30
31

Thin, delicate, corkscrew-shaped organisms on

Exhibit Display

Zoom In | Zoom Out | Reset | Add To New Card | Existing Card

colored, firm, somewhat pearly papules that measure about 2-6 mm and often have a central umbilication.

dark-field microscopy

Exhibit Display

Zoom In | Zoom Out | Reset | Add To New Card | Existing Card

1
2
3
4
5
6
7
8
9
10
11
12
13
14
15
16
17
18
19
20
21
22
23
24
25
26
27
28
29
30
31

(Choice D) Gonorrhea and chlamydia most commonly present with dysuria and penile discharge, neither of which is present in this patient

Exhibit Display

Zoom In | Zoom Out | Reset | Add To New Card | Existing Card

1
2
3
4
5
6
7
8
9
10
11
12
13
14
15
16
17
18
19
20
21
22
23
24
25
26
27
28
29
30
31

A 30-year-old man is brought to the emergency department due to erratic behavior, progressive right-sided weakness, and difficulty walking for the last month. The patient was diagnosed with HIV several years ago and is not compliant with antiretroviral treatment. Physical examination shows a cachectic and disheveled man. Funduscopic examination shows no abnormalities. Motor strength in the right upper and lower extremities is decreased, and his gait is ataxic. Brain MRI reveals several discrete areas of demyelination in the subcortical and periventricular white matter with no surrounding edema or mass effect. CD4 cell count is 30/mm^3. Reactivation of which of the following pathogens is most likely responsible for this patient's current symptoms?

A. Cytomegalovirus
B. Epstein-Barr virus
C. Herpes simplex virus
D. JC virus
E. Measles virus
F. *Toxoplasma gondii*

Submit

1
2
3
4
5
6
7
8
9
10
11
12
13
14
15
16
17
18
19
20
21
22
23
24
25
26
27
28
29
30
31

A 30-year-old man is brought to the emergency department due to erratic behavior, progressive right-sided weakness, and difficulty walking for the last month. The patient was diagnosed with HIV several years ago and is not compliant with antiretroviral treatment. Physical examination shows a cachectic and disheveled man. Funduscopic examination shows no abnormalities. Motor strength in the right upper and lower extremities is decreased, and his gait is ataxic. Brain MRI reveals several discrete areas of demyelination in the subcortical and periventricular white matter with no surrounding edema or mass effect. CD4 cell count is 30/mm^3. Reactivation of which of the following pathogens is most likely responsible for this patient's current symptoms?

A. Cytomegalovirus (9%)
B. Epstein-Barr virus (2%)
C. Herpes simplex virus (5%)
✓ D. JC virus (73%)
E. Measles virus (1%)
F. *Toxoplasma gondii* (7%)

Omitted
Correct answer
D

73%
Answered correctly

02 secs
Time Spent

06/17/2020
Last Updated

Explanation

Progressive multifocal leukoencephalopathy	
	• JC virus reactivation

1
2
3
4
5
6
7
8
9
10
11
12
13
14
15
16
17
18
19
20
21
22
23
24
25
26
27
28
29
30
31

Progressive multifocal leukoencephalopathy	
Epidemiology	• JC virus reactivation • Severe immunosuppression (eg, untreated AIDS)
Manifestations	• Slowly progressive • Confusion, paresis, ataxia, seizure
Diagnosis	• MRI of the brain: asymmetric white matter lesions; no enhancement/edema • Lumbar puncture: CSF PCR positive for JC virus • Brain biopsy (rarely needed)
Treatment	• Often fatal • If HIV positive: antiretroviral therapy

CSF = cerebrospinal fluid; PCR = polymerase chain reaction.

JC virus is a polyomavirus, typically acquired in childhood, that causes life-long, latent infection of the kidney and lymphoid organs. Most adults have serologic evidence of exposure but remain asymptomatic. However, those with severe immunosuppression, particularly patients with **advanced AIDS**, are at risk for **viral reactivation** with spread to the brain. The virus attacks **oligodendrocytes**, the cells that produce myelin, causing a severe demyelinating disease called **progressive multifocal leukoencephalopathy** (PML).

PML typically presents with slowly worsening confusion, ataxia, motor deficits, and seizure. Brain MRI usually shows multifocal areas of white matter demyelination with **no mass effect or enhancement**. Diagnosis is confirmed with JC virus PCR testing of the cerebrospinal fluid; brain biopsy is rarely required. There is no specific treatment for PML, but patients with HIV who develop the disease are treated with antiretroviral therapy to reduce immune suppression. This often helps stabilize neurologic symptoms.

(Choice A) Patients with advanced AIDS can occasionally develop cytomegalovirus encephalitis, which usually presents with rapidly progressive altered mental state and focal neurologic deficits. However, this condition is highly inflammatory so brain imaging typically shows enhancing lesions.

CSF = cerebrospinal fluid; PCR = polymerase chain reaction.

JC virus is a polyomavirus, typically acquired in childhood, that causes life-long, latent infection of the kidney and lymphoid organs. Most adults have serologic evidence of exposure but remain asymptomatic. However, those with severe immunosuppression, particularly patients with **advanced AIDS**, are at risk for **viral reactivation** with spread to the brain. The virus attacks **oligodendrocytes**, the cells that produce myelin, causing a severe demyelinating disease called **progressive multifocal leukoencephalopathy** (PML).

PML typically presents with slowly worsening confusion, ataxia, motor deficits, and seizure. Brain MRI usually shows multifocal areas of white matter demyelination with **no mass effect or enhancement**. Diagnosis is confirmed with JC virus PCR testing of the cerebrospinal fluid; brain biopsy is rarely required. There is no specific treatment for PML, but patients with HIV who develop the disease are treated with antiretroviral therapy to reduce immune suppression. This often helps stabilize neurologic symptoms.

(Choice A) Patients with advanced AIDS can occasionally develop cytomegalovirus encephalitis, which usually presents with rapidly progressive altered mental state and focal neurologic deficits. However, this condition is highly inflammatory so brain imaging typically shows enhancing lesions.

(Choice B) Epstein-Barr virus reactivation can cause primary CNS lymphoma in patients with advanced AIDS. Patients usually have focal neurologic symptoms and altered mental state. However, brain MRI normally reveals a single enhancing lesion with mass effect.

(Choice C) Herpes simplex virus encephalitis usually causes focal neurologic deficits and altered mental status. However, symptom onset is usually rapid (<1 week), most patients have fever, and brain imaging usually reveals an enhancing temporal lobe lesion with mass effect.

(Choice E) Measles can cause subacute, sclerosing panencephalitis several years after initial infection. This fatal, progressive disease is characterized by slowly worsening neurologic symptoms and multifocal, enhancing, white matter lesions.

(Choice F) *Toxoplasma gondii* is usually acquired by exposure to cat feces. Most patients are asymptomatic and have a life-long dormant infection. However, patients with advanced AIDS can have reactivation leading to meningoencephalitis (eg, headache, confusion, fever). Brain imaging usually shows several ring-enhancing lesions with surrounding edema.

Educational objective:
Patients with advanced AIDS can have reactivation of JC virus, which causes progressive multifocal leukoencephalopathy. This condition usually presents with slowly progressive confusion, ataxia, and motor deficits. Brain MRI reveals multifocal areas of white matter demyelination with no

PML typically presents with slowly worsening confusion, ataxia, motor deficits, and seizure. Brain MRI usually shows multifocal areas of white matter demyelination with **no mass effect or enhancement**. Diagnosis is confirmed with JC virus PCR testing of the cerebrospinal fluid; brain biopsy is rarely required. There is no specific treatment for PML, but patients with HIV who develop the disease are treated with antiretroviral therapy to reduce immune suppression. This often helps stabilize neurologic symptoms.

(Choice A) Patients with advanced AIDS can occasionally develop cytomegalovirus encephalitis, which usually presents with rapidly progressive altered mental state and focal neurologic deficits. However, this condition is highly inflammatory so brain imaging typically shows enhancing lesions.

(Choice B) Epstein-Barr virus reactivation can cause primary CNS lymphoma in patients with advanced AIDS. Patients usually have focal neurologic symptoms and altered mental state. However, brain MRI normally reveals a single enhancing lesion with mass effect.

(Choice C) Herpes simplex virus encephalitis usually causes focal neurologic deficits and altered mental status. However, symptom onset is usually rapid (<1 week), most patients have fever, and brain imaging usually reveals an enhancing temporal lobe lesion with mass effect.

(Choice E) Measles can cause subacute, sclerosing panencephalitis several years after initial infection. This fatal, progressive disease is characterized by slowly worsening neurologic symptoms and multifocal, enhancing, white matter lesions.

(Choice F) *Toxoplasma gondii* is usually acquired by exposure to cat feces. Most patients are asymptomatic and have a life-long dormant infection. However, patients with advanced AIDS can have reactivation leading to meningoencephalitis (eg, headache, confusion, fever). Brain imaging usually shows several ring-enhancing lesions with surrounding edema.

Educational objective:
Patients with advanced AIDS can have reactivation of JC virus, which causes progressive multifocal leukoencephalopathy. This condition usually presents with slowly progressive confusion, ataxia, and motor deficits. Brain MRI reveals multifocal areas of white matter demyelination with no mass effect or enhancement.

Microbiology	Infectious Diseases	Progressive multifocal leukoencephalopathy
Subject	System	Topic

Copyright © UWorld. All rights reserved.

- Brain biopsy (rarely needed)

Exhibit Display

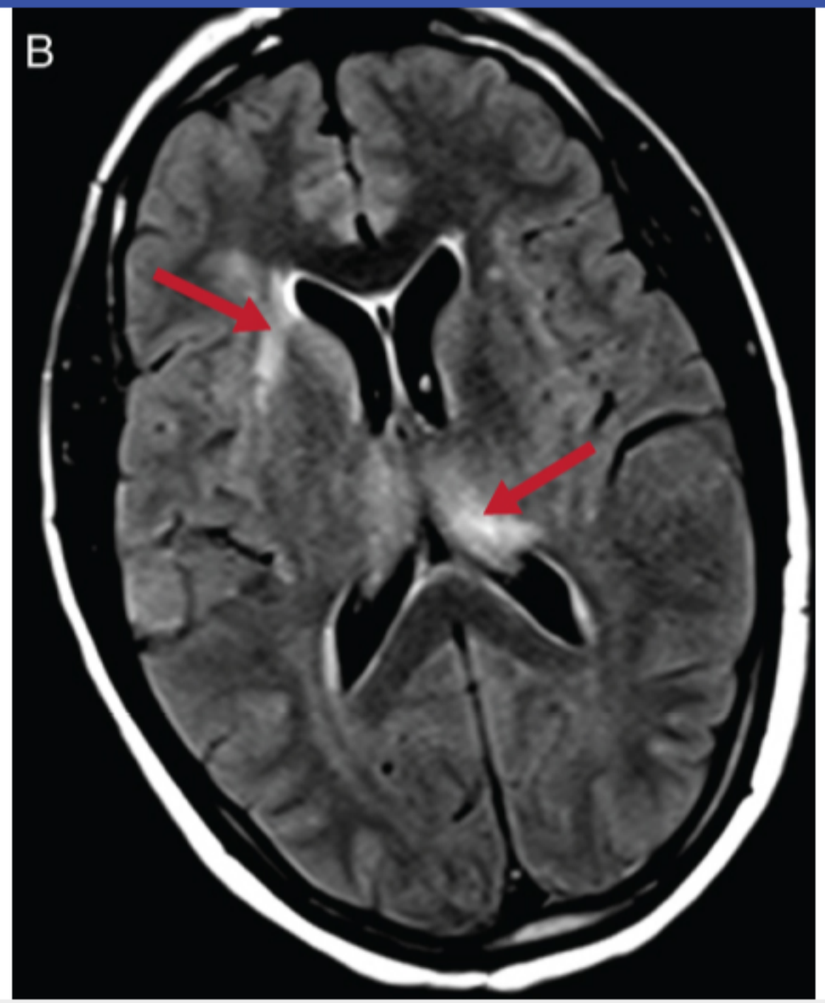

Zoom In | Zoom Out | Reset | Add To New Card | Existing Card

imaging usually shows several ring enhancing lesions with surrounding edema

- Brain biopsy (rarely needed)

Exhibit Display

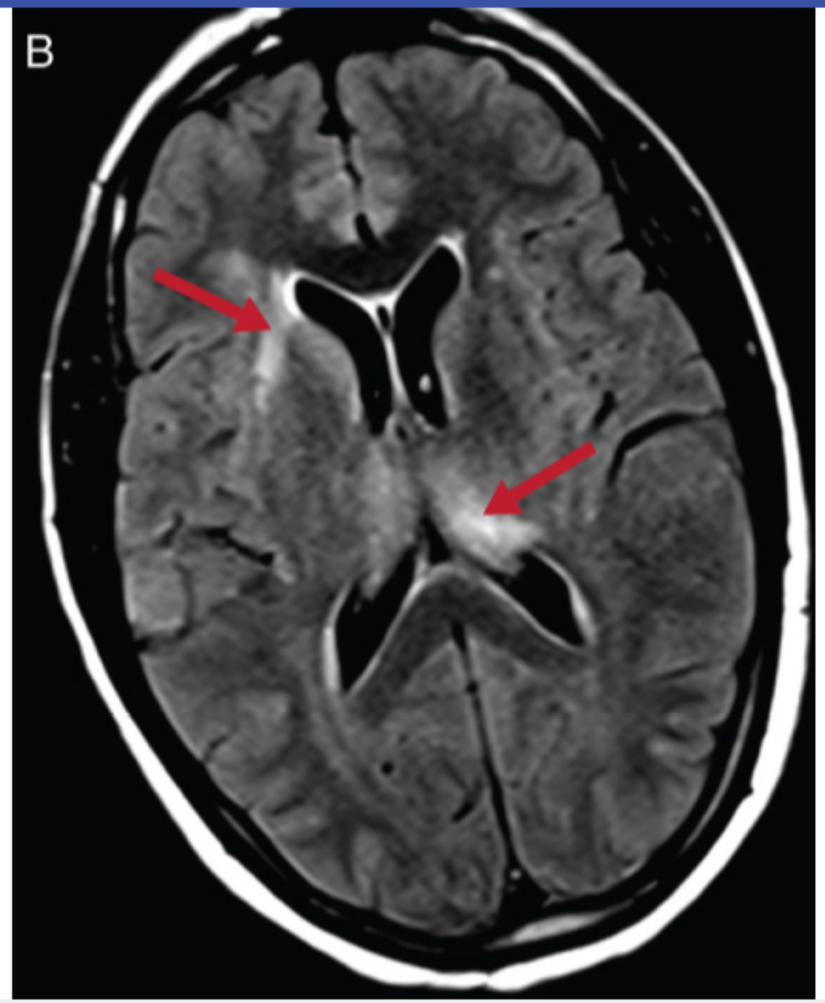

Zoom In | Zoom Out | Reset | Add To New Card | Existing Card

imaging usually shows several ring enhancing lesions with surrounding edema

PML typically presents with slowly worsening confusion, ataxia, motor deficits, and seizure. Brain MRI usually shows multifocal areas of white

Exhibit Display

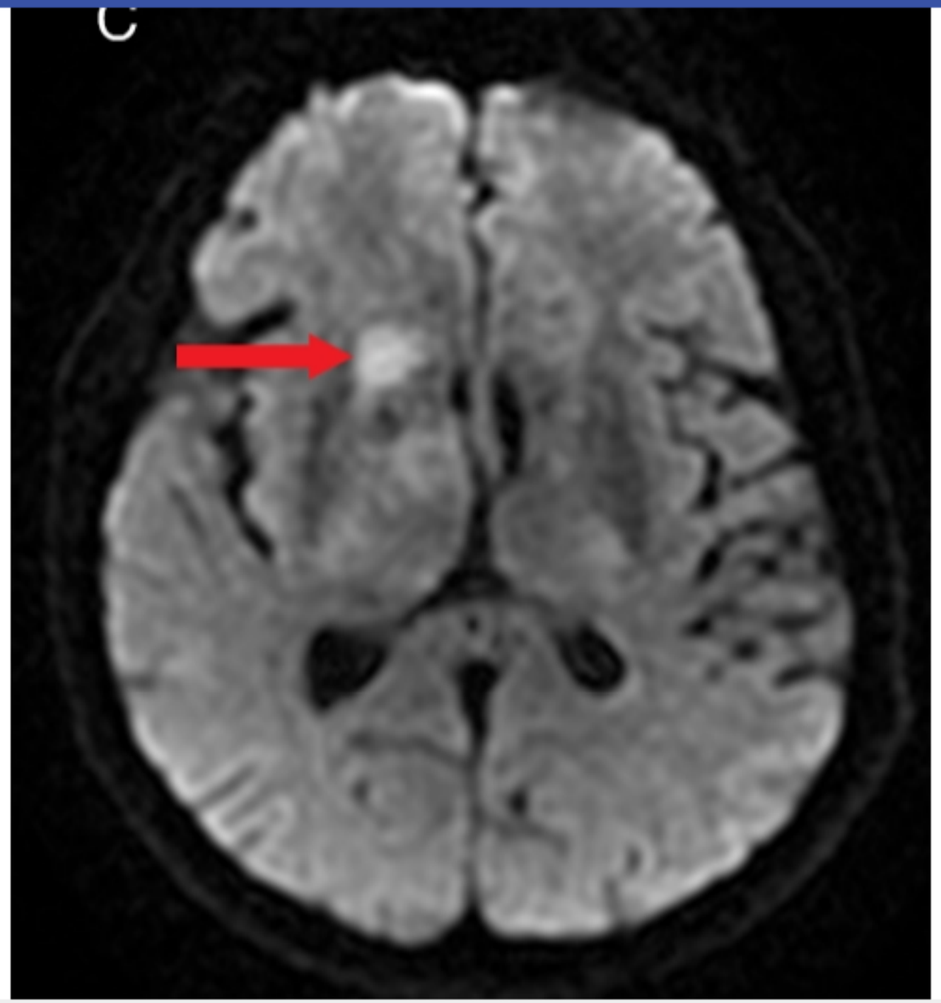

Zoom In | Zoom Out | Reset | Add To New Card | Existing Card

1
2
3
4
5
6
7
8
9
10
11
12
13
14
15
16
17
18
19
20
21
22
23
24
25
26
27
28
29
30
31

PML typically presents with slowly worsening confusion, ataxia, motor deficits, and seizure. Brain MRI usually shows multifocal areas of white

Exhibit Display

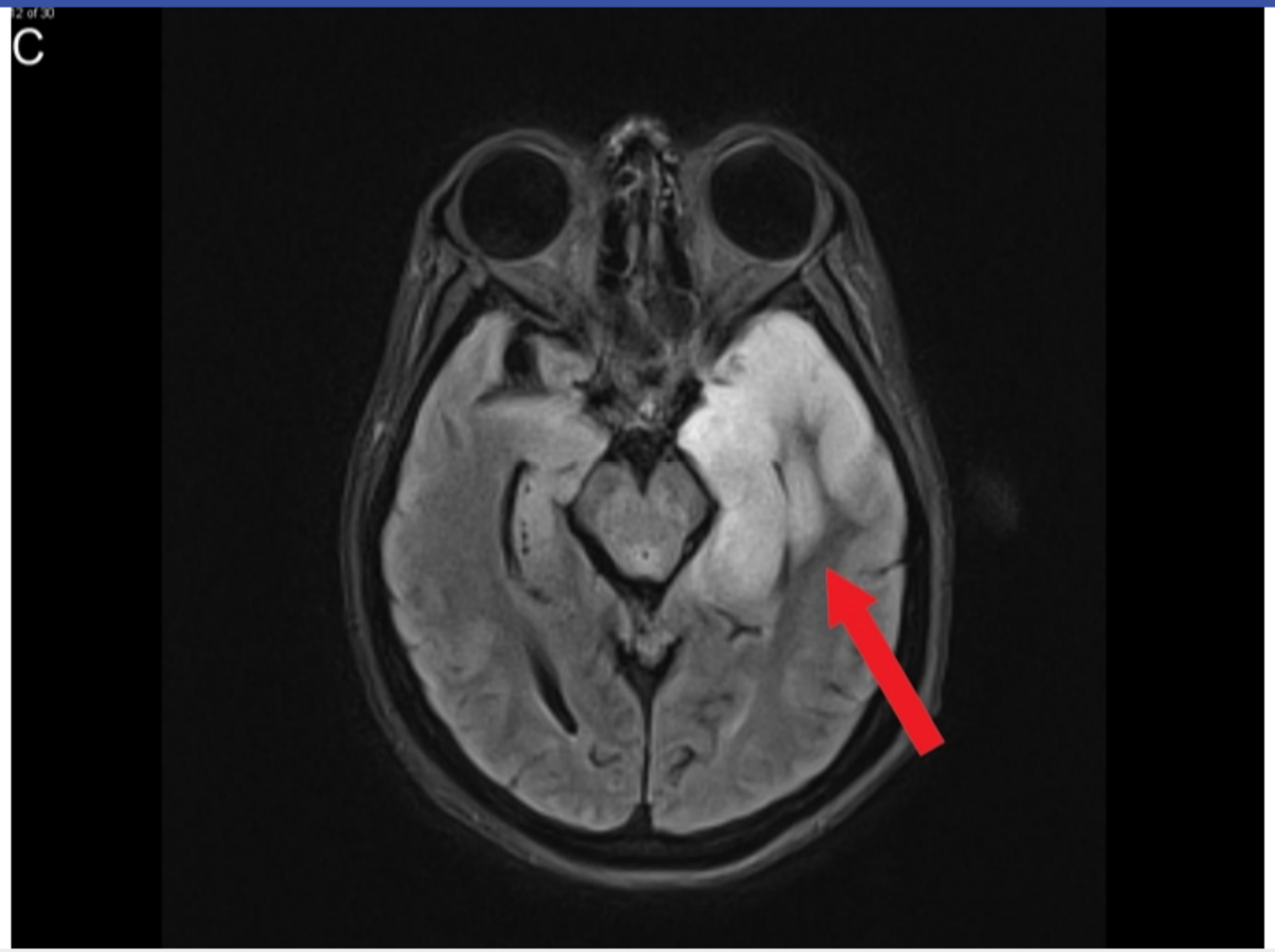

Zoom In | Zoom Out | Reset | Add To New Card | Existing Card

1
2
3
4
5
6
7
8
9
10
11
12
13
14
15
16
17
18
19
20
21
22
23
24
25
26
27
28
29
30
31

PML typically presents with slowly worsening confusion, ataxia, motor deficits, and seizure. Brain MRI usually shows multifocal areas of white

Exhibit Display

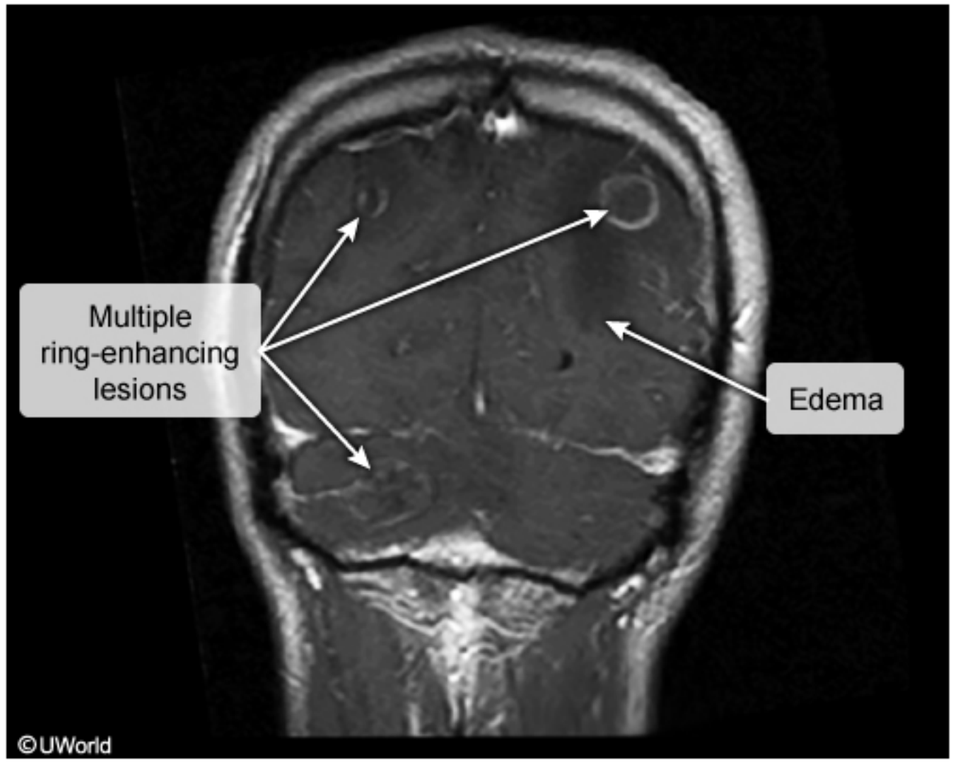

Zoom In | Zoom Out | Reset | Add To New Card | Existing Card

1
2
3
4
5
6
7
8
9
10
11
12
13
14
15
16
17
18
19
20
21
22
23
24
25
26
27
28
29
30
31

1
2
3
4
5
6
7
8
9
10
11
12
13
14
15
16
17
18
19
20
21
22
23
24
25
26
27
28
29
30
31

During the course of a week at an overnight summer camp, 4 children age 7-9 are sent to the camp health center. They each have fever, cough, congestion, sore throat, and red eyes. Physical examination of the children shows bilateral conjunctival injection and an erythematous oropharynx. Auscultation of one child also reveals crackles in the left lower lung field. All the children's symptoms improve over 7 days with supportive care. Which of the following is the most likely cause of the outbreak?

A. Adenovirus
B. Coxsackievirus
C. Influenza virus
D. Norovirus
E. Parvovirus
F. Respiratory syncytial virus

Submit

During the course of a week at an overnight summer camp, 4 children age 7-9 are sent to the camp health center. They each have fever, cough, congestion, sore throat, and red eyes. Physical examination of the children shows bilateral conjunctival injection and an erythematous oropharynx. Auscultation of one child also reveals crackles in the left lower lung field. All the children's symptoms improve over 7 days with supportive care. Which of the following is the most likely cause of the outbreak?

- ✓ A. Adenovirus (75%)
- B. Coxsackievirus (3%)
- C. Influenza virus (5%)
- D. Norovirus (2%)
- E. Parvovirus (1%)
- F. Respiratory syncytial virus (10%)

Omitted
Correct answer
A

75%
Answered correctly

02 secs
Time Spent

01/23/2020
Last Updated

Explanation

Adenovirus	
	• Double-stranded DNA • Transmission via direct contact

Adenovirus	
Epidemiology	• Double-stranded DNA • Transmission via direct contact, fecal-oral route, respiratory droplets • Occurs year-round
Clinical features	• Pharyngoconjunctival fever • Outbreaks in crowded quarters (eg, day care centers, camp dormitories, military barracks)

©UWorld

Adenovirus infection is a common, usually **self-limiting**, disease caused by a double-stranded DNA genome that is transmitted via direct contact, fecal-oral route, or respiratory droplets. Adenovirus infection occurs year-round and in **outbreaks** in crowded quarters (eg, day care centers, camp dormitories, military barracks).

Viral replication in epithelial cells can give rise to varying manifestations of disease based on serotype, with upper respiratory involvement as the most common. **Pharyngoconjunctival fever** is characterized by the **acute** onset of **fever, cough, congestion, pharyngitis,** and **conjunctivitis**. Physical examination usually reveals an erythematous oropharynx with bilateral, follicular conjunctival injection and serous discharge. Pneumonia occurs in a small percentage of patients, such as the child with focal crackles.

(Choice B) In young children, hand-foot-and-mouth disease is caused by coxsackievirus. Painful vesicles develop in the oropharynx and on the hands (eg, palms, dorsal fingers) and feet (eg, soles, sides). Coxsackievirus can also cause herpangina, an illness characterized by fever with posterior pharyngeal vesicles and without a rash.

(Choice C) Influenza viruses cause acute onset of high fever, cough, muscle aches, and malaise with a peak incidence during the winter. In

1
2
3
4
5
6
7
8
9
10
11
12
13
14
15
16
17
18
19
20
21
22
23
24
25
26
27
28
29
30
31

Adenovirus infection is a common, usually **self-limiting**, disease caused by a double-stranded DNA genome that is transmitted via direct contact, fecal-oral route, or respiratory droplets. Adenovirus infection occurs year-round and in **outbreaks** in crowded quarters (eg, day care centers, camp dormitories, military barracks).

Viral replication in epithelial cells can give rise to varying manifestations of disease based on serotype, with upper respiratory involvement as the most common. **Pharyngoconjunctival fever** is characterized by the **acute** onset of **fever, cough, congestion, pharyngitis,** and **conjunctivitis**. Physical examination usually reveals an erythematous oropharynx with bilateral, follicular conjunctival injection and serous discharge. Pneumonia occurs in a small percentage of patients, such as the child with focal crackles.

(Choice B) In young children, hand-foot-and-mouth disease is caused by coxsackievirus. Painful vesicles develop in the oropharynx and on the hands (eg, palms, dorsal fingers) and feet (eg, soles, sides). Coxsackievirus can also cause herpangina, an illness characterized by fever with posterior pharyngeal vesicles and without a rash.

(Choice C) Influenza viruses cause acute onset of high fever, cough, muscle aches, and malaise with a peak incidence during the winter. In children, infection can be complicated by febrile seizures, vomiting, acute otitis media, and pneumonia.

(Choice D) Norovirus causes rapid-onset, self-limiting gastroenteritis in outbreak settings (eg, restaurants, child care facilities, cruise ships). In addition to vomiting and diarrhea, fever, headache, and malaise are common.

(Choice E) Parvovirus B19 causes erythema infectiosum (fifth disease) in school-aged children and presents with fever, malaise, and a classic "slapped cheek" rash.

(Choice F) Respiratory syncytial virus (RSV) classically causes lower respiratory tract disease (eg, bronchiolitis, pneumonia) in infants. Although older children and adults can develop respiratory infection and outbreaks can occur in close quarters, RSV is a seasonal virus that peaks in the winter months.

Educational objective:
Adenovirus is a self-limiting, year-round infection that causes the acute onset of fever, cough, congestion, pharyngitis, and conjunctivitis. This pharyngoconjunctival disease can occur in outbreaks among those living in close quarters (eg, camp dormitories, military barracks).

References

- Adenovirus.

Physical examination usually reveals an erythematous oropharynx with bilateral, follicular conjunctival injection and serous discharge. Pneumonia occurs in a small percentage of patients, such as the child with focal crackles.

(Choice B) In young children, hand-foot-and-mouth disease is caused by coxsackievirus. Painful vesicles develop in the oropharynx and on the hands (eg, palms, dorsal fingers) and feet (eg, soles, sides). Coxsackievirus can also cause herpangina, an illness characterized by fever with posterior pharyngeal vesicles and without a rash.

(Choice C) Influenza viruses cause acute onset of high fever, cough, muscle aches, and malaise with a peak incidence during the winter. In children, infection can be complicated by febrile seizures, vomiting, acute otitis media, and pneumonia.

(Choice D) Norovirus causes rapid-onset, self-limiting gastroenteritis in outbreak settings (eg, restaurants, child care facilities, cruise ships). In addition to vomiting and diarrhea, fever, headache, and malaise are common.

(Choice E) Parvovirus B19 causes erythema infectiosum (fifth disease) in school-aged children and presents with fever, malaise, and a classic "slapped cheek" rash.

(Choice F) Respiratory syncytial virus (RSV) classically causes lower respiratory tract disease (eg, bronchiolitis, pneumonia) in infants. Although older children and adults can develop respiratory infection and outbreaks can occur in close quarters, RSV is a seasonal virus that peaks in the winter months.

Educational objective:
Adenovirus is a self-limiting, year-round infection that causes the acute onset of fever, cough, congestion, pharyngitis, and conjunctivitis. This pharyngoconjunctival disease can occur in outbreaks among those living in close quarters (eg, camp dormitories, military barracks).

References

- Adenovirus.

Microbiology	Infectious Diseases	Upper respiratory tract infections
Subject	System	Topic

Copyright © UWorld. All rights reserved.

1
2
3
4
5
6
7
8
9
10
11
12
13
14
15
16
17
18
19
20
21
22
23
24
25
26
27
28
29
30
31

Exhibit Display

Zoom In | Zoom Out | Reset | Add To New Card | Existing Card

older children and adults can develop respiratory infection and outbreaks can occur in close quarters; RSV is a seasonal virus that peaks in the

1
2
3
4
5
6
7
8
9
10
11
12
13
14
15
16
17
18
19
20
21
22
23
24
25
26
27
28
29
30
31

Exhibit Display

Zoom In | Zoom Out | Reset | Add To New Card | Existing Card

older children and adults can develop respiratory infection and outbreaks can occur in close quarters; RSV is a seasonal virus that peaks in the

Physical examination usually reveals an erythematous oropharynx with bilateral follicular conjunctival injection and serous discharge. Pneumonia

Exhibit Display

Zoom In | Zoom Out | Reset | Add To New Card | Existing Card

1
2
3
4
5
6
7
8
9
10
11
12
13
14
15
16
17
18
19
20
21
22
23
24
25
26
27
28
29
30
31

1
2
3
4
5
6
7
8
9
10
11
12
13
14
15
16
17
18
19
20
21
22
23
24
25
26
27
28
29
30
31

A scientist is conducting research to discover novel drug targets for antiretroviral agents against HIV. An HIV-positive blood sample is analyzed in the laboratory, and purified CD4 T lymphocytes are extracted. Using molecular tracing techniques, the scientist follows a viral HIV protein that is synthesized in the blood sample's T cells. The protein becomes glycosylated before being proteolytically cleaved into 2 smaller proteins in the Golgi apparatus. Which of the following best describes the function of these 2 newly formed HIV proteins?

A. Viral DNA integration into the host genome

B. Viral DNA synthesis from RNA template

C. Viral polyprotein cleavage

D. Virion attachment to the target cells

E. Virus-induced cell apoptosis

Submit

1
2
3
4
5
6
7
8
9
10
11
12
13
14
15
16
17
18
19
20
21
22
23
24
25
26
27
28
29
30
31

A scientist is conducting research to discover novel drug targets for antiretroviral agents against HIV. An HIV-positive blood sample is analyzed in the laboratory, and purified CD4 T lymphocytes are extracted. Using molecular tracing techniques, the scientist follows a viral HIV protein that is synthesized in the blood sample's T cells. The protein becomes glycosylated before being proteolytically cleaved into 2 smaller proteins in the Golgi apparatus. Which of the following best describes the function of these 2 newly formed HIV proteins?

A. Viral DNA integration into the host genome (10%)

B. Viral DNA synthesis from RNA template (12%)

C. Viral polyprotein cleavage (12%)

✓ D. Virion attachment to the target cells (61%)

E. Virus-induced cell apoptosis (3%)

Omitted
Correct answer
D

61%
Answered correctly

02 secs
Time Spent

05/25/2020
Last Updated

Explanation



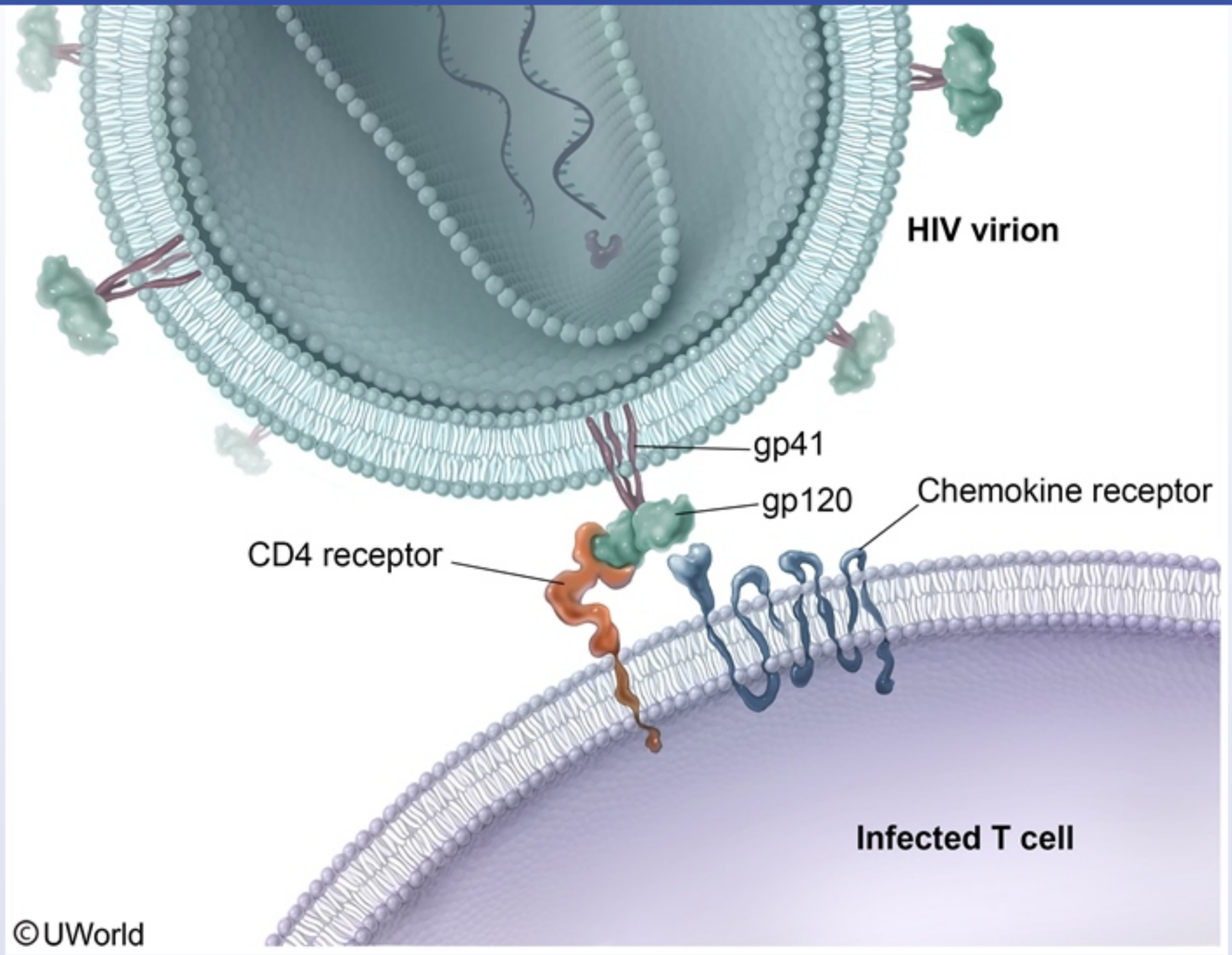

The HIV genome contains a set of structural genes (*gag*, *pol*, and *env*) that encode **polyproteins**. These polyproteins are subsequently cleaved by host or viral proteases into the individual proteins that compose the HIV virus.

The only **glycosylated** HIV polyprotein is **gp160**, the product of the *env* gene. gp160 is extensively glycosylated in the rough endoplasmic

©UWorld

The HIV genome contains a set of structural genes (*gag*, *pol*, and *env*) that encode **polyproteins**. These polyproteins are subsequently cleaved by host or viral proteases into the individual proteins that compose the HIV virus.

The only **glycosylated** HIV polyprotein is **gp160**, the product of the *env* gene. gp160 is extensively glycosylated in the rough endoplasmic reticulum and Golgi apparatus. It is then cleaved into the envelope proteins **gp120**, which mediates viral attachment, and **gp41**, which mediates viral fusion with the host cell. Glycosylation of these proteins is crucial for:

- **Immune evasion** – Glycosylation acts as a shield for the conserved regions of these surface proteins, masking them from immune recognition.
- **Host cell binding**
- Proper protein folding

(Choices A, B, and C) The *pol* gene encodes for reverse transcriptase, integrase, and protease, three crucial HIV enzymes. Reverse transcriptase converts single-stranded viral RNA into double-stranded DNA, which is then integrated into the host genome by integrase. Protease helps cleave HIV polyproteins into individual proteins after transcription in the rough endoplasmic reticulum. These enzymes are not glycosylated.

(Choice E) Uninfected CD4 cells can undergo activation-induced apoptosis when responding to HIV peptides displayed on the surface of infected cells. CD4 cells infected with HIV are damaged primarily through direct cytopathic effects. Both mechanisms contribute to CD4 cell depletion in HIV infection.

Educational objective:
In the HIV replication cycle, polyprotein precursors are encoded by the structural genes *gag*, *pol*, and *env*. Only the *env* gene polyprotein product (gp160) is glycosylated. This polyprotein is subsequently cleaved in the Golgi apparatus to form the envelope glycoproteins gp120 and gp41.

References

- HIV-1 envelope glycoprotein biosynthesis, trafficking, and incorporation

Microbiology	Infectious Diseases	HIV
Subject	System	Topic

The HIV genome contains a set of structural genes (*gag*, *pol*, and *env*) that encode **polyproteins**. These polyproteins are subsequently cleaved by host or viral proteases into the individual proteins that compose the HIV virus.

The only **glycosylated** HIV polyprotein is **gp160**, the product of the *env* gene. gp160 is extensively glycosylated in the rough endoplasmic reticulum and Golgi apparatus. It is then cleaved into the envelope proteins **gp120**, which mediates viral attachment, and **gp41**, which mediates viral fusion with the host cell. Glycosylation of these proteins is crucial for:

- **Immune evasion** – Glycosylation acts as a shield for the conserved regions of these surface proteins, masking them from immune recognition.
- **Host cell binding**
- Proper protein folding

(Choices A, B, and C) The *pol* gene encodes for reverse transcriptase, integrase, and protease, three crucial HIV enzymes. Reverse transcriptase converts single-stranded viral RNA into double-stranded DNA, which is then integrated into the host genome by integrase. Protease helps cleave HIV polyproteins into individual proteins after transcription in the rough endoplasmic reticulum. These enzymes are not glycosylated.

(Choice E) Uninfected CD4 cells can undergo activation-induced apoptosis when responding to HIV peptides displayed on the surface of infected cells. CD4 cells infected with HIV are damaged primarily through direct cytopathic effects. Both mechanisms contribute to CD4 cell depletion in HIV infection.

Educational objective:
In the HIV replication cycle, polyprotein precursors are encoded by the structural genes *gag*, *pol*, and *env*. Only the *env* gene polyprotein product (gp160) is glycosylated. This polyprotein is subsequently cleaved in the Golgi apparatus to form the envelope glycoproteins gp120 and gp41.

References

- HIV-1 envelope glycoprotein biosynthesis, trafficking, and incorporation

Microbiology	Infectious Diseases	HIV
Subject	System	Topic

Copyright © UWorld. All rights reserved.

1
2
3
4
5
6
7
8
9
10
11
12
13
14
15
16
17
18
19
20
21
22
23
24
25
26
27
28
29
30
31

A 2-month-old girl is brought to the clinic due to perinatal hepatitis B exposure. Her mother is age 22 and immigrated to the United States shortly after giving birth. The pregnancy was complicated by maternal hepatitis B infection. However, the mother received no prenatal or perinatal care and was not diagnosed with chronic hepatitis B until the immigration process. Maternal HBsAg, HBeAg, and anti-HBc are all positive; anti-HBs is negative. The infant has not been evaluated previously and has not received any immunizations or other medications. She is exclusively breast fed and has been growing normally. Vital signs are normal and physical examination is unremarkable. No hepatomegaly or jaundice is seen. The infant's laboratory results will most likely show which of the following?

A. Antibody against HBsAg (anti-HBs)

B. HBeAg

C. Markedly elevated direct bilirubin

D. Markedly elevated liver function tests

E. Neither HBsAg nor anti-HBs

Submit

A 2-month-old girl is brought to the clinic due to perinatal hepatitis B exposure. Her mother is age 22 and immigrated to the United States shortly after giving birth. The pregnancy was complicated by maternal hepatitis B infection. However, the mother received no prenatal or perinatal care and was not diagnosed with chronic hepatitis B until the immigration process. Maternal HBsAg, HBeAg, and anti-HBc are all positive; anti-HBs is negative. The infant has not been evaluated previously and has not received any immunizations or other medications. She is exclusively breast fed and has been growing normally. Vital signs are normal and physical examination is unremarkable. No hepatomegaly or jaundice is seen. The infant's laboratory results will most likely show which of the following?

- A. Antibody against HBsAg (anti-HBs) (15%)
- ✓ B. HBeAg (43%)
- C. Markedly elevated direct bilirubin (0%)
- D. Markedly elevated liver function tests (7%)
- E. Neither HBsAg nor anti-HBs (33%)

Omitted
Correct answer
B

43%
Answered correctly

02 secs
Time Spent

04/03/2020
Last Updated

Explanation

Perinatal hepatitis B infection	
Risk factors	• Maternal viral load • Maternal HBeAg positive

Perinatal hepatitis B infection	
Risk factors	• Maternal viral load • Maternal HBeAg positive
Clinical findings	• Infants usually immune-tolerant (normal or mildly elevated liver enzymes, no symptoms) • High risk for chronic infection • High viral load & HBeAg positive
Prevention	• Maternal antiviral therapy in some cases • Newborn hepatitis B vaccination & immunoglobulin within 12 hours • Routine immunization • Serology ~3 months after 3rd dose of vaccine

This infant was exposed to hepatitis B virus (HBV) during delivery. Mother-to-child transmission most commonly occurs during **delivery**, but transplacental infection can also occur. Maternal **viral load** and **HBeAg** status are the strongest risk factors for infant infection. Infants born to HBeAg-positive women (as in this case) have a >90% chance of acquiring infection, whereas the chance is less in infants born to HBeAg-negative women.

Viral replication occurs rapidly in infected infants due to immune system immaturity in newborns. As a result, infected infants have high viral loads and HBeAg levels. Despite this high level of replication, infants enter an **immune-tolerant** phase of chronic HBV infection in which they are asymptomatic and have normal or only mildly elevated liver function tests. Over time, chronically infected newborns are at high risk of progression to **cirrhosis** and **hepatocellular carcinoma**. The chance of progression to chronic hepatitis B is 90% without treatment, much higher than the chance of progression in older children and adults. Administration of **hepatitis B vaccine** and **immunoglobulin** as soon as possible after delivery can prevent chronic infection.

(Choice A) Due to their immature immune system, more than 90% of vertically infected infants develop chronic infection (eg, they do not develop anti-HBs and do not clear their HBV infection). Additionally, the infant's mother has chronic disease and lacks anti-HBs, meaning there would be

1
2
3
4
5
6
7
8
9
10
11
12
13
14
15
16
17
18
19
20
21
22
23
24
25
26
27
28
29
30
31

This infant was exposed to hepatitis B virus (HBV) during delivery. Mother-to-child transmission most commonly occurs during **delivery**, but transplacental infection can also occur. Maternal **viral load** and **HBeAg** status are the strongest risk factors for infant infection. Infants born to HBeAg-positive women (as in this case) have a >90% chance of acquiring infection, whereas the chance is less in infants born to HBeAg-negative women.

Viral replication occurs rapidly in infected infants due to immune system immaturity in newborns. As a result, infected infants have high viral loads and HBeAg levels. Despite this high level of replication, infants enter an **immune-tolerant** phase of chronic HBV infection in which they are asymptomatic and have normal or only mildly elevated liver function tests. Over time, chronically infected newborns are at high risk of progression to **cirrhosis** and **hepatocellular carcinoma**. The chance of progression to chronic hepatitis B is 90% without treatment, much higher than the chance of progression in older children and adults. Administration of **hepatitis B vaccine** and **immunoglobulin** as soon as possible after delivery can prevent chronic infection.

(Choice A) Due to their immature immune system, more than 90% of vertically infected infants develop chronic infection (eg, they do not develop anti-HBs and do not clear their HBV infection). Additionally, the infant's mother has chronic disease and lacks anti-HBs, meaning there would be no maternally derived transplacental antibodies. Therefore, anti-HBs would not be expected in this infant.

(Choices C and D) Hepatic injury from hepatitis B is due to the cellular immune response, not by the virus itself. Therefore, infants with HBV infection enter an immune-tolerant phase due to their immature T-cell responses, which limits hepatocyte damage. As a result, laboratory markers of liver injury (eg, liver function tests, direct bilirubinemia) are usually normal or only mildly elevated in HBV-infected neonates.

(Choice E) Perinatally infected infants have rapid appearance of HBsAg within a few days; absence of both HBsAg and anti-HBs at age 2 months would suggest that the infant was not infected. However, this is unlikely as virtually all infants born to HBeAg-positive mothers will be infected perinatally.

Educational objective:
Infants born to HBeAg-positive mothers have a high risk of acquiring perinatal hepatitis B virus (HBV) infection. Infected neonates have high levels of HBV replication and are at high risk for chronic infection, but are usually asymptomatic or have only mildly elevated liver function tests.

References

- Prevention of neonatal hepatitis B virus transmission.

and HBeAg levels. Despite this high level of replication, infants enter an **immune-tolerant** phase of chronic HBV infection in which they are asymptomatic and have normal or only mildly elevated liver function tests. Over time, chronically infected newborns are at high risk of progression to **cirrhosis** and **hepatocellular carcinoma**. The chance of progression to chronic hepatitis B is 90% without treatment, much higher than the chance of progression in older children and adults. Administration of **hepatitis B vaccine** and **immunoglobulin** as soon as possible after delivery can prevent chronic infection.

(Choice A) Due to their immature immune system, more than 90% of vertically infected infants develop chronic infection (eg, they do not develop anti-HBs and do not clear their HBV infection). Additionally, the infant's mother has chronic disease and lacks anti-HBs, meaning there would be no maternally derived transplacental antibodies. Therefore, anti-HBs would not be expected in this infant.

(Choices C and D) Hepatic injury from hepatitis B is due to the cellular immune response, not by the virus itself. Therefore, infants with HBV infection enter an immune-tolerant phase due to their immature T-cell responses, which limits hepatocyte damage. As a result, laboratory markers of liver injury (eg, liver function tests, direct bilirubinemia) are usually normal or only mildly elevated in HBV-infected neonates.

(Choice E) Perinatally infected infants have rapid appearance of HBsAg within a few days; absence of both HBsAg and anti-HBs at age 2 months would suggest that the infant was not infected. However, this is unlikely as virtually all infants born to HBeAg-positive mothers will be infected perinatally.

Educational objective:
Infants born to HBeAg-positive mothers have a high risk of acquiring perinatal hepatitis B virus (HBV) infection. Infected neonates have high levels of HBV replication and are at high risk for chronic infection, but are usually asymptomatic or have only mildly elevated liver function tests.

References

- Prevention of neonatal hepatitis B virus transmission.
- Natural history of hepatitis B virus infection in children.

Microbiology	Infectious Diseases	Hepatitis b
Subject	System	Topic

Copyright © UWorld. All rights reserved.

1
2
3
4
5
6
7
8
9
10
11
12
13
14
15
16
17
18
19
20
21
22
23
24
25
26
27
28
29
30
31

A 22-year-old woman participates in a research study. She is asymptomatic and has not had a respiratory illness in the last 8 weeks. She reports no chronic medical problems and takes no medications. A nasopharyngeal specimen is obtained and cultured on a selective medium containing vancomycin, colistin, nystatin, and trimethoprim. The organism most likely to be isolated is typically associated with which of the following conditions?

- A. Cystitis
- B. Dental caries
- C. Diphtheria
- D. Meningitis
- E. Otitis media
- F. Pneumonia
- G. Rheumatic heart disease

Submit

1
2
3
4
5
6
7
8
9
10
11
12
13
14
15
16
17
18
19
20
21
22
23
24
25
26
27
28
29
30
31

A 22-year-old woman participates in a research study. She is asymptomatic and has not had a respiratory illness in the last 8 weeks. She reports no chronic medical problems and takes no medications. A nasopharyngeal specimen is obtained and cultured on a selective medium containing vancomycin, colistin, nystatin, and trimethoprim. The organism most likely to be isolated is typically associated with which of the following conditions?

A. Cystitis (7%)
B. Dental caries (7%)
C. Diphtheria (4%)
✓ D. Meningitis (57%)
E. Otitis media (6%)
F. Pneumonia (12%)
G. Rheumatic heart disease (4%)

Omitted
Correct answer
D

57%
Answered correctly

02 secs
Time Spent

02/14/2020
Last Updated

Explanation

The nasopharynx is colonized with a wide range of gram-positive and gram-negative bacteria. Therefore, nasopharyngeal swabs are often cultured on media containing antibiotics to isolate a specific organism. The agar described in this case is the **Thayer-Martin medium**, used to identify pathogenic ***Neisseria* organisms** such as *N meningitidis* (a common cause of **meningitis**) and *N gonorrhoeae* (a common cause of

1
2
3
4
5
6
7
8
9
10
11
12
13
14
15
16
17
18
19
20
21
22
23
24
25
26
27
28
29
30
31

The nasopharynx is colonized with a wide range of gram-positive and gram-negative bacteria. Therefore, nasopharyngeal swabs are often cultured on media containing antibiotics to isolate a specific organism. The agar described in this case is the **Thayer-Martin medium**, used to identify pathogenic ***Neisseria* organisms** such as *N meningitidis* (a common cause of **meningitis**) and *N gonorrhoeae* (a common cause of urethritis). The Thayer-Martin medium is a chocolate sheep blood agar infused with vancomycin to inhibit gram-positive bacteria; with colistin and trimethoprim to inhibit gram-negative bacteria (other than pathogenic *Neisseria* species); and with nystatin to inhibit yeast.

(Choice A) The most common cause of cystitis is *Escherichia coli*, a gram-negative rod inhibited by colistin and trimethoprim. *E coli* is not a common nasopharyngeal organism.

(Choice B) Dental carries are caused primarily by *Streptococcus* (eg, *S mutans*) and *Lactobacillus* species, gram-positive organisms inhibited by vancomycin.

(Choice C) *Corynebacterium diphtheriae* is the cause of diphtheria. It usually presents with slow-onset sore throat, malaise, and low-grade fever. *C diphtheriae* is a gram-positive organism inhibited by vancomycin.

(Choices E and F) The most common cause of both otitis media and community-acquired pneumonia in adults is *Streptococcus pneumoniae*. Although *S pneumoniae* can colonize the nasopharynx, this gram-positive organism is inhibited by vancomycin.

(Choice G) Rheumatic heart disease is caused by *Streptococcus pyogenes* (group A streptococci), a common gram-positive pharyngeal pathogen. *S pyogenes* is inhibited by vancomycin.

Educational objective:
The Thayer-Martin medium is used to isolate pathogenic *Neisseria* species such as *N meningitidis* and *N gonorrhoeae*. It is a chocolate sheep blood agar that contains vancomycin to inhibit the growth of gram-positive organisms; colistin and trimethoprim to inhibit gram-negative bacteria (other than pathogenic *Neisseria*); and nystatin to inhibit yeasts.

References

- Cellular and molecular biology of Neisseria meningitidis colonization and invasive disease.

Microbiology	Infectious Diseases	Meningococci
Subject	System	Topic

1
2
3
4
5
6
7
8
9
10
11
12
13
14
15
16
17
18
19
20
21
22
23
24
25
26
27
28
29
30
31

A virologist is researching acyclovir-resistant herpes simplex virus (HSV). Viral DNA analysis reveals a mutation in the thymidine kinase gene, resulting in a mutated enzyme that does not phosphorylate acyclovir to its active form. In an experiment, a resistant HSV type 2 strain containing this mutation is cultured in a cell line, and the cell culture is coinfected with a nonresistant HSV type 1 strain. It is found that some of the newly produced type 1 virions acquire resistance to acyclovir, and subsequent progeny continue to be resistant. Which of the following mechanisms best explains the observed findings?

A. Interference

B. Phenotypic mixing

C. Reassortment

D. Recombination

E. Transformation

Submit

A virologist is researching acyclovir-resistant herpes simplex virus (HSV). Viral DNA analysis reveals a mutation in the thymidine kinase gene, resulting in a mutated enzyme that does not phosphorylate acyclovir to its active form. In an experiment, a resistant HSV type 2 strain containing this mutation is cultured in a cell line, and the cell culture is coinfected with a nonresistant HSV type 1 strain. It is found that some of the newly produced type 1 virions acquire resistance to acyclovir, and subsequent progeny continue to be resistant. Which of the following mechanisms best explains the observed findings?

- A. Interference (0%)
- B. Phenotypic mixing (9%)
- C. Reassortment (21%)
- ✓ D. Recombination (40%)
- E. Transformation (28%)

Omitted
Correct answer
D

40%
Answered correctly

01 sec
Time Spent

02/27/2020
Last Updated

Explanation

Recombination

Virus A Virus B

1
2
3
4
5
6
7
8
9
10
11
12
13
14
15
16
17
18
19
20
21
22
23
24
25
26
27
28
29
30
31

Recombination

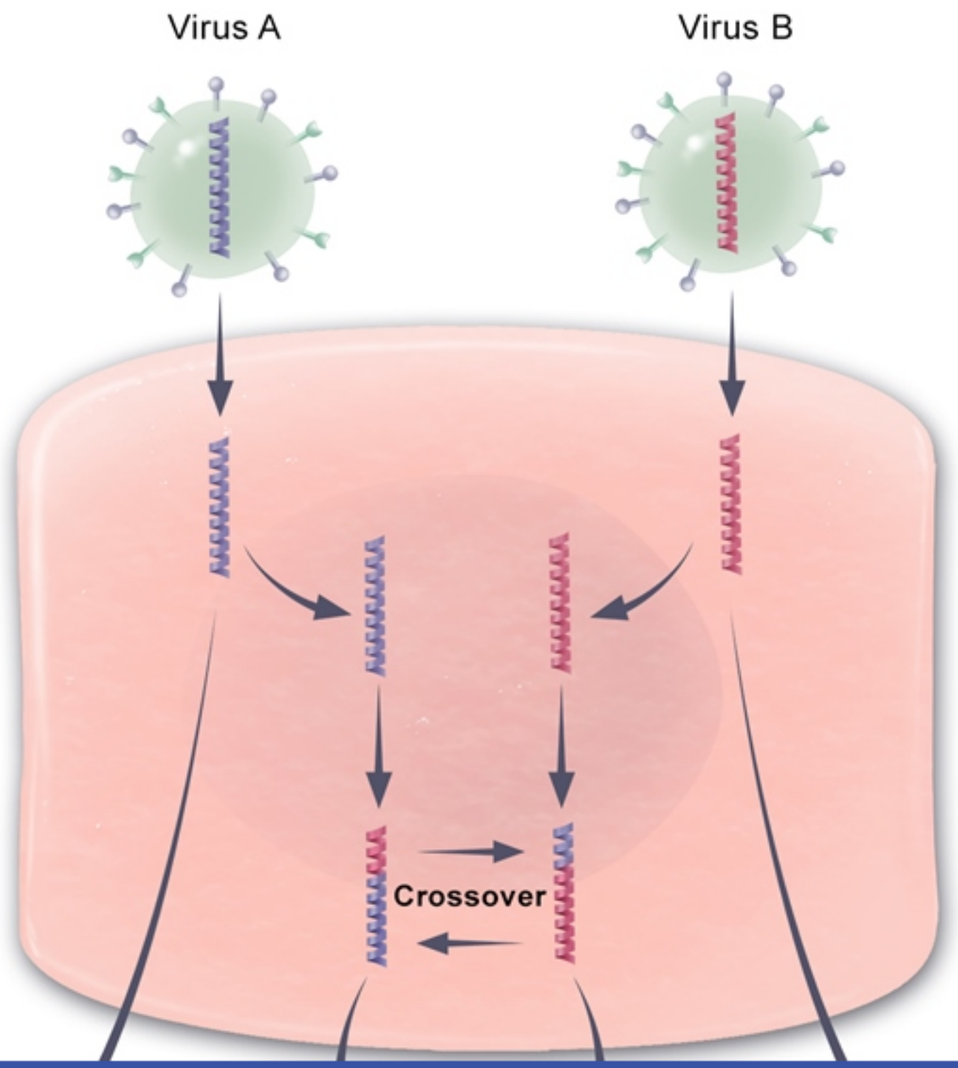

1
2
3
4
5
6
7
8
9
10
11
12
13
14
15
16
17
18
19
20
21
22
23
24
25
26
27
28
29
30
31

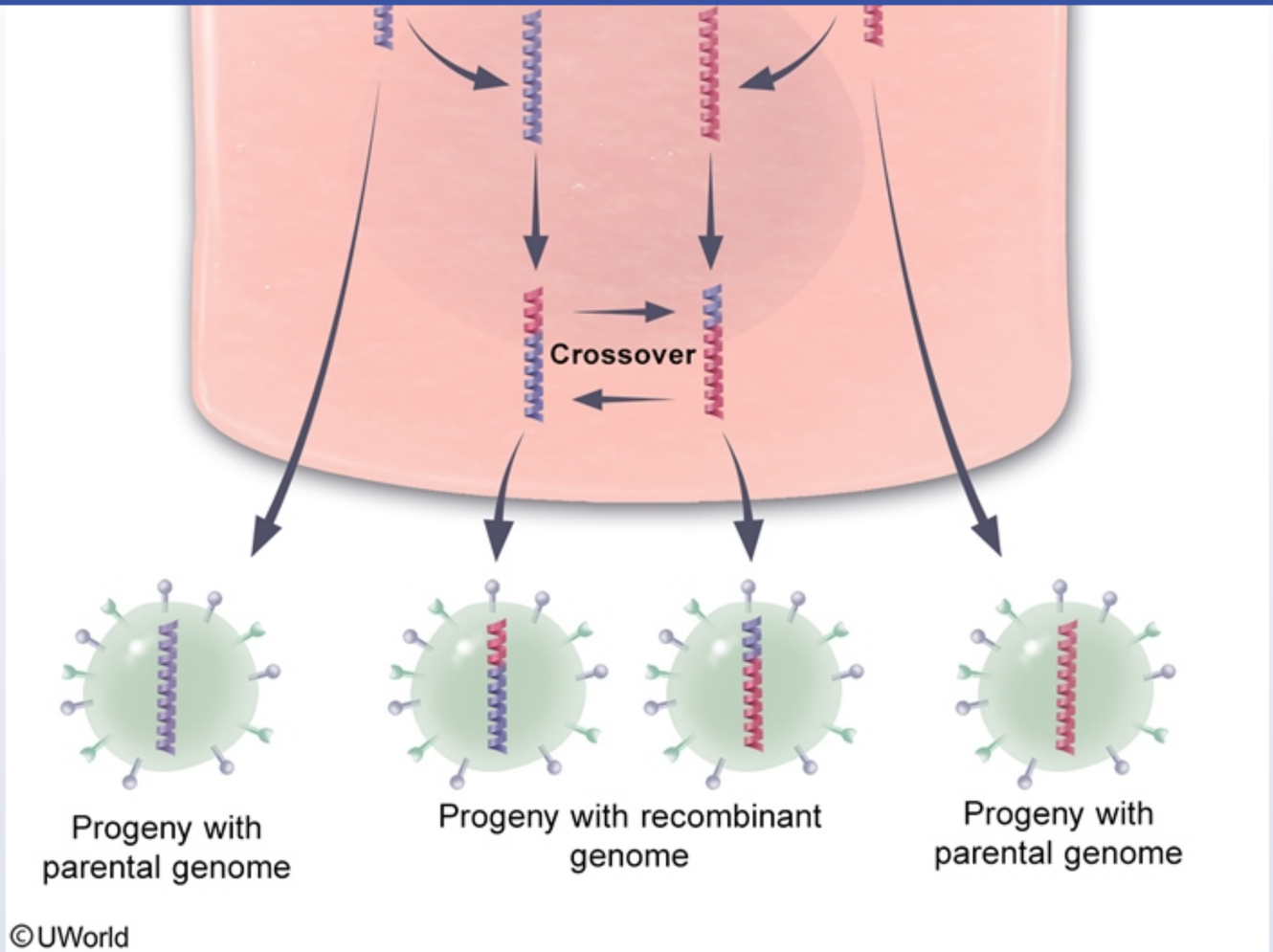

This scenario describes the exchange of genetic information between 2 virus strains that have **nonsegmented, double-stranded** DNA genomes. **Recombination** refers to the exchange of genes between 2 chromosomes via **crossing over** within homologous regions. The resulting progeny can have recombined genomes with traits from both parent viruses. In this case, the thymidine kinase genes in HSV type 1 and 2 virions are likely to have significant sequence similarity, allowing cross over to occur with relatively high frequency.

©UWorld

This scenario describes the exchange of genetic information between 2 virus strains that have **nonsegmented, double-stranded** DNA genomes. **Recombination** refers to the exchange of genes between 2 chromosomes via **crossing over** within homologous regions. The resulting progeny can have recombined genomes with traits from both parent viruses. In this case, the thymidine kinase genes in HSV type 1 and 2 virions are likely to have significant sequence similarity, allowing cross over to occur with relatively high frequency.

(Choice A) Interference occurs when one virus inhibits replication and/or release of a second virus that is infecting the same cell. Simple interference would not result in recombinant progeny virions.

(Choice B) Phenotypic mixing can occur when a host cell is coinfected with 2 viral strains and progeny virions contain parental genome from one strain and nucleocapsid (or envelope) proteins from the other strain. This may result in progeny acquiring additional traits (eg, enhanced ability to infect new host cells due to different nucleocapsid proteins). However, as the genome is unchanged, subsequent progeny would not retain these traits.

(Choice C) Reassortment refers to changes in genomic composition that occur when host cells are coinfected with 2 **segmented** viruses that exchange whole genome segments. This process can cause sudden alterations in surface antigens of the viral progeny, as observed with the highly mutagenic influenza virus. However, because the herpesvirus genome is nonsegmented, it does not engage in reassortment.

(Choice E) Transformation is the uptake of naked DNA by a prokaryotic or eukaryotic cell. In virology, transformation also describes incorporation of viral DNA into a host cell chromosome (lysogeny). Transformation alters the genetic composition of the host cell but typically causes no genomic change in progeny virions.

Educational objective:
Recombination refers to gene exchange that occurs through the crossing over of 2 double-stranded DNA molecules. Reassortment describes the mixing of genome segments in segmented viruses that infect the same host cell.

Microbiology	Infectious Diseases	Viral genetics
Subject	System	Topic

Copyright © UWorld. All rights reserved.

©UWorld

Exhibit Display

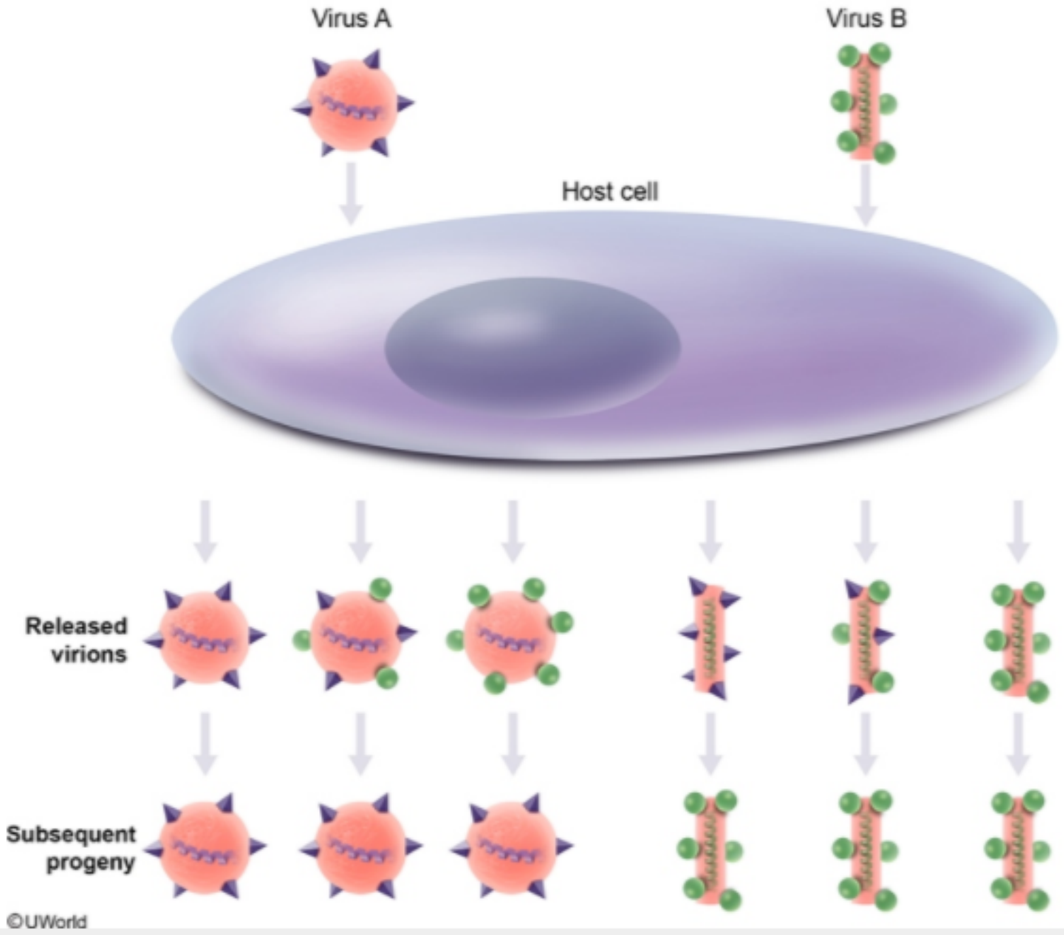

Zoom In | Zoom Out | Reset | Add To New Card | Existing Card

©UWorld

Exhibit Display

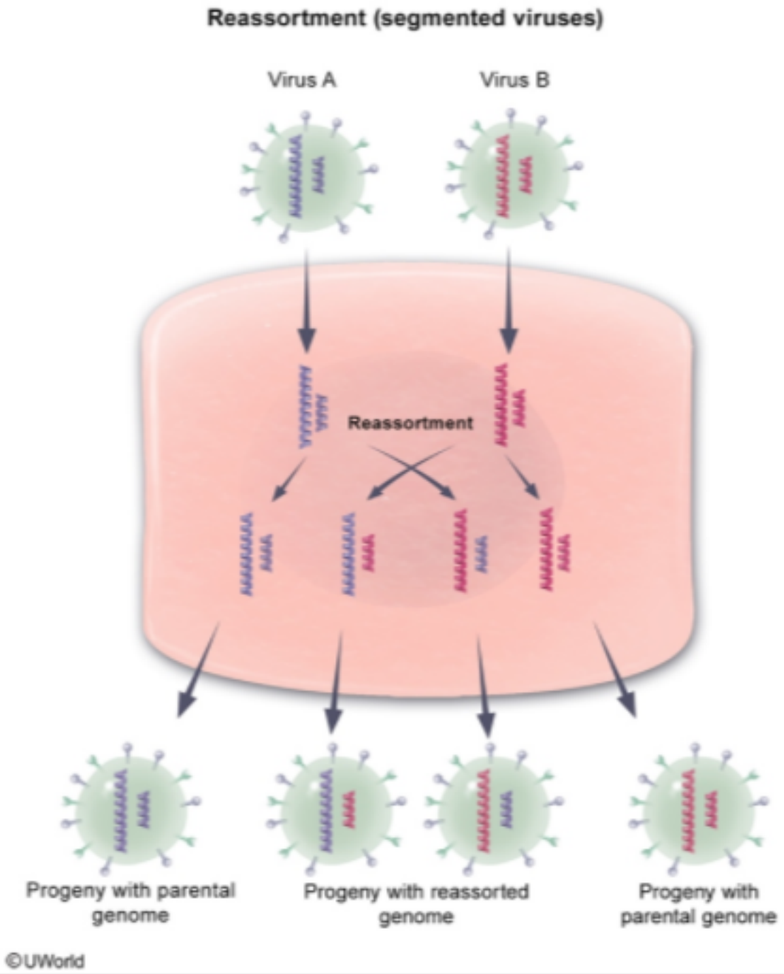

Zoom In | Zoom Out | Reset | Add To New Card | Existing Card

1
2
3
4
5
6
7
8
9
10
11
12
13
14
15
16
17
18
19
20
21
22
23
24
25
26
27
28
29
30
31

A 24-year-old man comes to the emergency department due to bloody diarrhea. His symptoms began 10 days ago with episodic abdominal discomfort and loose stools. The symptoms have progressively worsened, and he has had 6–8 stools mixed with blood and mucus over the past 2 days. The patient recently returned from a 2-week trip to Egypt and felt well while traveling. Temperature is 38 C (100.4 F), blood pressure is 120/70 mm Hg, and pulse is 86/min. The abdomen is soft with mild tenderness on palpation of lower quadrants. There is no guarding or rebound tenderness, and bowel sounds are hyperactive. Stool testing is negative for *C difficile* toxin, and stool culture yields no bacteria. Sigmoidoscopy reveals colonic ulcers with undermining edges that contain trophozoites. The causative organism for this patient's current condition can also produce which of the following manifestations?

- A. Bile duct obstruction
- B. Cystic brain lesions
- C. Granulomatous cystitis
- D. Itchy cutaneous eruptions
- E. Liver abscess

Submit

A 24-year-old man comes to the emergency department due to bloody diarrhea. His symptoms began 10 days ago with episodic abdominal discomfort and loose stools. The symptoms have progressively worsened, and he has had 6–8 stools mixed with blood and mucus over the past 2 days. The patient recently returned from a 2-week trip to Egypt and felt well while traveling. Temperature is 38 C (100.4 F), blood pressure is 120/70 mm Hg, and pulse is 86/min. The abdomen is soft with mild tenderness on palpation of lower quadrants. There is no guarding or rebound tenderness, and bowel sounds are hyperactive. Stool testing is negative for *C difficile* toxin, and stool culture yields no bacteria. Sigmoidoscopy reveals colonic ulcers with undermining edges that contain trophozoites. The causative organism for this patient's current condition can also produce which of the following manifestations?

- A. Bile duct obstruction (6%)
- B. Cystic brain lesions (3%)
- C. Granulomatous cystitis (5%)
- D. Itchy cutaneous eruptions (3%)
- ✓ E. Liver abscess (80%)

Omitted
Correct answer
E

80%
Answered correctly

02 secs
Time Spent

05/20/2020
Last Updated

Explanation

Entamoeba histolytica	
	• Amoeba transmitted via the fecal-oral route

Entamoeba histolytica	
Risk factors	• Amoeba transmitted via the fecal-oral route • Ingestion of contaminated food/water • **Developing nations** (travel/residence)
Manifestations	• 90% of patients asymptomatic • **Colitis** (diarrhea, bloody stool with mucus, abdominal pain) • **Liver abscess** (RUQ pain, fever) • Brain, lung, pleura abscess (less common)
Diagnosis	• Stool ova & parasites – **trophozoites/cysts** • Colonoscopy – **flask-shaped** colonic ulcers

RUQ = right upper quadrant.

Entamoeba histolytica is an amoeba that infects the gastrointestinal tract of humans and is transmitted via the fecal-oral route when cysts are ingested from contaminated food or water. Cases are rare in the United States but commonly occur in developing regions where sanitation is poor. Most infected patients have no symptoms, but a minority (~10%) develop clinically significant **colitis** with subacute bloody-mucoid diarrhea, abdominal pain, and fever. The diagnosis is confirmed when **cysts and trophozoites** are seen on stool studies and/or colonic visualization demonstrates **flask-shaped colonic ulcers** (with trophozoites).

Colonic *E histolytica* infections occasionally (~1%) spread through the bloodstream to the liver, lungs, and/or brain. The most common extraintestinal manifestation is a single **amebic liver abscess** in the right lobe of the liver. Invasive strains are more likely to have amebic proteases that degrade host extracellular membranes and secretory IgA. Almost all invasive strains also demonstrate **contact-dependent cytotoxicity**, whereby an amebic lectin binds the host cell, introduces an amebic porin into the host cell membrane, and causes cell lysis.

(Choice A) Liver flukes (eg, *Clonorchis*, *Opisthorchis*) are typically transmitted due to consuming contaminated fish. The pathogen can remain in the bile duct of an infected patient for decades. Many cases are asymptomatic, but complications such as bile duct obstruction can occur.

(Choice B) Ingestion of the egg stage of the pork tapeworm *Taenia solium* leads to neurocysticercosis, which is characterized by the formation of

Entamoeba histolytica is an amoeba that infects the gastrointestinal tract of humans and is transmitted via the fecal-oral route when cysts are ingested from contaminated food or water. Cases are rare in the United States but commonly occur in developing regions where sanitation is poor. Most infected patients have no symptoms, but a minority (~10%) develop clinically significant **colitis** with subacute bloody-mucoid diarrhea, abdominal pain, and fever. The diagnosis is confirmed when **cysts and trophozoites** are seen on stool studies and/or colonic visualization demonstrates **flask-shaped colonic ulcers** (with trophozoites).

Colonic *E histolytica* infections occasionally (~1%) spread through the bloodstream to the liver, lungs, and/or brain. The most common extraintestinal manifestation is a single **amebic liver abscess** in the right lobe of the liver. Invasive strains are more likely to have amebic proteases that degrade host extracellular membranes and secretory IgA. Almost all invasive strains also demonstrate **contact-dependent cytotoxicity**, whereby an amebic lectin binds the host cell, introduces an amebic porin into the host cell membrane, and causes cell lysis.

(Choice A) Liver flukes (eg, *Clonorchis*, *Opisthorchis*) are typically transmitted due to consuming contaminated fish. The pathogen can remain in the bile duct of an infected patient for decades. Many cases are asymptomatic, but complications such as bile duct obstruction can occur.

(Choice B) Ingestion of the egg stage of the pork tapeworm *Taenia solium* leads to neurocysticercosis, which is characterized by the formation of cystic brain lesions. Manifestations often occur years later and include seizures (primarily) and focal neurologic signs. Spread of *E histolytic* to the brain would cause an abscess, not a cyst.

(Choice C) Schistosomiasis is parasitic blood fluke infection that is acquired when bathing or swimming in freshwater that contains the intermediate host, a freshwater snail. Most cases are asymptomatic but urinary shedding of eggs through the bladder can result in granulomatous inflammation, ulcerations, and, ultimately, bladder cancer.

(Choice D) Cutaneous larva migrans is a hookworm infection that causes an intensely itchy, reddish-brown, migrating, serpiginous cutaneous track in the area near penetration (usually the lower extremities).

Educational objective:
Entamoeba histolytica is an amoeba that causes colitis characterized by ulcers with undermining edges (ie, flask-shaped) that may contain cysts and trophozoites. Trophozoites can occasionally (~1%) invade the colonic wall and disseminate through the blood to the liver, brain, or lungs. Amebic hepatic abscess is the most common extraintestinal manifestation.

abdominal pain, and fever. The diagnosis is confirmed when **cysts and trophozoites** are seen on stool studies and/or colonic visualization demonstrates **flask-shaped colonic ulcers** (with trophozoites).

Colonic *E histolytica* infections occasionally (~1%) spread through the bloodstream to the liver, lungs, and/or brain. The most common extraintestinal manifestation is a single **amebic liver abscess** in the right lobe of the liver. Invasive strains are more likely to have amebic proteases that degrade host extracellular membranes and secretory IgA. Almost all invasive strains also demonstrate **contact-dependent cytotoxicity**, whereby an amebic lectin binds the host cell, introduces an amebic porin into the host cell membrane, and causes cell lysis.

(Choice A) Liver flukes (eg, *Clonorchis*, *Opisthorchis*) are typically transmitted due to consuming contaminated fish. The pathogen can remain in the bile duct of an infected patient for decades. Many cases are asymptomatic, but complications such as bile duct obstruction can occur.

(Choice B) Ingestion of the egg stage of the pork tapeworm *Taenia solium* leads to neurocysticercosis, which is characterized by the formation of cystic brain lesions. Manifestations often occur years later and include seizures (primarily) and focal neurologic signs. Spread of *E histolytic* to the brain would cause an abscess, not a cyst.

(Choice C) Schistosomiasis is parasitic blood fluke infection that is acquired when bathing or swimming in freshwater that contains the intermediate host, a freshwater snail. Most cases are asymptomatic but urinary shedding of eggs through the bladder can result in granulomatous inflammation, ulcerations, and, ultimately, bladder cancer.

(Choice D) Cutaneous larva migrans is a hookworm infection that causes an intensely itchy, reddish-brown, migrating, serpiginous cutaneous track in the area near penetration (usually the lower extremities).

Educational objective:
Entamoeba histolytica is an amoeba that causes colitis characterized by ulcers with undermining edges (ie, flask-shaped) that may contain cysts and trophozoites. Trophozoites can occasionally (~1%) invade the colonic wall and disseminate through the blood to the liver, brain, or lungs. Amebic hepatic abscess is the most common extraintestinal manifestation.

Microbiology	Infectious Diseases	Amebiasis
Subject	System	Topic

Copyright © UWorld. All rights reserved.

A 25-year-old man is hospitalized with fever, anorexia, and fatigue. He admits to IV drug abuse and many episodes of unprotected sex over the past few years. His condition is treated and he is discharged from the hospital. The patient follows up with his physician regularly over the next 8 months, and the following serologic marker dynamics are obtained (see the graph below).

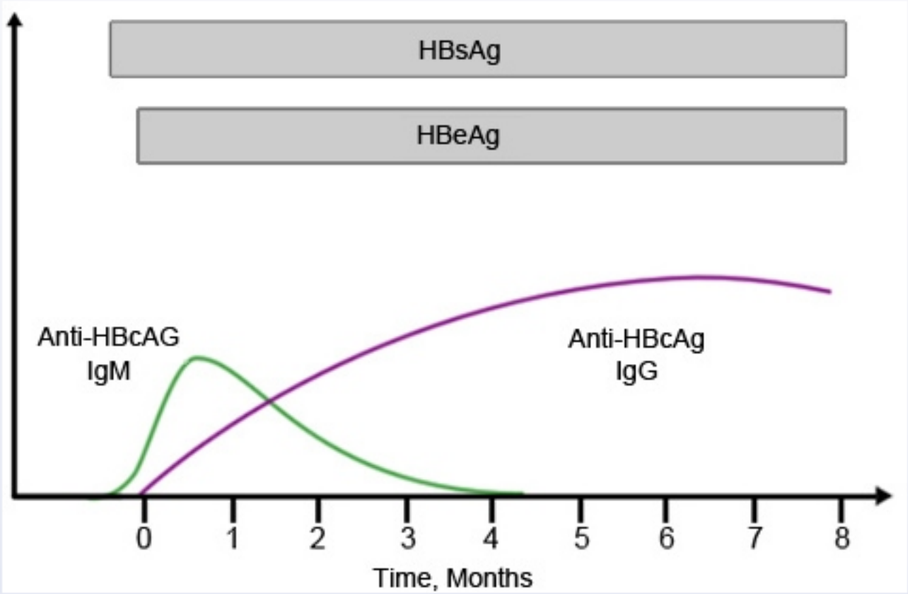

*Grey bars indicate the detectable presence of the specified serum marker.

This patient most likely:

A. Had acute hepatitis B and has successfully recovered

B. Had an exacerbation of preexisting hepatitis B

C. Had acute hepatitis B that has progressed to chronic hepatitis with low infectivity

D. Had acute hepatitis B that has progressed to chronic hepatitis with high infectivity

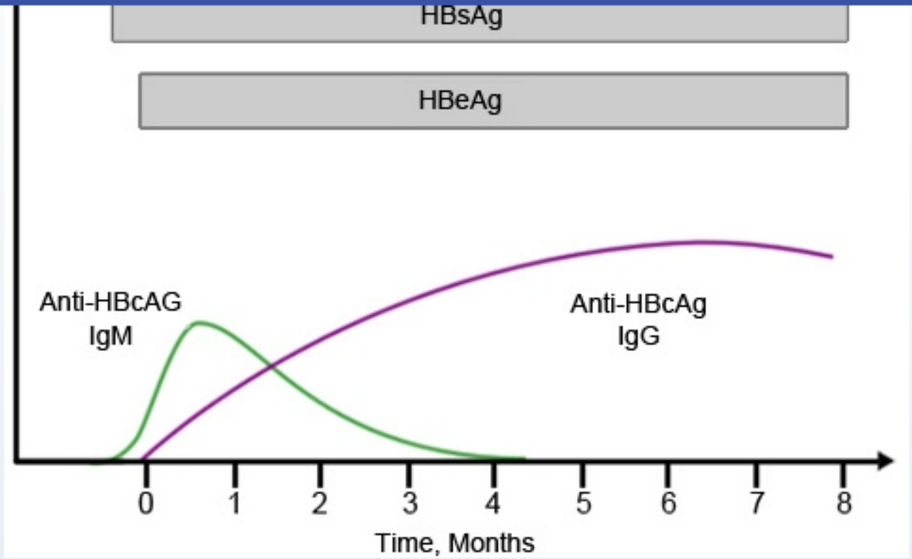

*Grey bars indicate the detectable presence of the specified serum marker.

This patient most likely:

A. Had acute hepatitis B and has successfully recovered

B. Had an exacerbation of preexisting hepatitis B

C. Had acute hepatitis B that has progressed to chronic hepatitis with low infectivity

D. Had acute hepatitis B that has progressed to chronic hepatitis with high infectivity

E. Was vaccinated against HBV during the hospitalization

Submit

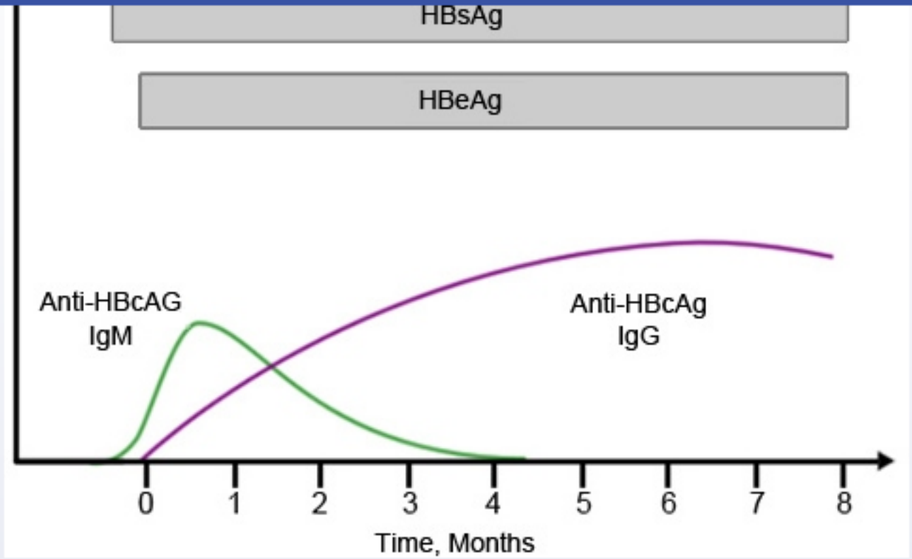

*Grey bars indicate the detectable presence of the specified serum marker.

This patient most likely:

A. Had acute hepatitis B and has successfully recovered (5%)

B. Had an exacerbation of preexisting hepatitis B (1%)

C. Had acute hepatitis B that has progressed to chronic hepatitis with low infectivity (7%)

✓ D. Had acute hepatitis B that has progressed to chronic hepatitis with high infectivity (83%)

E. Was vaccinated against HBV during the hospitalization (1%)

Omitted
Correct answer

83%
Answered correctly

05 secs
Time Spent

06/01/2020
Last Updated

The serologic markers for hepatitis B infection appear on a predictable timeline with a long asymptomatic incubation period (lasting an average of 6-8 weeks) followed by acute disease lasting several weeks to months. HBsAg first appears before the onset of symptoms, peaks when the patient is most ill, and then becomes undetectable in 3-6 months (unless the disease progresses to a chronic phase). Shortly after HBsAg first appears, HBeAg and HBV DNA can be detected in the serum and are markers of active viral replication. Anti-HBcAg IgM and elevated serum transaminases appear shortly before symptom onset. Over the next few months, the anti-HBcAg IgM component is replaced with an IgG component. Anti-HBeAg appears shortly after HBeAg vanishes and suggests subsiding viral activity (transition from high viral replication/infectivity to low viral replication/infectivity). Anti-HBsAg IgG arises once the acute disease has resolved (unless the disease progresses to a chronic phase), and is typically not detectable until weeks or months after HBsAg has disappeared. This antibody may persist indefinitely, conferring lifelong immunity.

Given this serologic marker graph, it appears that this patient has a persistence of HBsAg and HBeAg over a long period with low to moderate levels of anti-HBcAg IgG and no detectable Anti-HBsAg. These findings are suggestive of an acute hepatitis B infection that has not resolved, but rather has progressed to a highly infectious chronic hepatitis B (note the persistence of HBeAg and lack of anti-HBeAg).

(Choice A) Were this patient to have fully recovered from his bout of acute hepatitis B, all antigens should have dropped to undetectable levels and he should have high levels of anti-HBsAg IgG and anti-HBcAg IgG.

(Choice B) An exacerbation of preexisting hepatitis B would be characterized by a decline followed by a spike in antigen levels.

(Choice C) Acute hepatitis B that progressed to chronic hepatitis with low infectivity would be indicated by a graph similar to the one shown for this patient. However, there would be low or undetectable levels of HBeAg (the marker for high infectivity) and likely detectable quantities of anti-HBeAg.

(Choice E) Vaccination against HBV would be identified by a surge in anti-HBsAb with no anti-HBcAg, anti-HBeAg, or viral antigens detected.

Educational objective:
If HBeAg persists for several months and host anti-HBeAg remain at low or undetectable levels, suspect chronic hepatitis B infection with high infectivity.

Microbiology Infectious Diseases Hepatitis b

patient is most ill, and then becomes undetectable in 3-6 months (unless the disease progresses to a chronic phase). Shortly after HBsAg first appears, HBeAg and HBV DNA can be detected in the serum and are markers of active viral replication. Anti-HBcAg IgM and elevated serum transaminases appear shortly before symptom onset. Over the next few months, the anti-HBcAg IgM component is replaced with an IgG component. Anti-HBeAg appears shortly after HBeAg vanishes and suggests subsiding viral activity (transition from high viral replication/infectivity to low viral replication/infectivity). Anti-HBsAg IgG arises once the acute disease has resolved (unless the disease progresses to a chronic phase), and is typically not detectable until weeks or months after HBsAg has disappeared. This antibody may persist indefinitely, conferring lifelong immunity.

Given this serologic marker graph, it appears that this patient has a persistence of HBsAg and HBeAg over a long period with low to moderate levels of anti-HBcAg IgG and no detectable Anti-HBsAg. These findings are suggestive of an acute hepatitis B infection that has not resolved, but rather has progressed to a highly infectious chronic hepatitis B (note the persistence of HBeAg and lack of anti-HBeAg).

(Choice A) Were this patient to have fully recovered from his bout of acute hepatitis B, all antigens should have dropped to undetectable levels and he should have high levels of anti-HBsAg IgG and anti-HBcAg IgG.

(Choice B) An exacerbation of preexisting hepatitis B would be characterized by a decline followed by a spike in antigen levels.

(Choice C) Acute hepatitis B that progressed to chronic hepatitis with low infectivity would be indicated by a graph similar to the one shown for this patient. However, there would be low or undetectable levels of HBeAg (the marker for high infectivity) and likely detectable quantities of anti-HBeAg.

(Choice E) Vaccination against HBV would be identified by a surge in anti-HBsAb with no anti-HBcAg, anti-HBeAg, or viral antigens detected.

Educational objective:
If HBeAg persists for several months and host anti-HBeAg remain at low or undetectable levels, suspect chronic hepatitis B infection with high infectivity.

Microbiology	Infectious Diseases	Hepatitis b
Subject	System	Topic

Copyright © UWorld. All rights reserved.

A 29-year-old male is hospitalized with low-grade fever and high serum levels of alanine aminotransferase (ALT) and aspartate aminotransferase (AST). His serum is positive for HBsAg. You should inform the patient that the most likely outcome for his infection would be:

A. Complete resolution

B. Fulminant hepatitis

C. Stable chronic hepatitis

D. Chronic hepatitis with progression to cirrhosis

E. Chronic hepatitis with progression to hepatocellular carcinoma

Submit

A 29-year-old male is hospitalized with low-grade fever and high serum levels of alanine aminotransferase (ALT) and aspartate aminotransferase (AST). His serum is positive for HBsAg. You should inform the patient that the most likely outcome for his infection would be:

- ✓ A. Complete resolution (58%)
- B. Fulminant hepatitis (5%)
- C. Stable chronic hepatitis (19%)
- D. Chronic hepatitis with progression to cirrhosis (9%)
- E. Chronic hepatitis with progression to hepatocellular carcinoma (7%)

Omitted
Correct answer
A

58%
Answered correctly

02 secs
Time Spent

02/03/2020
Last Updated

Explanation

Hepatitis B virus infection can produce one of three syndromes: acute hepatitis with complete resolution; chronic hepatitis (with or without cirrhosis and the attendant increased risk of hepatocellular carcinoma); or fulminant hepatitis with massive liver necrosis. By far the most common outcome in HBV-infected adults (> 95%) is acute hepatitis with mild or subclinical symptoms that eventually completely resolve.

(Choice B) Fulminant hepatitis occurs in < 1% of patients who develop acute hepatitis.

(Choice C) Only 4-5% of patients with hepatitis B virus infection will go on to develop chronic hepatitis. Of those, 50-80% will remain stable with no evidence of cirrhosis.

E. Chronic hepatitis with progression to hepatocellular carcinoma (7%)

Omitted
Correct answer
A

58%
Answered correctly

02 secs
Time Spent

02/03/2020
Last Updated

Explanation

Hepatitis B virus infection can produce one of three syndromes: acute hepatitis with complete resolution; chronic hepatitis (with or without cirrhosis and the attendant increased risk of hepatocellular carcinoma); or fulminant hepatitis with massive liver necrosis. By far the most common outcome in HBV-infected adults (> 95%) is acute hepatitis with mild or subclinical symptoms that eventually completely resolve.

(Choice B) Fulminant hepatitis occurs in < 1% of patients who develop acute hepatitis.

(Choice C) Only 4-5% of patients with hepatitis B virus infection will go on to develop chronic hepatitis. Of those, 50-80% will remain stable with no evidence of cirrhosis.

(Choice D) Approximately 20-50% of patients with chronic hepatitis B infection will also eventually develop cirrhosis.

(Choice E) Hepatocellular carcinoma arises in 10% of patients with chronic hepatitis and cirrhosis.

Educational Objective:
The most common outcome in HBV-infected adults (> 95%) is acute hepatitis with mild or subclinical symptoms that eventually completely resolve.

Microbiology	Infectious Diseases	Hepatitis b
Subject	System	Topic

Copyright © UWorld. All rights reserved.

A 27-year-old man comes to the emergency department due to 2 weeks of low-grade fever, malaise, and loss of appetite. The patient has no prior medical conditions and takes no medications. He does not smoke cigarettes or drink alcohol but regularly injects illicit drugs. The patient is sexually active and uses condoms inconsistently. Physical examination reveals scleral icterus. A smooth and mildly tender liver edge is palpable 4 cm below the right costal margin. Laboratory results are as follows:

Liver function studies	
Total bilirubin	4.3 mg/dL
Alkaline phosphatase	220 U/L
Aspartate aminotransferase (SGOT)	1,600 U/L
Alanine aminotransferase (SGPT)	2,100 U/L

Hepatitis panel	
Hepatitis A virus antibody, IgM	negative
Hepatitis B surface antibody (HBsAb)	negative
Hepatitis B core antibody (HBcAb), IgM	positive
Hepatitis B surface antigen (HBsAg)	positive
Hepatitis C virus antibody	negative

Which of the following is an essential step in the replication cycle of the virus infecting this patient?

A. Cleavage of precursor polyprotein by viral protease
B. Expression of regulatory latency-associated transcript
C. Integration of viral DNA into the host genome

Total bilirubin	4.3 mg/dL
Alkaline phosphatase	220 U/L
Aspartate aminotransferase (SGOT)	1,600 U/L
Alanine aminotransferase (SGPT)	2,100 U/L

Hepatitis panel

Hepatitis A virus antibody, IgM	negative
Hepatitis B surface antibody (HBsAb)	negative
Hepatitis B core antibody (HBcAb), IgM	positive
Hepatitis B surface antigen (HBsAg)	positive
Hepatitis C virus antibody	negative

Which of the following is an essential step in the replication cycle of the virus infecting this patient?

A. Cleavage of precursor polyprotein by viral protease
B. Expression of regulatory latency-associated transcript
C. Integration of viral DNA into the host genome
D. Release of new viral particles by host cell lysis
E. Reverse transcription of template RNA to viral DNA

Submit

Total bilirubin	4.3 mg/dL
Alkaline phosphatase	220 U/L
Aspartate aminotransferase (SGOT)	1,600 U/L
Alanine aminotransferase (SGPT)	2,100 U/L

Hepatitis panel

Hepatitis A virus antibody, IgM	negative
Hepatitis B surface antibody (HBsAb)	negative
Hepatitis B core antibody (HBcAb), IgM	positive
Hepatitis B surface antigen (HBsAg)	positive
Hepatitis C virus antibody	negative

Which of the following is an essential step in the replication cycle of the virus infecting this patient?

A. Cleavage of precursor polyprotein by viral protease (4%)
B. Expression of regulatory latency-associated transcript (4%)
C. Integration of viral DNA into the host genome (31%)
D. Release of new viral particles by host cell lysis (8%)
✓ E. Reverse transcription of template RNA to viral DNA (50%)

Omitted
Correct answer

50%
Answered correctly

04 secs
Time Spent

04/28/2020
Last Updated

1
2
3
4
5
6
7
8
9
10
11
12
13
14
15
16
17
18
19
20
21
22
23
24
25
26
27
28
29
30
31

HBV life cycle

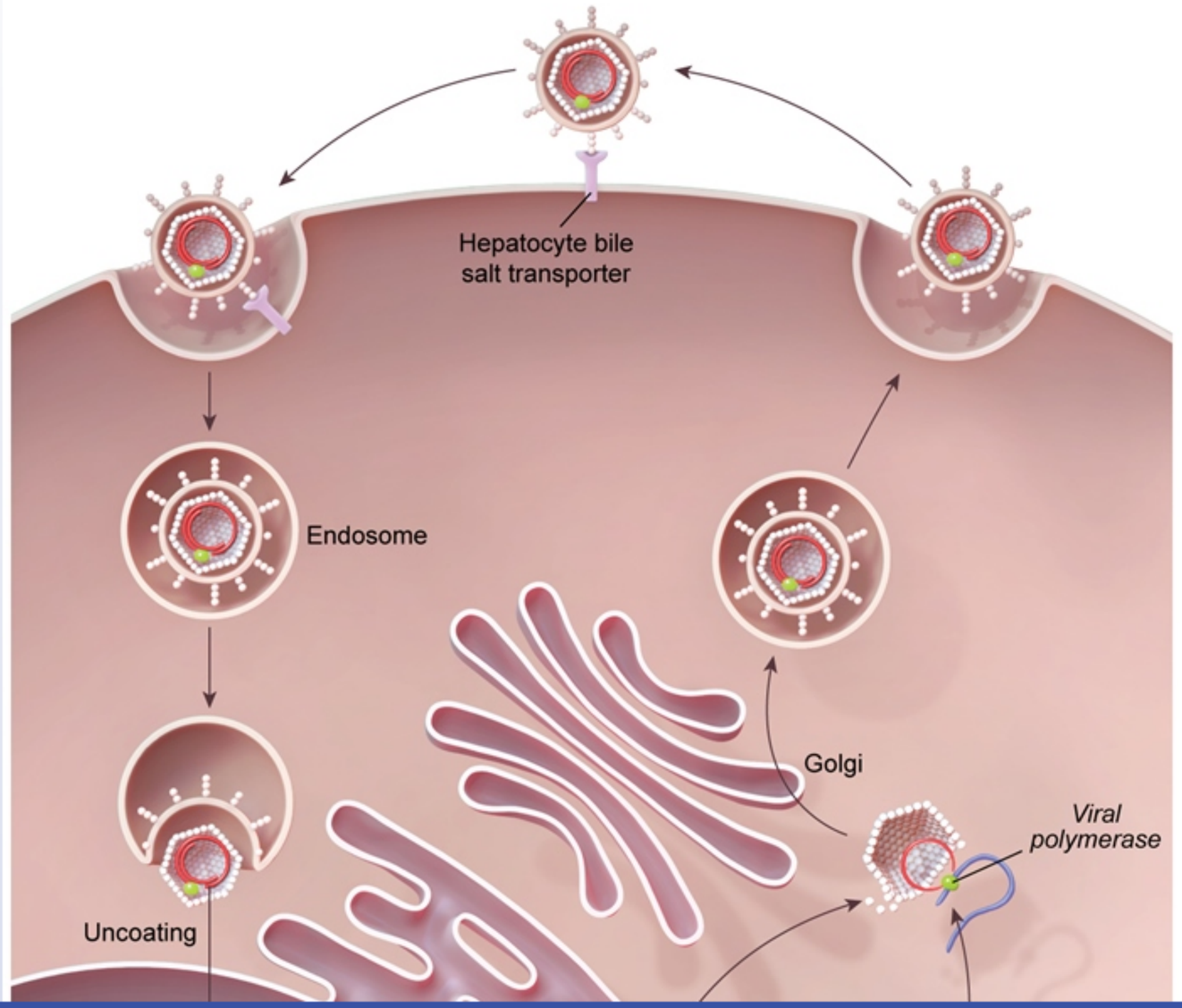

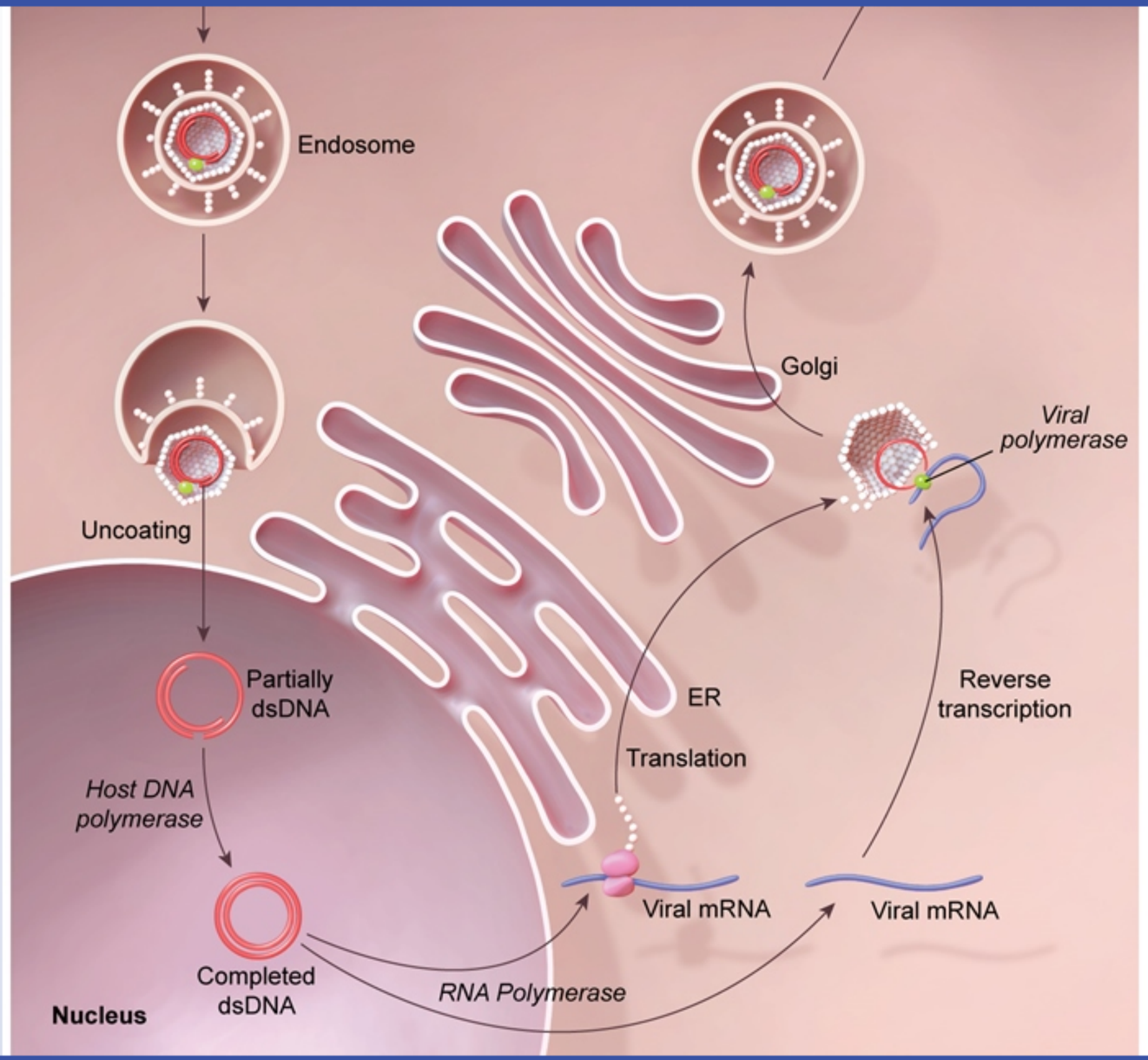
Endosome
Uncoating
Partially dsDNA
Host DNA polymerase
Completed dsDNA
Nucleus
RNA Polymerase
Viral mRNA
Translation
ER
Golgi
Viral mRNA
Reverse transcription
Viral polymerase

Acute hepatitis B virus (HBV) infection is associated with the shedding of viral antigens (HBsAg, HBeAg) and HBV DNA into the bloodstream and the development of IgM antibodies against HBc. Patients are often asymptomatic, but a minority develops constitutional symptoms (eg, fatigue, loss of appetite), hepatomegaly, icterus, and significant elevations in aminotransferase levels. Transmission in low-prevalence countries (eg, United States) is usually due to injection drug use or unprotected sex.

HBV is an encapsulated virus with a partially double-stranded DNA genome. It binds to and enters hepatocytes using a host cell bile salt transporter and then sheds its coat in the host cytoplasm. The partially double-stranded genome is "repaired" and transcribed by host cell machinery, yielding a **+ sense single-stranded mRNA template**. This serves as a **pre-genome** for future progeny; it is converted by **viral reverse transcriptase** into the partially double-stranded DNA genome of budding viral particles (which are subsequently released from the cell). The mRNA template is also translated by host ribosomes into the proteins that compose the virus.

(Choice A) Both hepatitis C virus and HIV encode for a viral protease that cleaves viral polyprotein into individual proteins. Protease inhibitors target this step in viral replication and are used for treatment. HBV does not generate a polyprotein; therefore, it does not encode for a viral protease.

(Choice B) Herpes simplex virus type 1 establishes a life-long latent infection within sensory neurons where it expresses latency-associated transcript, a non-protein coding RNA molecule that suppresses viral lytic genes and inhibits host cell apoptosis.

(Choice C) Although HBV can insert its genome into host chromosomes (which contributes to hepatocarcinogenesis), this step is not required for viral replication. In contrast, HIV must integrate into the host genome in order to replicate. Integrase inhibitors (eg, dolutegravir) target this step in HIV replication.

(Choice D) HBV is released via exocytosis from host cells and is not considered a lytic virus. Hepatocyte damage occurs primarily when cytotoxic T cells recognize HBV antigens on infected cells. Patients who clear the virus have a robust, polyclonal, cytotoxic T-cell response. Those that develop latent infection often have a much weaker and narrower cytotoxic T-cell response.

Educational objective:
Hepatitis B virus has a partially double-stranded DNA genome and contains a viral DNA polymerase with reverse transcriptase activity. Reverse transcriptase serves a crucial step in viral replication; it converts transcribed positive sense single-stranded RNA into the partially double-stranded DNA genome of viral progeny.

References

machinery, yielding a **+ sense single-stranded mRNA template**. This serves as a **pre-genome** for future progeny; it is converted by **viral reverse transcriptase** into the partially double-stranded DNA genome of budding viral particles (which are subsequently released from the cell). The mRNA template is also translated by host ribosomes into the proteins that compose the virus.

(Choice A) Both hepatitis C virus and HIV encode for a viral protease that cleaves viral polyprotein into individual proteins. Protease inhibitors target this step in viral replication and are used for treatment. HBV does not generate a polyprotein; therefore, it does not encode for a viral protease.

(Choice B) Herpes simplex virus type 1 establishes a life-long latent infection within sensory neurons where it expresses latency-associated transcript, a non-protein coding RNA molecule that suppresses viral lytic genes and inhibits host cell apoptosis.

(Choice C) Although HBV can insert its genome into host chromosomes (which contributes to hepatocarcinogenesis), this step is not required for viral replication. In contrast, HIV must integrate into the host genome in order to replicate. Integrase inhibitors (eg, dolutegravir) target this step in HIV replication.

(Choice D) HBV is released via exocytosis from host cells and is not considered a lytic virus. Hepatocyte damage occurs primarily when cytotoxic T cells recognize HBV antigens on infected cells. Patients who clear the virus have a robust, polyclonal, cytotoxic T-cell response. Those that develop latent infection often have a much weaker and narrower cytotoxic T-cell response.

Educational objective:
Hepatitis B virus has a partially double-stranded DNA genome and contains a viral DNA polymerase with reverse transcriptase activity. Reverse transcriptase serves a crucial step in viral replication; it converts transcribed positive sense single-stranded RNA into the partially double-stranded DNA genome of viral progeny.

References

- Medical virology of hepatitis B: how it began and where we are now.

Microbiology	Infectious Diseases	Hepatitis b
Subject	System	Topic

Copyright © UWorld. All rights reserved.

A 43-year-old man comes to the office due to increasing discomfort and pain with sitting for the past several months. He also has had occasional perianal pruritus. Physical examination shows multiple, cauliflower-shaped, verrucous growths measuring 1 to 2 cm on the perianal skin. Histopathologic examination of the lesion reveals hyperplastic papillary squamous epithelium with parakeratosis, nuclear irregularity, and "perinuclear halos" of cytoplasmic vacuolization. Which of the following additional evaluations is most appropriate for this patient?

A. Adhesive paddle test with microscopy

B. Colonoscopy with terminal ileoscopy

C. Darkfield microscopy of the tissue

D. Hepatic venous pressure measurement

E. HIV antigen and antibody testing

Submit

A 43-year-old man comes to the office due to increasing discomfort and pain with sitting for the past several months. He also has had occasional perianal pruritus. Physical examination shows multiple, cauliflower-shaped, verrucous growths measuring 1 to 2 cm on the perianal skin. Histopathologic examination of the lesion reveals hyperplastic papillary squamous epithelium with parakeratosis, nuclear irregularity, and "perinuclear halos" of cytoplasmic vacuolization. Which of the following additional evaluations is most appropriate for this patient?

- A. Adhesive paddle test with microscopy (6%)
- B. Colonoscopy with terminal ileoscopy (12%)
- C. Darkfield microscopy of the tissue (11%)
- D. Hepatic venous pressure measurement (1%)
- ✓ E. HIV antigen and antibody testing (69%)

Omitted
Correct answer
E

69%
Answered correctly

02 secs
Time Spent

05/11/2020
Last Updated

Explanation

Condylomata acuminata (anogenital warts)	
Etiology	• Human papillomavirus types 6 & 11 • May have coinfection with other genotypes
Appearance	• Plaques, papules, verrucous lesions • Genitalia, perineum, perianal skin

Condylomata acuminata (anogenital warts)	
Etiology	• Human papillomavirus types 6 & 11 • May have coinfection with other genotypes
Appearance	• Plaques, papules, verrucous lesions • Genitalia, perineum, perianal skin
Biopsy	• Thickening of the stratum corneum • Epidermal hyperplasia • Cytoplasmic vacuolization
Disease associations & risk factors	• HIV • Other sexually transmitted infections • Immune suppression

Condylomata acuminata (anogenital warts [**AGW**]) are characterized by pink or skin-colored plaques, papules, and verrucous lesions on the genitalia, perineum, or perianal skin. AGW are caused by **human papillomavirus** (HPV), primarily **types 6 and 11**. The diagnosis is usually apparent on clinical examination, but biopsy is often helpful for large or atypical lesions. Pathologic findings include papilloma formation (black arrow) with thickening of the stratum corneum (hyperkeratosis, blue arrow) and epidermal hyperplasia (acanthosis); nuclear irregularity and perinuclear vacuolization are common but nonspecific.

AGW are associated with an increased **risk for HIV infection**. AGW and HIV share common risk factors; both are frequently acquired via sexual contact and have an increased prevalence in men who have sex with men. In addition, patients with immune suppression (eg, transplant immunosuppression, HIV infection) have increased incidence of AGW and frequently have multiple, widespread lesions. Conversely, large, friable AGW lesions likely confer increased susceptibility to acquiring HIV infection. Therefore, **HIV testing** is recommended.

(Choice A) Pinworm (*Enterobius vermicularis*) infection is confirmed on microscopy after sampling the perianal area for eggs with an adhesive paddle or cellophane tape. This condition can present with severe pruritus but does not cause verrucous lesions.

(Choice B) Colonoscopy with terminal ileoscopy is used to evaluate for ileocolonic Crohn disease. Patients commonly have perianal

Condylomata acuminata (anogenital warts [**AGW**]) are characterized by pink or skin-colored plaques, papules, and verrucous lesions on the genitalia, perineum, or perianal skin. AGW are caused by **human papillomavirus** (HPV), primarily **types 6 and 11**. The diagnosis is usually apparent on clinical examination, but biopsy is often helpful for large or atypical lesions. Pathologic findings include papilloma formation (black arrow) with thickening of the stratum corneum (hyperkeratosis, blue arrow) and epidermal hyperplasia (acanthosis); nuclear irregularity and perinuclear vacuolization are common but nonspecific.

AGW are associated with an increased **risk for HIV infection**. AGW and HIV share common risk factors; both are frequently acquired via sexual contact and have an increased prevalence in men who have sex with men. In addition, patients with immune suppression (eg, transplant immunosuppression, HIV infection) have increased incidence of AGW and frequently have multiple, widespread lesions. Conversely, large, friable AGW lesions likely confer increased susceptibility to acquiring HIV infection. Therefore, **HIV testing** is recommended.

(Choice A) Pinworm (*Enterobius vermicularis*) infection is confirmed on microscopy after sampling the perianal area for eggs with an adhesive paddle or cellophane tape. This condition can present with severe pruritus but does not cause verrucous lesions.

(Choice B) Colonoscopy with terminal ileoscopy is used to evaluate for ileocolonic Crohn disease. Patients commonly have perianal involvement, but typical findings include painful abscesses and draining fistulae.

(Choice C) Condyloma lata is a manifestation of secondary syphilis, which can be confirmed by direct visualization of *Treponema pallidum* on darkfield microscopy of the tissue or exudate. Although condyloma lata may present as verruciform lesions resembling AGW, biopsy typically reveals a dense lymphoplasmacytic infiltrate.

(Choice D) Portal hypertension can lead to dilation of peripheral portosystemic collaterals. Involvement of the rectal submucosal veins (connecting the inferior mesenteric and iliac systems) can cause rectal varices, which present as enlarged veins resembling internal hemorrhoids. External verrucae are more consistent with AGW.

Educational objective:
Condylomata acuminata (anogenital warts) present as pink- or skin-colored plaques, papules, and verrucous lesions on the genitalia, perineum, or perianal skin; they are caused by human papillomavirus, primarily types 6 and 11. These lesions are associated with increased risk for HIV infection, and HIV testing is recommended.

References

1
2
3
4
5
6
7
8
9
10
11
12
13
14
15
16
17
18
19
20
21
22
23
24
25
26
27
28
29
30
31

Exhibit Display

Zoom In
Zoom Out
Reset
Add To Flash Card

References

Exhibit Display

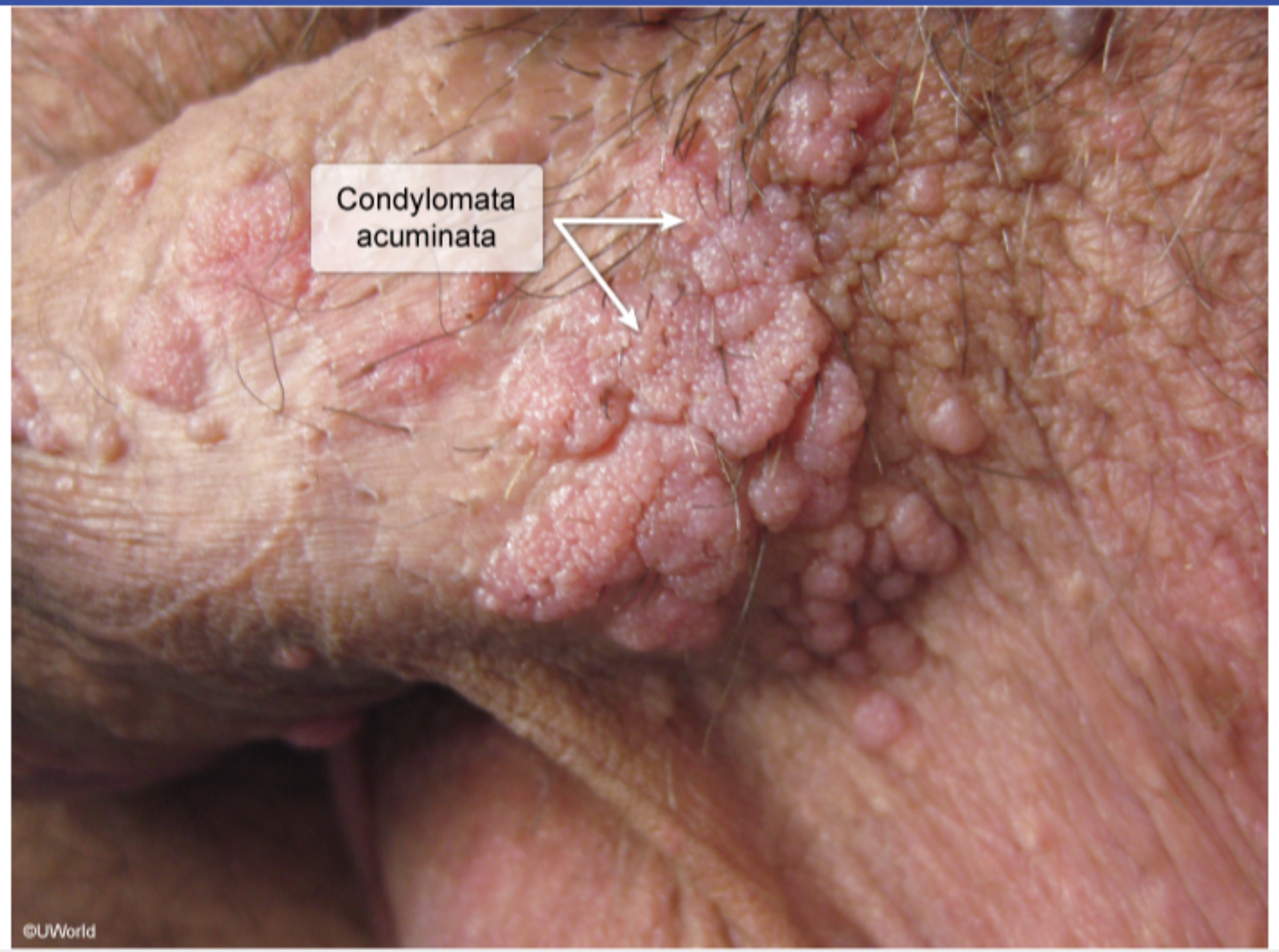

Zoom In Zoom Out Reset Add To Flash Card

References

Exhibit Display

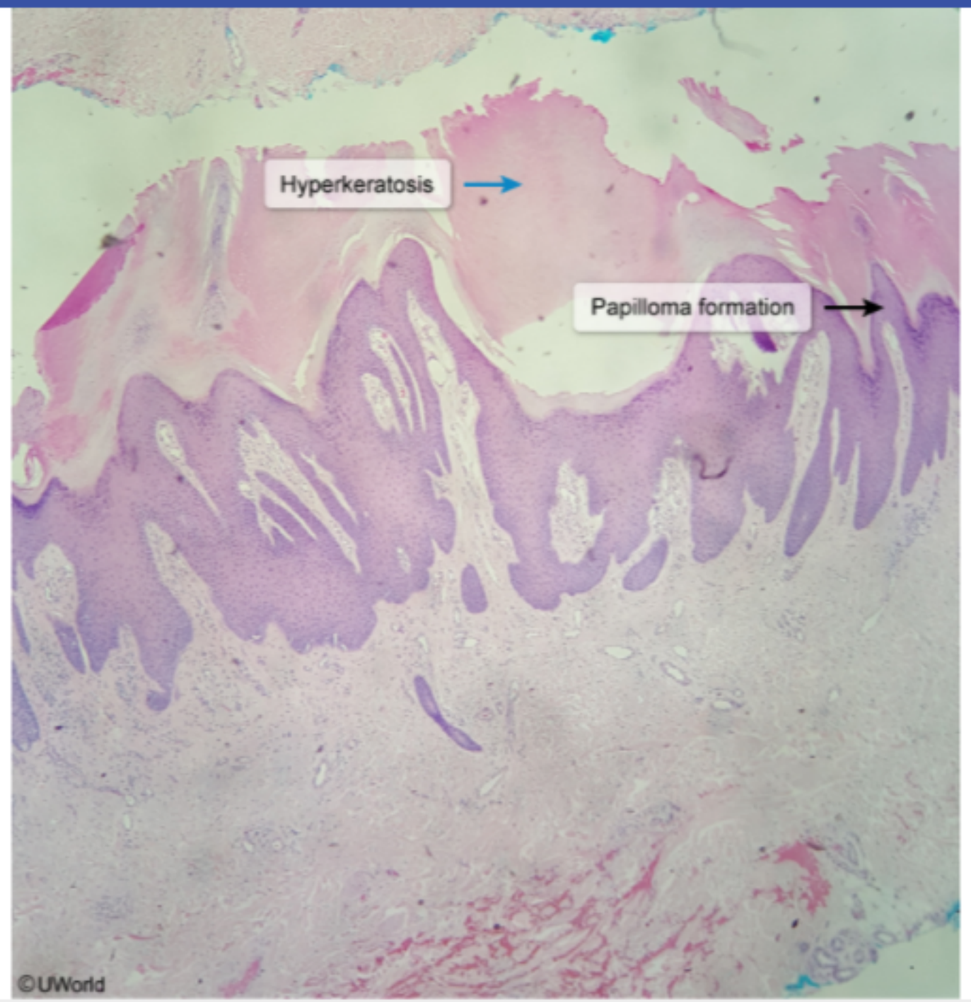

Zoom In Zoom Out Reset Add To Flash Card

References

Exhibit Display

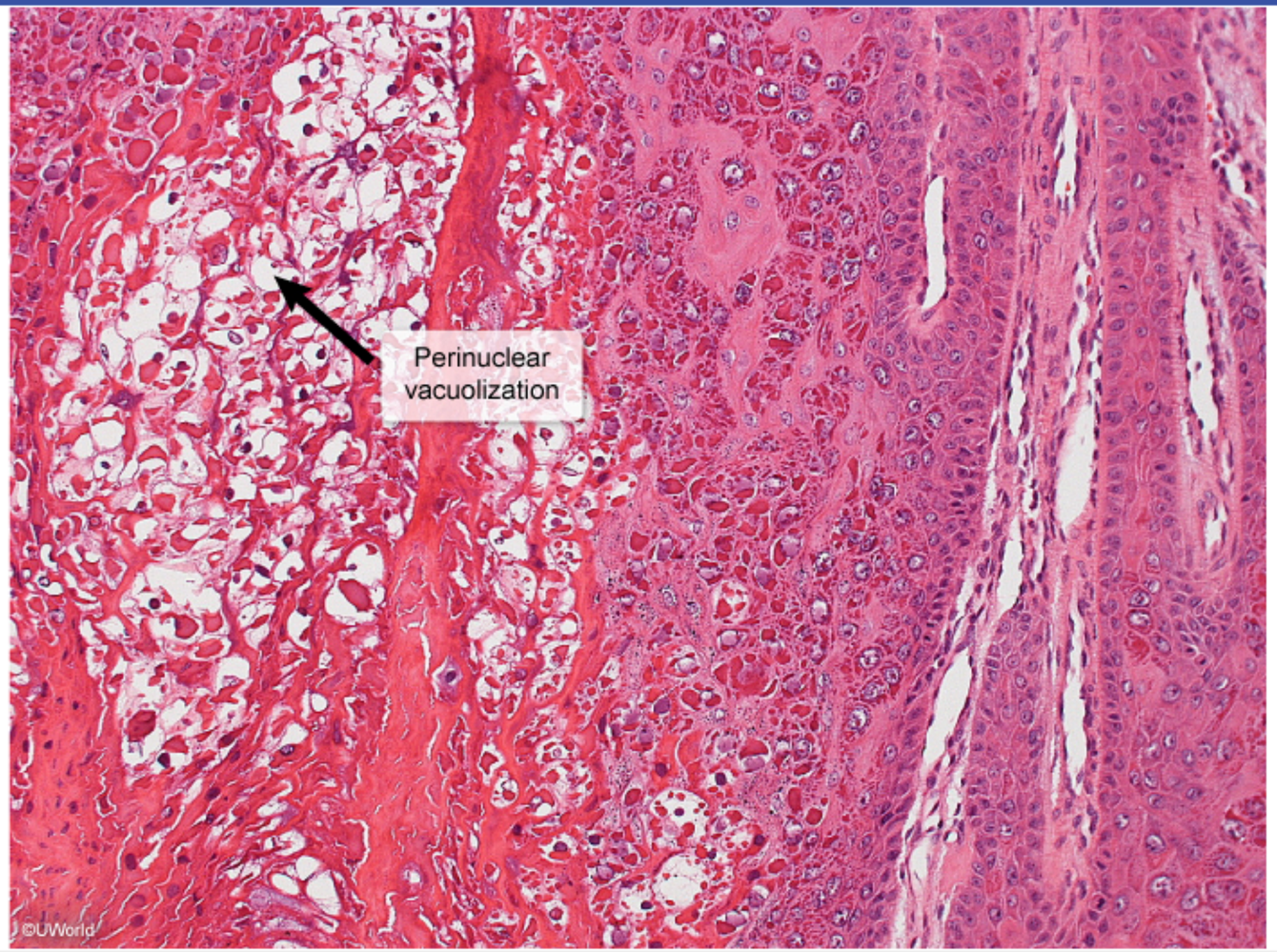

Zoom In Zoom Out Reset Add To Flash Card

References

immunosuppression, HIV infection) have increased incidence of AGW and frequently have multiple, widespread lesions. Conversely, large, friable AGW lesions likely confer increased susceptibility to acquiring HIV infection. Therefore, **HIV testing** is recommended.

(Choice A) Pinworm (*Enterobius vermicularis*) infection is confirmed on microscopy after sampling the perianal area for eggs with an adhesive paddle or cellophane tape. This condition can present with severe pruritus but does not cause verrucous lesions.

(Choice B) Colonoscopy with terminal ileoscopy is used to evaluate for ileocolonic Crohn disease. Patients commonly have perianal involvement, but typical findings include painful abscesses and draining fistulae.

(Choice C) Condyloma lata is a manifestation of secondary syphilis, which can be confirmed by direct visualization of *Treponema pallidum* on darkfield microscopy of the tissue or exudate. Although condyloma lata may present as verruciform lesions resembling AGW, biopsy typically reveals a dense lymphoplasmacytic infiltrate.

(Choice D) Portal hypertension can lead to dilation of peripheral portosystemic collaterals. Involvement of the rectal submucosal veins (connecting the inferior mesenteric and iliac systems) can cause rectal varices, which present as enlarged veins resembling internal hemorrhoids. External verrucae are more consistent with AGW.

Educational objective:
Condylomata acuminata (anogenital warts) present as pink- or skin-colored plaques, papules, and verrucous lesions on the genitalia, perineum, or perianal skin; they are caused by human papillomavirus, primarily types 6 and 11. These lesions are associated with increased risk for HIV infection, and HIV testing is recommended.

References

- Human papillomavirus and immunosuppression.
- Condylomata acuminata (anogenital warts) contain accumulations of HIV-1 target cells that may provide portals for HIV transmission.

Microbiology	Infectious Diseases	Warts
Subject	System	Topic

Copyright © UWorld. All rights reserved.

A 3-month-old boy is brought to the emergency department due to 2 days of fever and irritation that progressed to lethargy. Temperature is 38.6 C (101.5 F). A lumbar puncture is performed, and the results of cerebrospinal fluid (CSF) analysis are as follows:

Glucose	30 mg/dL
Protein	180 mg/dL
Leukocytes	1,000/mm^3

Gram-negative coccobacilli are isolated from the CSF. These organisms demonstrate little growth on 5% sheep blood agar but grow well when incubated on the same media alongside colonies of *Staphylococcus aureus*. Staphylococci promote the growth of these bacteria by supplementing which of the following substances?

- A. ATP
- B. Catalase
- C. Iron
- D. Lactose
- E. NAD+
- F. Pyruvate

Submit

A 3-month-old boy is brought to the emergency department due to 2 days of fever and irritation that progressed to lethargy. Temperature is 38.6 C (101.5 F). A lumbar puncture is performed, and the results of cerebrospinal fluid (CSF) analysis are as follows:

Glucose	30 mg/dL
Protein	180 mg/dL
Leukocytes	1,000/mm^3

Gram-negative coccobacilli are isolated from the CSF. These organisms demonstrate little growth on 5% sheep blood agar but grow well when incubated on the same media alongside colonies of *Staphylococcus aureus*. Staphylococci promote the growth of these bacteria by supplementing which of the following substances?

- A. ATP (3%)
- B. Catalase (25%)
- C. Iron (7%)
- D. Lactose (2%)
- ✓ E. NAD+ (59%)
- F. Pyruvate (1%)

Omitted
Correct answer
E

59%
Answered correctly

02 secs
Time Spent

02/03/2020
Last Updated

Explanation

This patient likely has *Haemophilus influenzae* type b meningitis (which may occur in patients who are unvaccinated or immunocompromised). ***Haemophilus*** (from the Greek for blood-loving) requires both **X factor** (hematin) and **V factor** (NAD+) to support growth. Sheep blood agar does not allow *Haemophilus* growth due to insufficient nutrients and the V factor-inactivating enzymes in the medium.

Growth of *Haemophilus* species on sheep blood agar can be achieved by cross-streaking the medium with *Staphylococcus aureus*. *H influenzae* colonies will grow around the streaks of β-hemolytic *S aureus* colonies because the latter actively secrete **V factor (NAD+)** into the medium and facilitate release of additional X factor (hematin) from β-hemolysis-induced erythrocyte lysis. This is known as the "satellite" phenomenon.

(Choices A and F) Pyruvate is the end product of glycolysis and is a starting substrate for the synthesis of glucose, lactate, fatty acids, amino acids, and nucleic acids. Bacteria use pyruvate in the metabolism of sugars for energy in the form of ATP.

(Choice B) Catalase is an enzyme present in staphylococci; the presence or absence of this enzyme is used to differentiate staphylococci from streptococci.

(Choice C) Iron is an essential growth factor for many bacteria, and it is provided in all blood agars from the iron within erythrocytes.

(Choice D) The use of lactose fermentation as a source of energy is best known in *Escherichia coli* with the well studied *lac* operon, an inducible and repressible genetic sequence coding for the enzymes necessary for lactose fermentation in the absence of glucose. It is activated by a sensed glucose deficit and repressed when glucose is available again.

Educational objective:
Haemophilus influenzae is a "blood-loving" organism that requires X (hematin) and V (NAD+) factors for growth. This can be accomplished by growing *H influenzae* in the presence of *Staphylococcus aureus* and demonstrating the "satellite phenomenon," whereby *H influenzae* grow only near the β-hemolytic *S aureus* colonies that produce the needed X and V factors.

Microbiology	Infectious Diseases	Haemophilus influenzae
Subject	System	Topic

Copyright © UWorld. All rights reserved.

An unvaccinated 20-month-old girl is brought to the emergency department with a rash. Three days ago, she developed a fever along with cough, congestion, and red eyes. The rash appeared on her face yesterday and spread to her trunk, arms, and legs today. The patient's temperature is 39.4 C (103 F). She is lethargic and ill appearing. Physical examination shows conjunctival injection and a diffuse, maculopapular, erythematous rash. She is admitted to the hospital for further management. Deficiency of which of the following is associated with a high rate of complications from this patient's condition?

- A. Vitamin A
- B. Vitamin B_6
- C. Vitamin B_{12}
- D. Vitamin D
- E. Vitamin E
- F. Vitamin K

Submit

An unvaccinated 20-month-old girl is brought to the emergency department with a rash. Three days ago, she developed a fever along with cough, congestion, and red eyes. The rash appeared on her face yesterday and spread to her trunk, arms, and legs today. The patient's temperature is 39.4 C (103 F). She is lethargic and ill appearing. Physical examination shows conjunctival injection and a diffuse, maculopapular, erythematous rash. She is admitted to the hospital for further management. Deficiency of which of the following is associated with a high rate of complications from this patient's condition?

- ✓ A. Vitamin A (63%)
- B. Vitamin B_6 (9%)
- C. Vitamin B_{12} (4%)
- D. Vitamin D (1%)
- E. Vitamin E (6%)
- F. Vitamin K (13%)

Omitted
Correct answer
A

63%
Answered correctly

01 sec
Time Spent

06/27/2020
Last Updated

Explanation

Measles virus (rubeola)	
	• Prodrome (eg, cough, coryza, conjunctivitis, fever, Koplik spots)

Measles virus (rubeola)	
Clinical presentation	• Prodrome (eg, cough, coryza, conjunctivitis, fever, Koplik spots) • Maculopapular exanthem ○ Cephalocaudal & centrifugal spread ○ Spares palms/soles
Complications	• Primary measles pneumonia • Secondary bacterial infections (pneumonia & otitis media) • Neurologic ○ Encephalitis (within days) ○ Acute disseminated encephalomyelitis (within weeks) ○ Subacute sclerosing panencephalitis (within years)
Prevention	• Live attenuated measles vaccine

©UWorld

This patient's history of fever, cough, congestion, and conjunctivitis followed by a maculopapular rash is consistent with measles. **Measles** is a highly contagious paramyxovirus that spreads by contact or aerosolized respiratory droplets. This vaccine-preventable infection can be life-threatening. The classic exanthema starts on the face and spreads in a cephalocaudal and centrifugal pattern. Erythematous, blanching, maculopapular lesions often progress to a deep red or brown, nonblanching, coalesced rash.

Vitamin A supplementation is recommended, especially in patients with vitamin A deficiency. Acute measles infection depletes vitamin A stores, resulting in a risk of keratitis and corneal ulceration. Vitamin A helps **prevent** and treat these **ocular complications**. In addition, it **reduces** risk of other comorbidities (eg, pneumonia, encephalitis), **recovery time**, and **length of hospital stay**. No other vitamin is linked to measles.

(Choice B) Vitamin B_6, or pyridoxine, deficiency can result in oral abnormalities (eg, stomatitis, cheilosis) and irritability. Vitamin B_6 is given therapeutically in specific circumstances (eg, to decrease adverse side effects of isoniazid therapy, to decrease homocysteine levels).

(Choice C) Deficiency of vitamin B_{12}, or cobalamin, results in macrocytic anemia; hypersegmented neutrophils on peripheral smear; and

©UWorld

This patient's history of fever, cough, congestion, and conjunctivitis followed by a maculopapular rash is consistent with measles. **Measles** is a highly contagious paramyxovirus that spreads by contact or aerosolized respiratory droplets. This vaccine-preventable infection can be life-threatening. The classic exanthema starts on the face and spreads in a cephalocaudal and centrifugal pattern. Erythematous, blanching, maculopapular lesions often progress to a deep red or brown, nonblanching, coalesced rash.

Vitamin A supplementation is recommended, especially in patients with vitamin A deficiency. Acute measles infection depletes vitamin A stores, resulting in a risk of keratitis and corneal ulceration. Vitamin A helps **prevent** and treat these **ocular complications**. In addition, it **reduces** risk of other comorbidities (eg, pneumonia, encephalitis), **recovery time**, and **length of hospital stay**. No other vitamin is linked to measles.

(Choice B) Vitamin B_6, or pyridoxine, deficiency can result in oral abnormalities (eg, stomatitis, cheilosis) and irritability. Vitamin B_6 is given therapeutically in specific circumstances (eg, to decrease adverse side effects of isoniazid therapy, to decrease homocysteine levels).

(Choice C) Deficiency of vitamin B_{12}, or cobalamin, results in macrocytic anemia; hypersegmented neutrophils on peripheral smear; and neurologic signs, such as paresthesias. Patients with a vegan diet are at risk as this vitamin is only found in animal products.

(Choices D, E, and F) Like vitamin A, vitamins D, E, and K are fat-soluble vitamins and often present in patients with fat malabsorption (eg, cystic fibrosis). Vitamin D deficiency results in bony abnormalities, such as rickets and osteomalacia. Vitamin E deficiency results in hemolytic anemia and neurologic abnormalities (eg, ataxia). Vitamin K deficiency presents with easy bleeding (eg, easy bruising, gum bleeding, hematuria, hematochezia).

Educational objective:
Vitamin A can be beneficial in the treatment of measles infection by reducing comorbidities (eg, ocular complications, diarrhea, pneumonia), recovery time, and length of hospital stay.

References

- Vitamin A for treating measles in children.
- Use of combination measles, mumps, rubella, and varicella vaccine: recommendations of the Advisory Committee on Immunization Practices (ACIP).
- Measles.

©UWorld

Exhibit Display

Zoom In | Zoom Out | Reset | Add To New Card | Existing Card

- Measles.

A 32-year-old man comes to the office due to an acute febrile illness that developed after a deer-hunting trip in Arkansas. The patient recalls getting tick bites in the woods but initially had no symptoms. He began experiencing fever, chills, malaise, headache, and myalgia a week after his return. Physical examination shows a diffuse, maculopapular rash; clear oropharynx; normal lung and heart sounds; and mild, diffuse abdominal tenderness. Laboratory testing reveals leukopenia, thrombocytopenia, and elevated aminotransferase levels. Microscopic evaluation of the blood demonstrates mulberry-shaped, intracytoplasmic inclusions in monocytes. Which of the following is the most likely pathogen responsible for this patient's condition?

A. *Babesia microti*

B. *Borrelia burgdorferi*

C. *Ehrlichia chaffeensis*

D. *Francisella tularensis*

E. *Rickettsia rickettsii*

Submit

A 32-year-old man comes to the office due to an acute febrile illness that developed after a deer-hunting trip in Arkansas. The patient recalls getting tick bites in the woods but initially had no symptoms. He began experiencing fever, chills, malaise, headache, and myalgia a week after his return. Physical examination shows a diffuse, maculopapular rash; clear oropharynx; normal lung and heart sounds; and mild, diffuse abdominal tenderness. Laboratory testing reveals leukopenia, thrombocytopenia, and elevated aminotransferase levels. Microscopic evaluation of the blood demonstrates mulberry-shaped, intracytoplasmic inclusions in monocytes. Which of the following is the most likely pathogen responsible for this patient's condition?

- A. *Babesia microti* (16%)
- B. *Borrelia burgdorferi* (8%)
- ✓ C. *Ehrlichia chaffeensis* (44%)
- D. *Francisella tularensis* (8%)
- E. *Rickettsia rickettsii* (22%)

Omitted
Correct answer
C

44%
Answered correctly

02 secs
Time Spent

03/08/2020
Last Updated

Explanation

Ehrlichia chaffeensis is harbored by **white-tailed deer** in the southwestern, southeastern, and mid-Atlantic United States. It is transmitted to humans by **tick bite** (eg, lone star tick) and subsequently spreads to tissue rich in **mononuclear cells** (eg, bone marrow, lymph nodes, liver, spleen), leading to nonspecific symptoms (eg, fever, chills, myalgia, headache), maculopapular rash, and significant laboratory abnormalities (eg, **lymphopenia**, thrombocytopenia, elevated aminotransferases).

Ehrlichia chaffeensis is harbored by **white-tailed deer** in the southwestern, southeastern, and mid-Atlantic United States. It is transmitted to humans by **tick bite** (eg, lone star tick) and subsequently spreads to tissue rich in **mononuclear cells** (eg, bone marrow, lymph nodes, liver, spleen), leading to nonspecific symptoms (eg, fever, chills, myalgia, headache), maculopapular rash, and significant laboratory abnormalities (eg, **lymphopenia**, thrombocytopenia, elevated aminotransferases).

E chaffeensis replicates in membrane-bound vacuoles within the cytoplasm of monocytes and can be visualized on peripheral blood or buffy coat examination as **mulberry-shaped, intraleukocytic inclusions** (morulae). Treatment with antibiotics (eg, doxycycline) is usually curative.

(Choice A) *Babesia* is a protozoa transmitted by ticks in the northeastern and midwestern United States. It appears as a ring-shaped, intraerythrocytic parasite (similar to *Plasmodium*).

(Choice B) *Borrelia burgdorferi* causes Lyme disease and is transmitted by ticks (eg, *Ixodes scapularis*). Initial infection usually causes nonspecific symptoms (eg, fatigue, headache, myalgia) and a spreading, annular rash called erythema migrans. However, *B burgdorferi* is not typically visualized on microscopy and does not replicate in membrane-bound inclusions.

(Choice D) *Francisella tularensis* is an aerobic, gram-negative bacterium that is transmitted when humans come into contact with infected animals (eg, rabbits). It causes tularemia, which is typically characterized by tender, regional lymphadenopathy and a single, papulo-ulcerative lesion with eschar. This pathogen does not grow within membrane-bound vacuoles within leukocytes.

(Choice E) *Rickettsia rickettsii* is a tick-borne, gram-negative, obligate, intracellular bacterium that attacks vascular endothelial cells and causes Rocky Mountain spotted fever. Patients typically develop nonspecific symptoms (eg, fever, headache, myalgia) followed by a blanching, erythematous, centripetal rash that begins on the ankles and wrists.

Educational objective:
Ehrlichia chaffeensis is harbored in white-tailed deer and transmitted to humans by tick bite. It replicates in vacuoles within monocytes and forms mulberry-shaped, intraleukocytic inclusions (morulae). Manifestations usually include nonspecific symptoms (eg, fever, chills, myalgia), maculopapular rash, and significant laboratory abnormalities, particularly lymphopenia.

Microbiology	Infectious Diseases	Ehrlichiosis & anaplasmosis
Subject	System	Topic

Exhibit Display

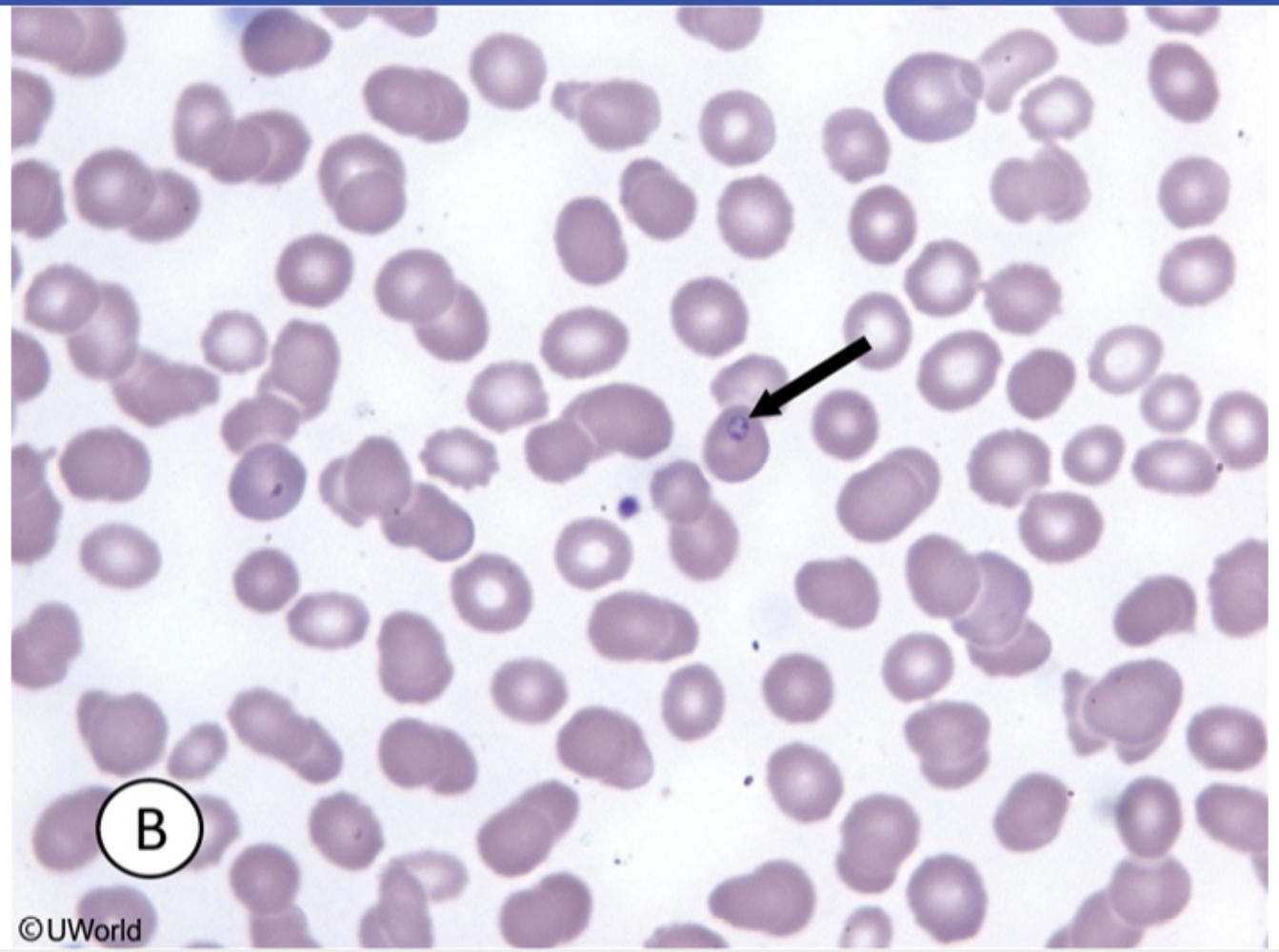

Zoom In | Zoom Out | Reset | Add To New Card | Existing Card

Subject System Topic

A 23-year-old woman diagnosed with a viral infection participates in a longitudinal research study. The patient experiences symptoms of similar spectrum over a specific time, as shown in the image.

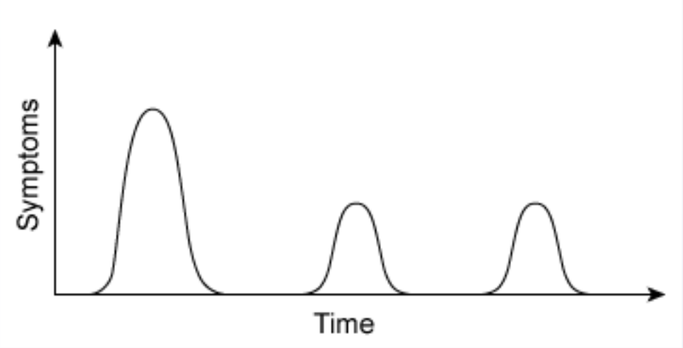

Which of the following mechanisms is most likely responsible for the pattern of illness seen in this patient?

- A. Latent infection within hepatocytes
- B. Latent infection within neuronal cell bodies
- C. Latent infection within transformed B-lymphocytes
- D. Superinfection by a different virus
- E. Viral surface protein changes from gene reassortment

Submit

A 23-year-old woman diagnosed with a viral infection participates in a longitudinal research study. The patient experiences symptoms of similar spectrum over a specific time, as shown in the image.

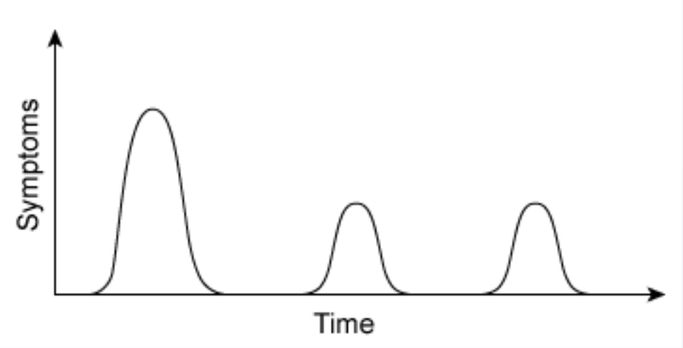

Which of the following mechanisms is most likely responsible for the pattern of illness seen in this patient?

- A. Latent infection within hepatocytes (17%)
- ✓ B. Latent infection within neuronal cell bodies (55%)
- C. Latent infection within transformed B-lymphocytes (8%)
- D. Superinfection by a different virus (1%)
- E. Viral surface protein changes from gene reassortment (17%)

Omitted
Correct answer
B

55%
Answered correctly

03 secs
Time Spent

03/04/2020
Last Updated

Explanation

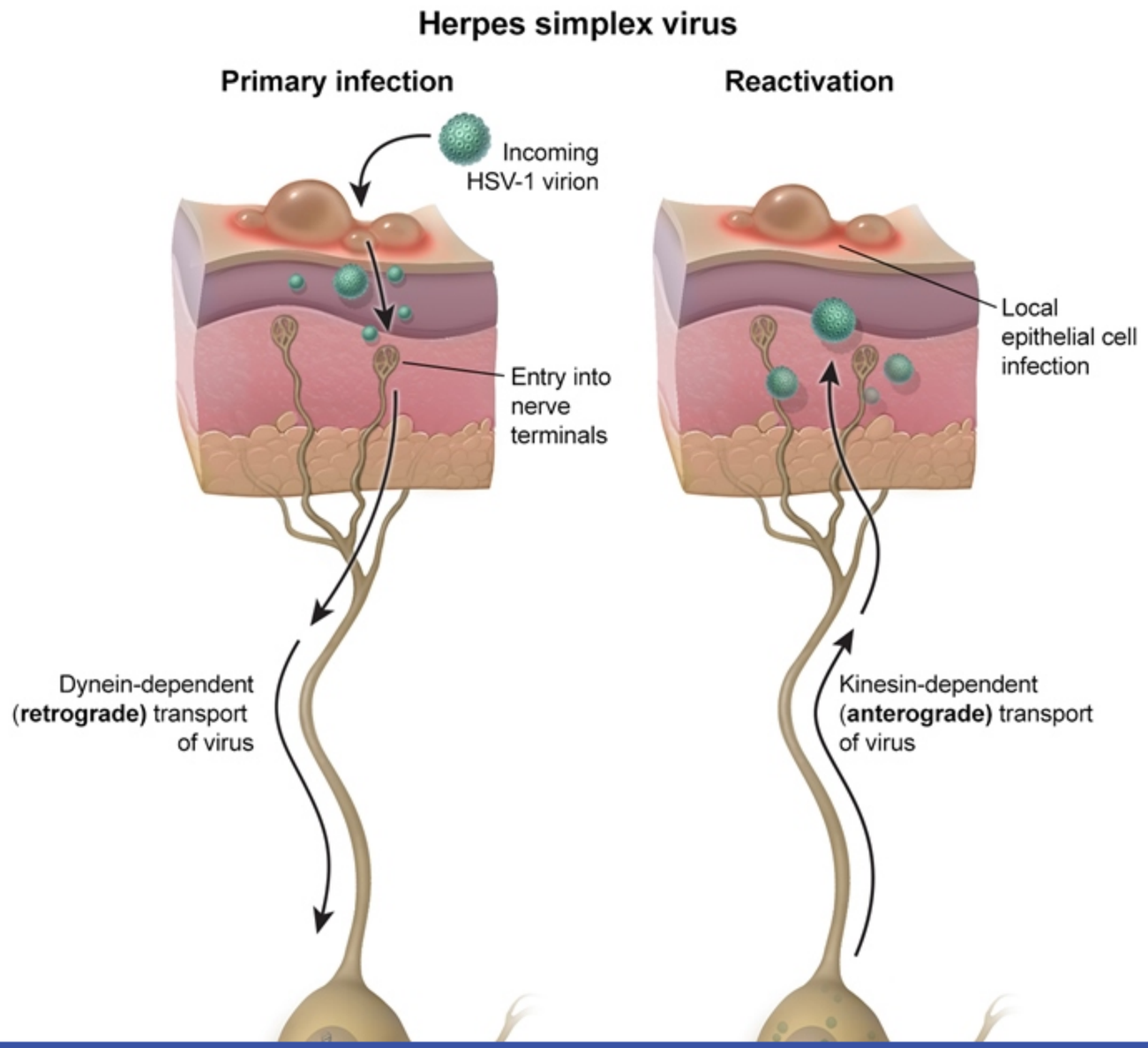
Herpes simplex virus
Primary infection
Reactivation
Incoming HSV-1 virion
Entry into nerve terminals
Local epithelial cell infection
Dynein-dependent (retrograde) transport of virus
Kinesin-dependent (anterograde) transport of virus

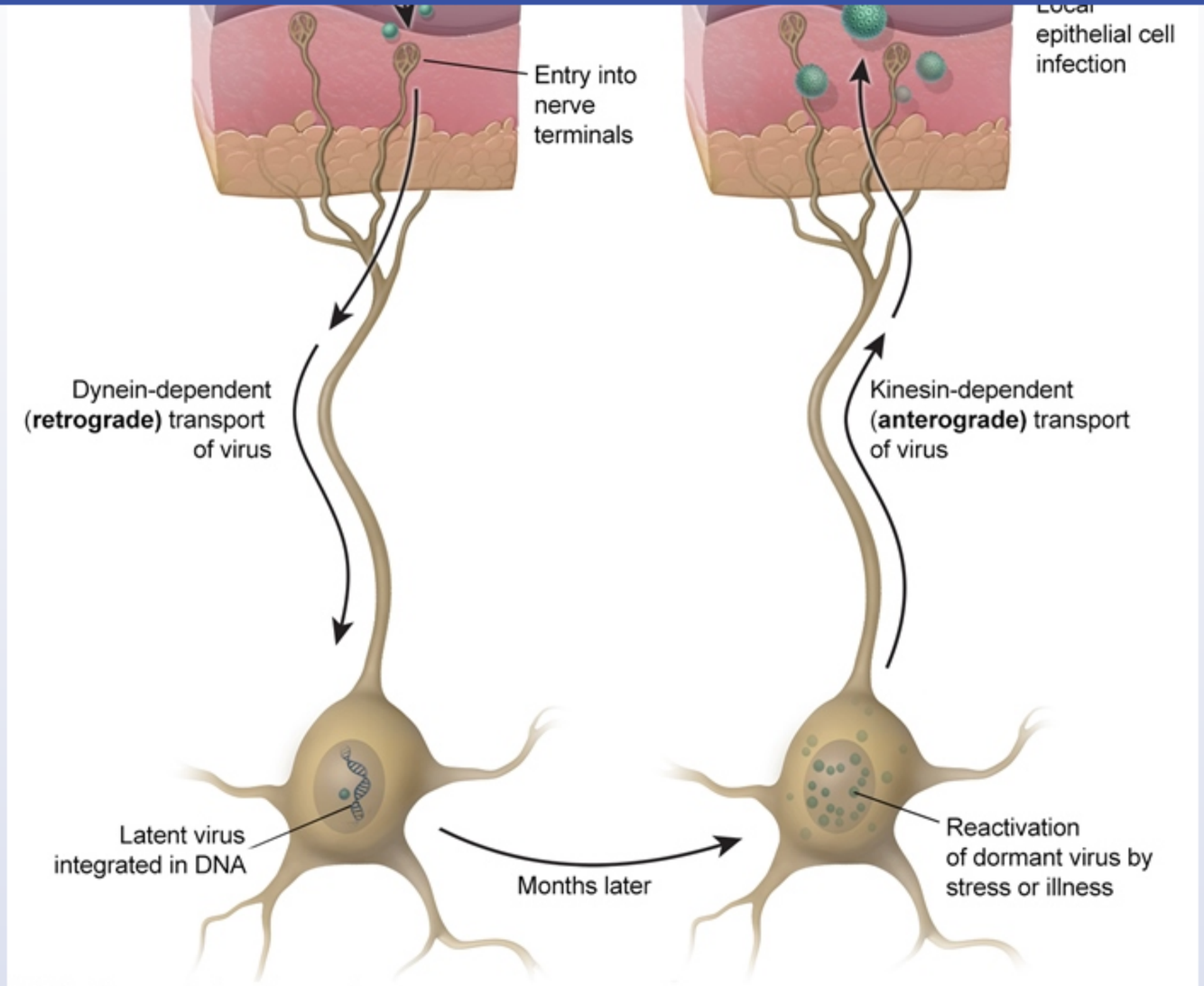

HSV-1 = herpes simplex virus type 1.

©UWorld

Patients with **herpes simplex virus** (HSV) usually have symptoms that flare and remit in a cyclical fashion. Initial HSV infections are marked by

©UWorld

Patients with **herpes simplex virus** (HSV) usually have symptoms that flare and remit in a cyclical fashion. Initial HSV infections are marked by viral replication at the site of exposure (eg, perioral or genital skin), which leads to vesicular mucocutaneous lesions and flulike symptoms. Manifestations last a week or two and then resolve spontaneously when viral replication ceases. However, the virus also spreads to dermal nerve terminals and is transported in a retrograde fashion to the **sensory ganglia**, where it establishes a lifelong **latent infection** within the **neuronal cell bodies**.

During latent infection, no viral replication occurs, so the disease is asymptomatic. However, infected cells continue to produce some HSV genes (eg, latency-associated transcript gene), and stress and other triggers can reactivate viral replication and lead to the re-emergence of symptoms (eg, vesicular lesions on the oral/genital mucous membranes, low-grade fever, malaise). Recurrent symptoms last a week or two and then resolve; they are often less severe than the initial episode.

(Choice A) Infection with hepatitis B or C virus usually results in chronic hepatocyte infection and persistent viral replication. Patients are usually asymptomatic for years or decades and then eventually develop cirrhosis and related complications (eg, jaundice, ascites, encephalopathy). Latent infections do not occur.

(Choice C) Epstein-Barr virus has a tropism for B-lymphocytes. Initial infection is associated with infectious mononucleosis (eg, sore throat, lymphadenopathy, malaise, atypical lymphocytosis); latent infection is usually asymptomatic, but there is a small risk of B-cell or Hodgkin lymphoma due to malignant transformation. Both Epstein-Barr virus and herpes simplex virus are members of the Herpesviridae family.

(Choice D) Hepatitis D virus is a small RNA molecule that requires coinfection with hepatitis B virus to have complete viral assembly. Superinfection by hepatitis D virus in patients with hepatitis B virus can lead to acute hepatic failure.

(Choice E) Influenza has a segmented genome, which leads to high rates of gene reassortment when 2 strains infect the same cell. Gene reassortment of surface glycoproteins (eg, hemagglutinin, neuraminidase) causes new strains to emerge and can result in new infections in those with a history of previous influenza infection; because surface proteins have changed, previous immunity is insufficient.

Educational objective:
Patients infected with herpes simplex virus develop a lifelong latent infection of the sensory ganglion. Periodic viral replication can lead to symptoms that flare and resolve over time.

HSV-1 = herpes simplex virus type 1

Exhibit Display

Zoom In | Zoom Out | Reset | Add To New Card | Existing Card

symptoms that flare and resolve over time.

HSV-1 = herpes simplex virus type 1.

©UWorld

Patients with **herpes simp** ... by viral replication at the site ... Manifestations last a week ... erve terminals and is transporte ... al **cell bodies**.

During latent infection, no ... nes (eg, latency-associated tra ... ns (eg, vesicular lesions on t ... resolve; they are often les ...

(Choice A) Infection with ... ally asymptomatic for years or ... Latent infections do not oc ...

(Choice C) Epstein-Barr ... lymphadenopathy, malaise ... lymphoma due to maligna ...

(Choice D) Hepatitis D vi ... Superinfection by hepatitis ...

(Choice E) Influenza has ... reassortment of surface gl ... ose with a history of previous i ...

Educational objective:
Patients infected with herpes simplex virus develop a lifelong latent infection of the sensory ganglion. Periodic viral replication can lead to symptoms that flare and resolve over time.

Exhibit Display

Viruses that cause latent infection	
Site of latency	**Virus**
Sensory neurons	Herpes simplex & varicella zoster viruses
B lymphocytes	Epstein-Barr virus
Myeloid cells	Cytomegalovirus, human herpesvirus 6 & 7
CD4 T lymphocytes	Human immunodeficiency virus
Stratified squamous epithelial cells	Human papilloma virus
Renal tubular epithelial cells	BK virus
Neuroglial cells	JC virus

Add To New Card | Existing Card

terminals and is transported in a retrograde fashion to the **sensory ganglia**, where it establishes a lifelong **latent infection** within the **neuronal cell bodies**.

During latent infection, no viral replication occurs, so the disease is asymptomatic. However, infected cells continue to produce some HSV genes (eg, latency-associated transcript gene), and stress and other triggers can reactivate viral replication and lead to the re-emergence of symptoms (eg, vesicular lesions on the oral/genital mucous membranes, low-grade fever, malaise). Recurrent symptoms last a week or two and then resolve; they are often less severe than the initial episode.

(Choice A) Infection with hepatitis B or C virus usually results in chronic hepatocyte infection and persistent viral replication. Patients are usually asymptomatic for years or decades and then eventually develop cirrhosis and related complications (eg, jaundice, ascites, encephalopathy). Latent infections do not occur.

(Choice C) Epstein-Barr virus has a tropism for B-lymphocytes. Initial infection is associated with infectious mononucleosis (eg, sore throat, lymphadenopathy, malaise, atypical lymphocytosis); latent infection is usually asymptomatic, but there is a small risk of B-cell or Hodgkin lymphoma due to malignant transformation. Both Epstein-Barr virus and herpes simplex virus are members of the Herpesviridae family.

(Choice D) Hepatitis D virus is a small RNA molecule that requires coinfection with hepatitis B virus to have complete viral assembly. Superinfection by hepatitis D virus in patients with hepatitis B virus can lead to acute hepatic failure.

(Choice E) Influenza has a segmented genome, which leads to high rates of gene reassortment when 2 strains infect the same cell. Gene reassortment of surface glycoproteins (eg, hemagglutinin, neuraminidase) causes new strains to emerge and can result in new infections in those with a history of previous influenza infection; because surface proteins have changed, previous immunity is insufficient.

Educational objective:
Patients infected with herpes simplex virus develop a lifelong latent infection of the sensory ganglion. Periodic viral replication can lead to symptoms that flare and resolve over time.

Microbiology	Infectious Diseases	HSV infection
Subject	System	Topic

Copyright © UWorld. All rights reserved.

A 5-year-old child is brought to the emergency department due to difficulty breathing and a low-grade fever. The patient's family recently moved to the United States from rural Nepal. Temperature is 38.1 C (100.6 F). Physical examination shows a grayish pharyngeal exudate, enlarged cervical lymph nodes, and partial soft palate paralysis. A sample of the pharyngeal exudate is obtained by oropharyngeal swab. Bacteria isolated from the exudate demonstrate exotoxin production in the laboratory. Which of the following best describes the mechanism of action of the exotoxin?

A. Autoimmune activation by antigenic mimicry

B. Degradation of lecithin

C. Inactivation of the 60S ribosomal subunit

D. Increased sensitivity to histamine

E. Intracellular protein ribosylation

Submit

A 5-year-old child is brought to the emergency department due to difficulty breathing and a low-grade fever. The patient's family recently moved to the United States from rural Nepal. Temperature is 38.1 C (100.6 F). Physical examination shows a grayish pharyngeal exudate, enlarged cervical lymph nodes, and partial soft palate paralysis. A sample of the pharyngeal exudate is obtained by oropharyngeal swab. Bacteria isolated from the exudate demonstrate exotoxin production in the laboratory. Which of the following best describes the mechanism of action of the exotoxin?

- A. Autoimmune activation by antigenic mimicry (5%)
- B. Degradation of lecithin (4%)
- C. Inactivation of the 60S ribosomal subunit (17%)
- D. Increased sensitivity to histamine (0%)
- ✓ E. Intracellular protein ribosylation (72%)

Omitted
Correct answer
E

72%
Answered correctly

03 secs
Time Spent

04/27/2020
Last Updated

Explanation

Diphtheria	
Epidemiology	• Endemic in developing countries due to inadequate vaccination but rare in developed countries

Diphtheria	
Epidemiology	• Endemic in developing countries due to inadequate vaccination but rare in developed countries
Microbiology/ pathogenesis	• ***Corynebacterium diphtheriae*** colonize respiratory tract & secrete diphtheria toxin, the primary virulence factor • **Diphtheria toxin** is an AB exotoxin that inhibits protein synthesis by ADP-ribosylation of EF-2 • Toxin acts locally, causing respiratory cell necrosis with formation of fibrinous, coagulative exudates
Clinical symptoms	• Sore throat • Fever • Cervical adenopathy • Pharyngeal exudates/**coalescing pseudomembrane**
Complications	• Submucosal edema & pseudomembrane aspiration can obstruct respiratory tract, causing **suffocation** • Systemically absorbed diphtheria toxin has predilection for brain & heart tissue ○ **Myocarditis/heart failure** ○ **Neurologic toxicity**

EF-2 = elongation factor-2.

©UWorld

This child has **diphtheria**, a disease caused by *Corynebacterium diphtheriae* and now rarely seen in most countries as a result of vaccination.

This child has **diphtheria**, a disease caused by *Corynebacterium diphtheriae* and now rarely seen in most countries as a result of vaccination. The A (active) subunit of the diphtheria AB **exotoxin** transfers a ribose residue from NAD to a histidine on **elongation factor-2** (EF-2). The EF-2 protein is essential for peptide chain translocation on the ribosome in the process of translation. **Ribosylation** inactivates EF-2, thereby inhibiting protein synthesis and causing cell death.

(Choice A) Group A *Streptococcus* (GAS) pharyngitis can lead to rheumatic fever via antigenic mimicry. GAS and cardiac myocytes have similar antigenic protein sequences. Therefore, when the immune system mounts a response against GAS, it may also cause myocarditis and valve destruction over time. GAS pharyngitis is not typically due to exotoxins and does not classically cause local neuropathies (eg, soft palate paralysis).

(Choice B) Lecithinase (also known as phospholipase C, or *Clostridium perfringens* alpha-toxin) is the exotoxin released by *C perfringens*. This enzyme degrades membrane phospholipids (including lecithin), leading to cell membrane destruction and cell death. *C perfringens* causes gas gangrene.

(Choice C) The shiga toxin of *Shigella* and the shigalike toxin of enterohemorrhagic *Escherichia coli* (EHEC) cause inactivation of the 60S ribosomal subunit. By contrast, diphtheria toxin inactivates EF-2, not the ribosome itself. *Shigella* and EHEC cause diarrheal illnesses.

(Choice D) Pertussis toxin is an AB exotoxin released by *Bordetella pertussis* that catalyzes ribosylation of G protein α_i subunits. This results in increased cAMP production, which leads to increased insulin production, lymphocyte and neutrophil dysfunction, and increased sensitivity to histamine. Classic pertussis has a catarrhal stage (mild upper respiratory symptoms), a paroxysmal stage (whooping cough), and a convalescent stage.

Educational objective:
Diphtheria toxin is an AB exotoxin that ribosylates and inactivates elongation factor-2. This action inhibits protein synthesis and ultimately leads to cell death.

Microbiology	Infectious Diseases	Diphtheria
Subject	System	Topic

Copyright © UWorld. All rights reserved.